

Primary Tuberculosis of the Breast Manifested as Abscess: a Rare Case Report

Samita Gupta¹, Vikram J. Singh², Gaurav Bhatia², Kshitiz Dhuria³

¹ Department of Radiology, Maharishi Markendeshwar Institute of Medical Sciences and Research, Mullana, Distt-Ambala, Haryana, India.

² Department of Surgery, Maharishi Markendeshwar Institute of Medical Sciences and Research, Mullana, Distt-Ambala, Haryana, India.

³ Department of Radiology, Maharishi Markendeshwar Institute of Medical Sciences and Research, Mullana, Distt-Ambala, Haryana, India.

Correspondence mail:

Dr. Samita Gupta, MD. Assistant Prof, Department of Radiology, Maharishi Markendeshwar Institute of Medical Sciences and Research, Mullana, Distt-Ambala, Haryana, India. email: singalsurgery@yahoo.com.

ABSTRAK

Tuberkulosis primer di payudara merupakan suatu entitas penyakit yang jarang terjadi. Kami melaporkan sebuah kasus tuberkulosis primer di payudara yang tampak sebagai abses payudara. Secara histopatologi, kasus ini didiagnosis sebagai tuberkulosis payudara. Aspirasi sitologi tidak dilakukan karena adanya abses di payudara. Pasien diberikan obat anti-tuberkulosis. Pada evaluasi lanjut, kondisi pasien ternyata membaik dalam 3 bulan.

Kata kunci: payudara, abses, tuberkulosis, pengobatan konservatif.

ABSTRACT

Primary breast tuberculosis is a rare entity. We are reporting a case of primary breast tuberculosis, which presented as breast abscess. On histopathology, it was diagnosed as breast tuberculosis. Aspiration cytology was not done due breast abscess. Patient was put on anti-tubercular drugs. In follow up, after 3 months patient condition was improved.

Key words: breast, abscess, tuberculosis, conservative treatment.

INTRODUCTION

Breast tuberculosis (TB) is a rare form of extra pulmonary TB first described by Sir Astley Cooper in 1829.¹ Although over one billion people suffer from TB worldwide, mammary tuberculosis is an extremely rare condition. The incidence of isolated TB of the breast ranges from 0.10% to 0.52%.² is scarcely reported even in countries with a high incidence of tuberculosis infection. This is explained by a

noticeable resistance of the mammary tissue to the mycobacterium tuberculosis.³ Its primary form is even more infrequent.

CASE ILLUSTRATION

A 42 year old female reported with pain in the right breast since two months with on and off fever. She started feeling heaviness in her right breast since 20 days before. There were no other complaints. Patient was taking treatment

from private hospital but there was no relief. On examination of the right breast, temperature was raised and tender lump was felt in the upper outer quadrant. Lump was firm in consistency.

On needle aspiration, thick pus came out. Total leukocyte counts and erythrocyte sedimentation rate was raised. Rests of tests were within normal limits including chest X-ray. Mantoux test was positive. Ultrasonography of the breast revealed a large homogeneous capacity in right breast with area of asymmetrical density. (**Figure 1**)

Thick pus of about 100 ml was drained out. Pus was sent for acid fast bacilli stain and culture test which came negative. On histopathology, to our surprisingly, diagnosis made as breast tuberculosis (**Figure 2**). Patient was put on anti tubercular drugs (rifampicin 600 mg, isoniazid 300 mg, pyrazinamide 1500 mg and ethambutol 1000 mg per day) was initiated for 2 months and continued with the addition of rifampicin and isoniazid therapy for an additional four months. In follow up of 3 months, patient recovered very well and advised to continue treatment.

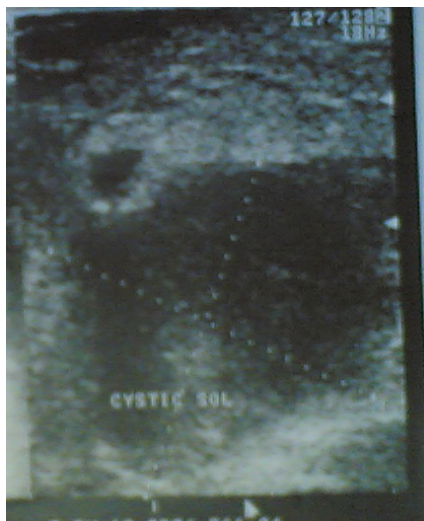

Figure 1. Ultrasonography of breast showed hypoechoic lesion with multiple internal echoes

DISCUSSION

Isolated tuberculosis of the breast is uncommon, even in developing countries where pulmonary and other forms of extrapulmonary manifestations of TB are endemic. The incidence of isolated TB of the breast remains low,

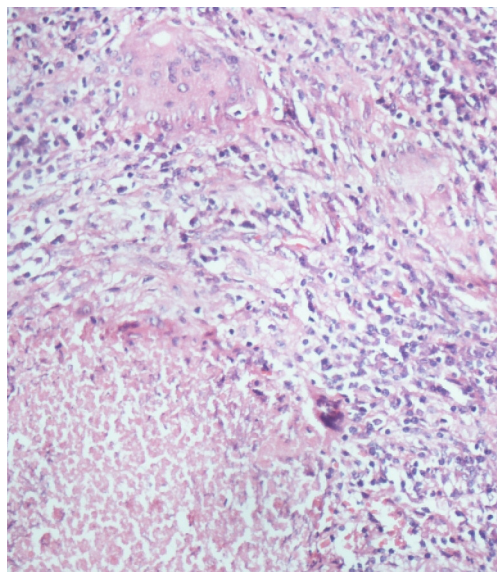


Figure 2. Photomicrograph showing caseating granuloma in the breast (H & E ,X – 200)

ranging from 0.10% to 0.52%. In the high tubercular endemic countries like India, the incidence represents 3 to 4.5% of the mammary pathologies.⁴ In the Western countries, with a lower tubercular incidence, it represents less than 0.1% of the mammary lesions examined via histology.^{3,5} Tuberculosis of the breast is usually affects women aged between 20 and 50 years. Breast involvement can be either primary without any extra-mammary focus, or secondary to pulmonary tuberculosis. The primary form of the disease is rare.⁶

Breast tissue, along with skeletal muscle and spleen, appears to be relatively resistant to tuberculous infection.⁷ The commonest location of the lump is the central or upper outer quadrant of the breast.⁸ The mass may be fluctuant and is usually covered with indurated tissue. It is usually fixed to the skin and fistulization is not uncommon. Nipple and skin retraction can also occur but breast discharge and pain are not common.⁹

It may be classified into three types, namely: nodular, disseminated and sclerosing varieties. McKeown and Wilkinson classified tuberculosis of the breast into five different types: the three stated above and acute miliary tuberculosis mastitis and tuberculosis mastitis obliterans.¹⁰ The nodular form is the most common variety and is characterized by a well defined, painless,

slow growing caseous lesion in the breast. Involvement of overlying tissue is usually late and it is at this point that the mass becomes painful. As in our case patient presented with breast abscess and on histology diagnosis came as tuberculosis which is very rare. Ultrasound is useful for characterising the ill-defined densities shown on mammography by excluding solid masses, but the findings of a hypoechoic lesion with heterogeneous internal echoes and irregular borders are not specific.² Microbiological and histological examinations remain the gold standard for the diagnosis of this uncommon disease. Early diagnosis is difficult, as the characteristic sinuses occur late in the course of the disease. In young women tuberculosis of the breast is often diagnosed as pyogenic abscess and in the elderly as carcinoma. Treatment of tuberculosis mastitis is best achieved by conservative surgery and anti-tuberculosis chemotherapy but in our case breast abscess was diagnosed which drained and on histology it diagnosed as tuberculosis.

CONCLUSION

The diagnosis must be considered in young patients presenting with a palpable lump, especially if they are lactating. A histological examination is required for confirmation. We concluded that if presented with abscess then also we should go for aspiration cytology keeping in mind chances of tuberculosis.

REFERENCES

1. Cooper. Illustrations of the diseases of the breast. Part I. London: Longman, Rees, Orme, Brown, and Green; 1829. p. 73.
2. Hale JA, Peters GN, Cheek JH. Tuberculosis of the breast: rare but still extant. *Am J Surg.* 1985;150:620-4.
3. Tewari M, Shukla HS. Breast tuberculosis: diagnosis, clinical features, and management. *Indian J Med Res.* 2005;122:103-10.
4. Gupta V, Mohan H, Jain P, Singh S, Singla N. Tuberculous mastitis: A report of two cases in elderly females. *Jpn J Infect Dis.* 2006;59:279-80.
5. Kalac N, Ozkan B, Bayiz H, Dursun AB, et al. Breast tuberculosis. *Breast.* 2002;11:346-9.
6. Zandrino F, Monetti F, Gandolfo N. Primary tuberculosis of the breast. A case report. *Acta Radiol.* 2000;41:61-3.
7. Alagaratnam TT, Ong GB. Tuberculosis of the breast. *Br J Surg.* 1980;67:125-6.
8. Morsad F, Ghazli M, Boumzgon K, et al. Mammary tuberculosis: a series of 14 cases. *J Gynaecol obstet Biol Reprod.* 2001;30:331-7.
9. Green RM, Ormerud LP. Mammary tuberculosis: rare but still present in the united kingdom. *Int J Tuberc Lung Dis.* 2000;4:788-90.
10. McKeown KC, Wilkinson KW. Tuberculosis disease of the breast. *Br J Surg.* 1952;39:420-9.