

Supraclavicular Lymphnodes: Unusual Manifestation of Metastase Adenocarcinoma Colon

Harijono Achmad, Rofika Hanifa

Department of Internal Medicine, Faculty of Medicine Brawijaya University - Saiful Anwar Hospital, Malang, Indonesia.

Correspondence mail:

Division of Gastroenterohepatology, Department of Internal Medicine, Faculty of Medicine, Brawijaya University - Saiful Anwar Hospital. Jl. Veteran Malang, Lowokwaru, Malang, Jawa Timur 65145, Indonesia. email: gastro_mlg@yahoo.com.

ABSTRAK

Kasus ini mengenai seorang pasien dengan getah bening supraklavikula simpul metastasis dari adenokarsinoma terlihat melintang di usus besar. Terdapat keluhan batuk dan didiagnosis demam tifoid, bronkitis serta metastasis hati. Perut sebah, penurunan berat badan, sembelit, tinja seperti pensil dengan adanya lendir dan darah, sakit tulang, dan urin berwarna seperti teh. Pemeriksaan kolonoskopi pertama kali terungkap adanya ileitis limfositik dan temuan mikroskopis juga menunjukkan ileitis limfositik. USG dan CT scan mengungkapkan metastasis hati yang tidak diketahui asalnya. Berdasarkan tanda dan gejala klinis, kami menduga bahwa karsinoma kolorektal adalah temuan utama. Kemudian, kolonoskopi kedua dilakukan dan ditemukan adanya polip kecil, yang disertai dengan biopsi dan hasilnya mendukung usus adenokarsinoma berdiferensiasi baik. Hasil serupa juga diungkapkan oleh evaluasi histopatologi. Kami melaporkan kasus yang tidak biasa dari hati dan supraklavikula metastasis kelenjar getah bening yang timbul dari adenokarsinoma polip kecil dari usus besar.

Kata kunci: *metastasis hati, karsinoma kolorektal, kelenjar limfe.*

ABSTRACT

We report a patient with supraclavicular lymph node metastasis from an undetectable adenocarcinoma of the transverse colon, who presented with cough and was diagnosed with typhoid fever; bronchitis as well as liver metastasis. There were an abdominal fullness, weight loss, constipation, pencil-like stool with mucous and blood, low-grade fever, bone ache, and tea-color urine. The first colonoscopy revealed lymphocytic ileitis and microscopic findings also showed lymphocytic ileitis. Abdominal USG and CT revealed liver metastasis of unknown origin. Based on the clinical sign and symptoms, we suspected that colorectal carcinoma was the primary site. Then, the second colonoscopy was performed and it revealed a small polyp, which was followed with a biopsy and the result supported a well-differentiated colon adenocarcinoma. Similar result was also revealed by the histopathological evaluation. This is an unusual case of liver and supraclavicular lymph node metastasis arising from a small polyp adenocarcinoma of the transverse colon.

Key words: *liver metastase, colorectal carcinoma, lymph node.*

INTRODUCTION

Colorectal cancer (CRC) remains a major public health problem in western countries. Each year, worldwide, there are approximately 400,000 people die from colorectal cancer and 700,000 new cases are diagnosed. Colorectal carcinoma is the second leading cause of death from cancer in the US. It is also the third most common malignancy in both men (after lung and prostate cancers) and women (after lung and breast cancers).¹ Approximately 60% of patients will develop metastatic disease, which is localized to the liver alone in half of them.^{1,2}

By the time they are diagnosed, about 25% of colon cancers will have extended through the bowel wall; whereas cancers of the rectum will have spread through the bowel wall in 50%-70% of patients and metastasized to lymph nodes in 50%-60%.¹

The most common site of extra lymphatic involvement is the liver and the lung is the most frequently affected extra-abdominal organ. Metastatic liver tumors are largely silent until the disease is well advanced.² Patients with metastatic colorectal tumors frequently die of hepatic failure due to liver metastasis. The overall incidence of colorectal carcinoma (CRC) is nearly identical in men and women. The risk of developing colorectal tumors begins to increase at 40 and rises with age. The incidence of CRC is higher in industrialized regions of the world.¹

Specific causes of CRC are unknown, but nutritional, genetic and familial factors, as well as pre-existing diseases, such as inflammatory bowel disease or certain cancers, have been found to be associated with this cancer. Risk factors for the development of CRC include high-fat diet, daily alcohol use, smoking, decreased physical activity and obesity.¹

CASE ILLUSTRATION

A 53-year-old male patient presented with cough since 1 year ago without sputum production. He also had progressive epigastric pain for 5 months, accompanied with low-grade fever. He had been admitted to a hospital in Surabaya a month before and the doctor said that he had chronic bronchitis and typhoid fever. He had difficulty in passing stool since 5 months

before admission. He had pencil-like stool with mucous and blood and passed tea-color urine since 2 weeks before admission. His lost 11-kilograms in the last 5 months.

He also said that he had bone ache since 37 years ago (1972), and he used to consume herbal medicine called Puyer Bintang Toed Joe since 1975 (34 years), once a month, and he started to consume Jamu Tawon Api since 6 years ago as his pain developed progressively. He usually works using a lot of physical strength. He has never suffered from frequent unperceived trauma or had fallen in his daily life. He used to drink alcohol from 1985 to 1990 and drank half a bottle per week. He used to smoke 10 cigarettes per day when he was young.

Then, since there were no improvements of his condition, he met an internist in Malang, and he consulted his illness to the Department of Gastroenterohepatology. The cough was relieved after he had received steroid injection.

On physical examination, the patient was in mildly ill condition. He was fully conscious with blood pressure of 110/80 mmHg, pulse rate at 80 beats per minute, respiratory rate was 18x/m. His axillary temperature was 36°C, with body weight of 70 kg, body height of 170 cm, and body mass index of 23.4. Auscultation of the lungs and heart revealed normal result. The abdomen was tender, but we found hepatomegaly with smooth surface, sharp margin, and Traube's space dullness. The carotid and radial pulse were normal. CNS examination revealed that the higher mental functions including the functions of cranial nerves and speech were normal. Motor system and sensory examinations were also normal. Examinations and review of other systems showed normal results. Investigation of hemogram revealed leukocytosis (leukocytes of 28,700/mm³ with normal hemoglobin level (11 g/dl) and blood chemistry test revealed normal results. The albumin and random blood glucose levels were normal with Salmonella typhi H titer of 1/640, Paratyphi A-B titer of 1/640, and paratyphi titer of CH 1/160. However, the cytology of red blood smear revealed normocytic normochromic red cells. Acid fast bacilli and gram staining of sputum test revealed negative results; however, the result of

TB PCR was positive. The ESR was 100-119 mm/hour, but bilirubin, alkaline phosphatase, alfa-fetoprotein and others blood and urine parameters were normal.

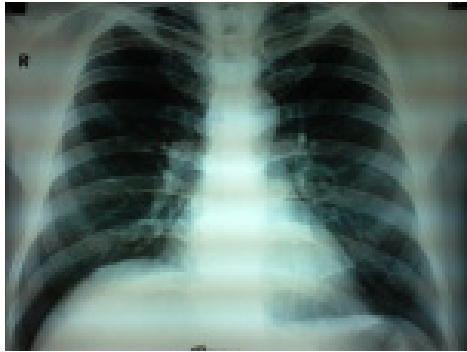


Figure 1. Chest X-Ray revealed increased bronchovascular pattern (increasing KV)

Plain radiographs were taken in March, 31th 2009. The chest radiographs showed increased bronchovascular pattern (**Figure 1**). We suspected a possibility of hilar lymphadenopathy in this chest X-ray.

An electrocardiogram revealed a normal sinus rhythm at rate of 90/min. Abdominal USG and CT scan (**Figure 2** and **3**) revealed hepatomegaly, multiple nodules, hyperechoic

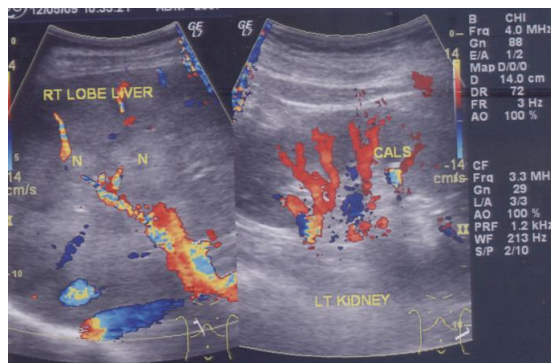


Figure 2. Abdominal USG revealed multiple nodules in right and left lobe of the liver. No calcification/ cystic lesion/ papili was found.

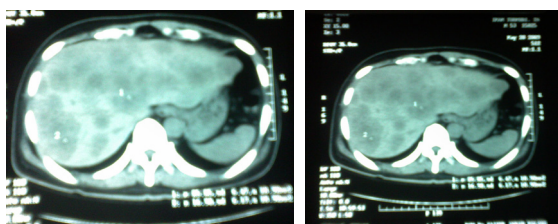


Figure 3. Abdominal CT scan revealed metastatic process in the liver with unknown primary origin

with rough and heterogenic echo parenchyma and bull's eye sign, which suggested a secondary hepatoma of unknown primary origin.

Considering the abovementioned clinical features and investigation, patient was diagnosed with liver cancer of unknown primary origin.

Due to his complaint of passing pencil-like stool and weight loss, he had a colonoscopy in Surabaya on April, 4th, 2009. The doctor suspected colorectal carcinoma as the primary site, but colonoscopy results revealed internal hemorrhoids and normal colon (**Figure 4**).

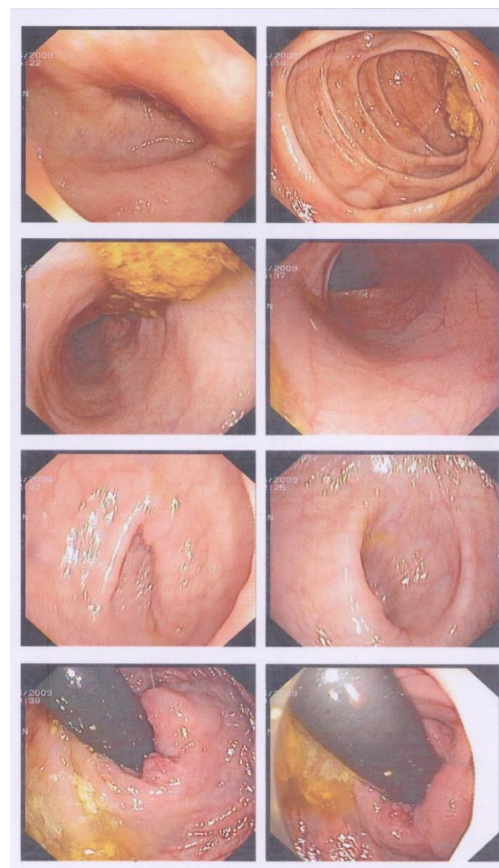


Figure 4. The 1st colonoscopy revealed internal hemorrhoid and normal colon

Biopsy results revealed lymphocytic ileitis and subsequently we found lymph node enlargement in supraclavicular region. No enlargement was found in the inguinal region. Malignant lymphoma was considered as the primary origin of liver metastasis since there was supraclavicular lymph node enlargement and lymphoid cell findings in the 1st ileum

biopsy. However, colorectal carcinoma was also considered as the primary origin because there were changes in bowel habits, hematochezia and weight loss.

We continued our investigation by performing re-colonoscopy, tumor marker examination, and biopsy of liver and supraclavicular lymph nodes to find the primary cancer. Investigations of tumor marker revealed normal results. The CEA level was 50 ng/ml (normal range <5 ng/mL), which supported our diagnosis, i.e. colorectal carcinoma as the primary cancer. Other tumor markers revealed normal results including CA 19-9 of 20.15 (<37 U/mL), AFP of 1.63 ng/ml (<7.2 ng/mL), CA 125 of 15.78 U/mL<35 U/mL).

We continued our investigation further by performing another colonoscopy and biopsy of liver and supraclavicular lymph nodes. The last colonoscopy revealed small polyp of 20 centimeters in size extending from external anal

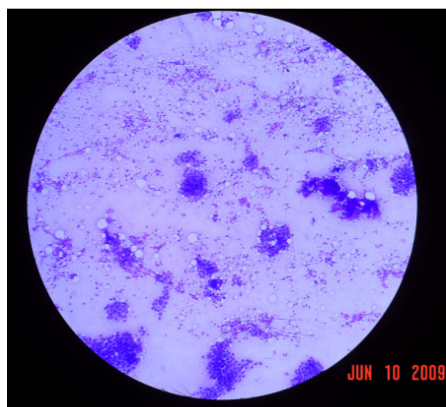


Figure 5. The result of supraclavicular lymph node biopsy showed undifferentiated carcinoma metastasis

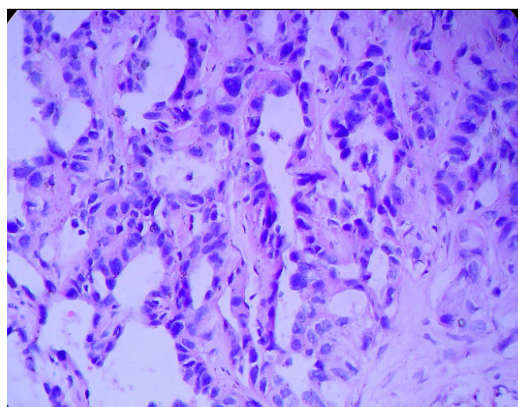


Figure 6. Liver biopsy revealed metastasis of poorly differentiated adenocarcinoma

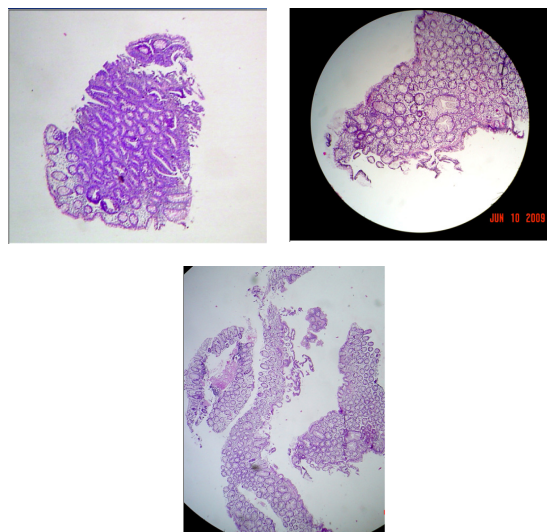


Figure 7. Rectum biopsy revealed normal result; however, the biopsy of transversal colon showed a well-differentiated adenocarcinoma

orifice.

The final diagnosis of our case was liver and lymph node metastasis originated from a small polyp in transversal colon. It was actually an infiltrative spread of an adenocarcinoma. Based on signs and symptoms of passing mucous pencil-like stool, hematochezia, weight loss, hepatosplenomegaly, supraclavicular lymph node enlargement, multiple nodules of the liver, bull's eye sign of ultrasonography findings and the results of colon biopsy, the diagnosis of colorectal carcinoma with metastasis to liver and supraclavicular lymph nodes was established.

Fluid and electrolytes were given intravenously. We treated the patient using 125 mg/24 hours intravenous Medixon®, 40 mg/day Omeprazole, 100 cc of 20% albumin transfusion, 20 mg of Atorsan® in the morning and Aminofusin® /0.9% normal saline with the rate of 21 drops/minute. On the 7th day of admission, we performed chemotherapy, using Ca leucovorin and 5-Fluorouracyl (De-gramont regimen). The patient showed a good response to chemotherapy.

The nonproductive cough showed a good response to steroid. It is possible that there were granulomas such as Koch pulmonum, Sarcoidosis or Aspergillosis in this patient as a result of impaired immune mechanisms. Corticosteroid may acutely suppress the manifestations, improves the cough and reveals

better result of chest radiograph. However, further investigations are necessary to confirm the diagnosis of lung process.

DISCUSSION

Colorectal carcinoma is the second leading cause of death from gastrointestinal tract (GIT) cancer in US. It is the 3rd common malignancy in both men and women, after lung, breast or prostate carcinoma.¹

Most of colorectal carcinoma developed metastatic disease (60%). The metastatic process to liver alone is account for 50%, which more frequently found in sessile polyps. According to Petrek, the common location of colorectal carcinoma are rectum (22%), recto sigmoid (8%), sigmoid (20%), descendingt colon (12%), flexure lienalis (8%), transversum (6%), flexure hepatica (4%), ascending colon (6%), caecum (12%), and appendix (2%) of all colorectal carcinoma.

Signs and symptoms of colorectal carcinoma depend on the location and the size of the tumor itself. Abdominal pain and polypoid fungating are signs and symptoms, which are commonly found in carcinoma of caecum and ascending colon; while recto sigmoid carcinoma usually presents the sign of obstruction/napkin rings or bleeding. In addition, colorectal carcinoma also may present with abdominal pain (60.5%), anemia (21.3%), weight loss (28.8%), changes in bowel habits (48%), diarrhea (12.7%), hematoschezia (48.5%), hemorrhoid (10.4%), abdominal mass (24.2%), rectal mass (7.9%), obstruction (17.0%), and asymptomatic (2.5%). Sometimes, the tumor invades into the intestine wall and perforates. When this occurs, it will cause peritonitis and septicemia. If the tumor gets ulcerated and involves blood vessel, it may cause bleeding.

According to Odone, the first appearance of the tumor may need 3-12 months to be noticed; while according to Petrek, colorectal carcinoma is uncommon in young age patients.¹ The screening tests include stool examination, barium enema and detection of circulating antigen for all people over 40 years of age. CEA, a tumor marker found by Gold and Freedman, is detected in 72-92% of patients with colorectal carcinoma. CEA will be increased within 6-10 months before

signs of metastasis develop or when the signs relapse. It is also will be markedly increased in poorly differentiated colorectal carcinoma as well as in colorectal carcinoma that has been spread to blood vessel and lymphatic nodes.

Supraclavicular lymph node is an unusual metastatic site for colorectal carcinoma. It is usually a metastatic site for gastric carcinoma. Liver metastasis is a common complication of cancer occurring in up to 70% of patients with advanced breast or prostate cancer and approximately 15% to 30% of patients with carcinoma of the lung, colon, stomach, bladder, uterus, rectum, thyroid, or kidney.²

The patient was first diagnosed with carcinoma of unknown origin. Later, he was diagnosed with carcinoma of unknown primary. Carcinoma of unknown primary (CUP) is a biopsy-proven diagnosis of malignancy (mainly epithelial) for which the anatomic site of origin remains unidentified after an intensive search. CUP is one of the 10 most frequently diagnosed cancers worldwide. It contributes to approximately 3–5% of all cancer cases.⁴ Most investigators rarely consider lymphomas, metastatic melanomas, and metastatic sarcomas that present without a known primary tumor to be CUP since those cancers have specific stage- and histological-based treatments.

A standard workup for CUP includes history taking, physical examination, and laboratory studies such as liver and renal function tests, hemogram, chest X-ray, CT scan of the abdomen and pelvis, mammography in women, and prostate-specific antigen (PSA) test in men.

With increasing availability of additional sophisticated imaging techniques and the emergence of targeted therapies that have been shown to be effective in several cancers, oncologists must decide on the extent of workup that is warranted. Specifically, they must consider how additional diagnostic procedures may affect the choice of therapy and the patient's survival and quality of life.

The reason why tumors present as CUP remains unclear. One hypothesis is that the primary tumor either regresses after seeding the metastasis or remains so small that it is not detected. It is possible that CUP falls on

the continuum of cancer presentation where the primary has been contained or eliminated by the natural body defenses.³ Alternatively, CUP may represent a specific malignant event that results in an increase in metastatic spread or survival relative to the primary. Whether the CUP metastases truly define a clone that is genetically and phenotypically unique to this diagnosis remains to be determined.^{3,4} Because all these reasons, liver metastasis is a serious and costly complication of cancer. The extent of angiogenesis in CUP relative to that in metastases from known primaries has also been evaluated, but no consistent findings have emerged.

Physical examination, including a digital rectal examination in men and breast and pelvic examinations in women, should be performed. Determining the status of patient's performance, nutritional status, co-morbidities and cancer-induced complications are essential as it may affect the treatment strategies.

Most tumor markers, including CEA, CA-125, CA 19-9, and CA 15-3, when the levels are increased, are nonspecific and they are not helpful in determining the primary tumor site. Men who present with the signs and symptoms of adenocarcinoma and osteoblastic metastasis should undergo PSA test. Patients with an elevated PSA level should be treated as having prostate cancer.⁶

In patients with undifferentiated or poorly differentiated carcinoma (especially those with a midline tumor), elevated β -human chorionic gonadotropin (β hCG) and α fetoprotein (AFP) levels suggest the possibility of an extragonadal germ cell (testicular) tumor. Cytogenetic studies had a larger role in the past and the interpretation of these older studies can be challenging. They are indicated only occasionally. We reserve them for undifferentiated neoplasm with inconclusive immunohistochemical stains and for those for with a high suspicion of lymphoma.

Chest X-rays are always planned, but the results are often negative, especially with low-volume disease. CT scans of the chest, abdomen, and pelvis can be used to help finding the primary tumor, evaluating the extent of disease, and selecting the most favorable biopsy site. Older studies suggested that the primary tumor site is

detected in 20–35% of patients who undergo a CT scan of the abdomen and pelvis; although by current definition these patients would not be considered as having CUP.

Older studies also suggest a latent primary tumor prevalence of 20%; however, with more sophisticated imaging, this prevalence is <10% today. A conventional workup for a cervical CUP (a neck lymphadenopathy with unknown primary tumor) includes a CT scan or MRI and invasive studies such as indirect and direct laryngoscopy, bronchoscopy, and upper endoscopy. 18 F-fluorodeoxyglucose (FDG) positron emission tomography (PET) scans are useful in this patient population and it may help in guided biopsy, determining the extent of disease, facilitating the appropriate treatment including planning radiation fields and providing help with disease surveillance.⁶

Invasive study including upper endoscopy, colonoscopy, and bronchoscopy, should be limited to symptomatic patients or those with laboratory or pathologic abnormalities. It suggests that these techniques will result in a high tumor yield.

On light microscopy, 60% of CUPs are found to be adenocarcinoma and 5% are squamous cell carcinoma. The remaining 30% of lesions are diagnosed as poorly differentiated adenocarcinoma, poorly differentiated carcinoma, or poorly differentiated neoplasm. A small percentages of lesions are diagnosed as neuroendocrine cancers (2%), mixed tumors (adenosquamous, or sarcomatoid carcinomas), or undifferentiated neoplasm.

In the absence of a known primary cancer, developing therapeutic strategies for CUP is challenging.^{5,7} The current diagnostic yield with imaging and immunochemistry is ~20–30% for CUP patients. The use of gene expression studies holds the promise of substantially increasing this yield. Gene expression profiles are most commonly generated using quantitative RT-PCR or DNA micro array.

It is often confused in early identification of primary site and management to prevent complication of the liver. By a thorough understanding of the etiologic factors and deforming forces, treatment can be planned for

each specific patient.⁸⁻¹⁰

Virchow's node (or signal node) is a lymph node in the left supraclavicular fossa (the area above the left clavicle). It takes its supply from lymph vessels in the abdomen cavity. The finding of an enlarged and hard node (also referred to as Troisier's sign) has long been regarded as strongly indicative for the presence of cancer in the abdomen, particularly the gastric cancer that has spread through the lymph vessels.

CONCLUSION

The liver metastasis commonly remains unrecognized, particularly in the acute phase, until severe complications occur.

We should perform biopsy although we could only find minimal lesion in colonoscopy / endoscopy examination

Early recognition and diagnosis as well as treatment strategies can be better formulated for the possible outcomes.

REFERENCES

1. Jones RS, Schlesinger MH. Cancer of colon and rectum. In: Schlesinger MH, Fardtran IF, eds. *Cancer colon and rectum*. Philadelphia: WB Saunders; 1998. p. 1784-99.
2. Anderson R. Secondary tumour of liver. Muir's textbook of surgical pathology. London: The English Language Book Society and Edward Arnold; 1996. p. 640.
3. Abbruzzese JL. The biology of unknown primary tumors. *Semin Oncol*. 1993;20:238.
4. Bugat R. Summary of the standards, options and recommendations for the management of patients with carcinoma of unknown primary site. *Br J Cancer*. 2003;89 (Suppl 1):S59.
5. Culine S. Cisplatin in combination with either gemcitabine or irinotecan in carcinomas of unknown primary site: Results of a randomized phase II study—trial for the French Study Group on Carcinomas of Unknown Primary (GEFCAPI 01). *J Clin Oncol*. 2003;21:3479.
6. Dennis JL, Oienka. Hunting the primary: novel strategies for defining the origin of tumours. *J Pathol*. 2005;205:236.
7. Greco FA, Hainsworth JD. One-hour paclitaxel, carboplatin, and extended-schedule etoposide in the treatment of carcinoma of unknown primary site. *Semin Oncol*. 1997;24(6 Suppl 19):S19.
8. Kende AI. Expression of cytokeratins 7 and 20 in carcinomas of the gastrointestinal tract. *Histopathol*. 2003;42:137.
9. Lobins R, Floyd J. Small cell carcinoma of unknown primary. *Semin Oncol*. 2007;34:39.
10. Olson JA, Jr. Magnetic resonance imaging facilitates breast conservation for occult breast cancer. *Ann Surg Oncol*. 2000;7:411.