

# A Case Report of Profuse Bleeding in the Lower Gastrointestinal Tract due to Dieulafoy Lesion in the Rectum

Saskia A. Nursyirwan<sup>1\*</sup>, Roy Soetikno<sup>1,2</sup>, Noto Dwimartutie<sup>3</sup>, Kaka Renaldi<sup>1</sup>

<sup>1</sup>Division of Gastroenterology, Pancreatobiliary, and Digestive Endoscopy, Department of Internal Medicine, Faculty of Medicine Universitas Indonesia - dr. Cipto Mangunkusumo Hospital, Jakarta, Indonesia.

<sup>2</sup>Division of Gastroenterology and Hepatology, San Francisco Veterans Affairs Medical Center, San Francisco, California, USA.

<sup>3</sup>Division of Geriatric, Department of Internal Medicine, Faculty of Medicine Universitas Indonesia - dr. Cipto Mangunkusumo Hospital, Jakarta, Indonesia.

## \*Corresponding Author:

Saskia A. Nursyirwan, MD. Division of Gastroenterology, Pancreatobiliary, and Digestive Endoscopy, Department of Internal Medicine, Faculty of Medicine Universitas Indonesia - Cipto Mangunkusumo Hospital. Jl Diponegoro no. 71, Jakarta Pusat, Indonesia. email: saskia.aziza@gmail.com.

## ABSTRACT

*Dieulafoy lesion is a rare condition that usually occurs in cases of gastric bleeding in the upper gastrointestinal tract. However, this condition can also occur in the lower gastrointestinal tract but less frequently. The lesion is an arteriolar malformation that extends to the submucosa, causing erosion and bleeding. Meanwhile, this is a case of a 67-year-old woman presenting with a bright red bloody stool prior to admission, as well as a history of constipation which was relieved by digital stool evacuation two weeks earlier. The medical history of the patient reveals episodes of repeated ischaemic stroke for over seven years and three months, which has led to other conditions such as right-sided paralysis, transcortical motor aphasia, and neurogenic dysphagia. The patient was routinely on antithrombotic medications, which was stopped during hospitalisation where repeated packed cell transfusion was done in order to avoid hemochezia. The patient needed the support of her caregiver most of the time since she was bedridden. Furthermore, the haemostasis and platelet function of the patient were normal. On colonoscopy, there was the discovery of a small lesion of about 3mm in her rectum, protruding into the lumen and pulsated, which was discovered to be Dieulafoy's lesion. Subsequently, this lesion was closed using rubber band ligation, and after a month, there was no recurrence of the lower gastrointestinal bleeding.*

**Keywords:** Hematochezia, lower gastrointestinal bleeding, Dieulafoy's lesion, ligation.

## INTRODUCTION

Dieulafoy lesion (DL), also known as caliber persistent artery, is a rare cause of gastrointestinal bleeding. This condition accounts for about 6% of gastrointestinal nonvariceal bleeding, and about 1% to 2% of all acute gastrointestinal hemorrhages.<sup>1</sup> The difficulty in making a correct diagnosis makes DL seem like a rare condition. However, it is believed that it occurs more

frequently in reality than what is reported. DL can occur in the stomach, duodenum, oesophagus, colon and rectum at 71%, 15%, 8%, 2% and 2%, respectively, as well as the jejunum-ileum and gastric anastomosis at 1% each.<sup>2</sup>

An artery of the GI tract will usually narrow as it gradually passes through the wall of the end organ. A DL is characterized by a vessel with an abnormally large diameter of about 1 to

3 mm, as it follows a tortuous path through the submucosa. This causes a lesion that typically protrudes through the submucosal membrane as a defect, ranging in size from 2 to 5 mm and containing fibrinoid necrosis at its base.<sup>3</sup> The difficulty in diagnosing lesions during endoscopy may be due to the heavy bleeding that occurs at the surrounding, as well as the small size of the lesions. There is no consensus concerning the treatment of DL, which could vary depending on the symptoms presented in the patient, site of the lesion, and the experts available during therapy. Also, the evolution of endoscopic methods of haemostasis has significantly reduced the need for surgery in DL.<sup>2</sup>

### CASE ILLUSTRATION

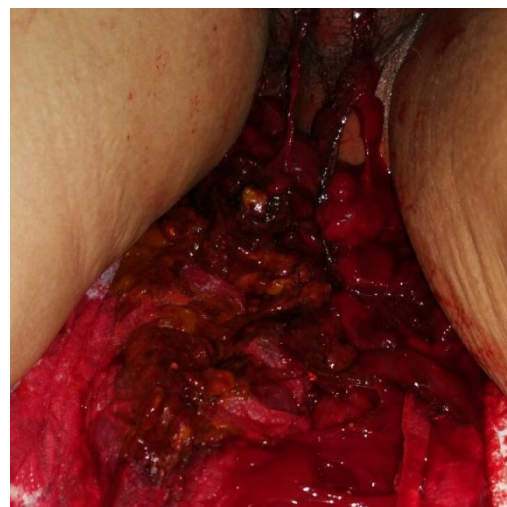A 67-year-old woman presented with a bright red bloody stool for about two weeks before admission to the hospital, where she denied feeling any pain in her abdomen. The patient had a history of constipation, which was relieved by digital stool evacuation two weeks earlier. Also, the medical history of the patient shows repeated ischemic strokes for over seven years and three months, which progressed to other conditions, such as right-sided paralysis, transcortical motor aphasia, and neurogenic dysphagia. The patient was previously diagnosed with diabetes mellitus and hypertension, and was on antithrombotic medication regularly. The support of a caregiver was required most of the time since the patient was bedridden. During a previous visit to the hospital, the patient underwent a colonoscopy that revealed a giant adenoma polyp in the sigmoid. Subsequently, this was removed through polypectomy, but the patient continued to have recurrent lower gastrointestinal bleeding. However, abdominal CT scan and esophagogastroduodenoscopy revealed no significant findings from previous checkups in the hospital.

The patient was fully alert on physical examination, despite having aphasia as a result of her stroke. The vital signs of the patient, such as the body mass index (BMI), blood pressure and pulse rate were 20 kg/m<sup>2</sup>, 120/70 mmHg and 98 beats per minute, respectively. Furthermore, pallor conjunctiva was observed, with the absence

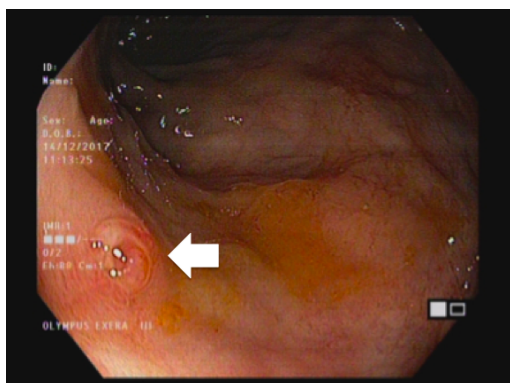
of organomegaly, palpable mass, or tenderness in any region of the abdomen, according to the abdominal examination. The patient was completely bedridden due to the right-sided paralysis she experienced. Other examinations conducted were insignificant since her platelets and haemostasis function were both normal.

Also, the patient presented with repeated bloody stool in our ward, with a total of about 200-300cc in each episode of bleeding, and received recurrent packed red cell transfusions when there was a drop in the haemoglobin level after bleeding from about 10 g/dl to 4 g/dl.

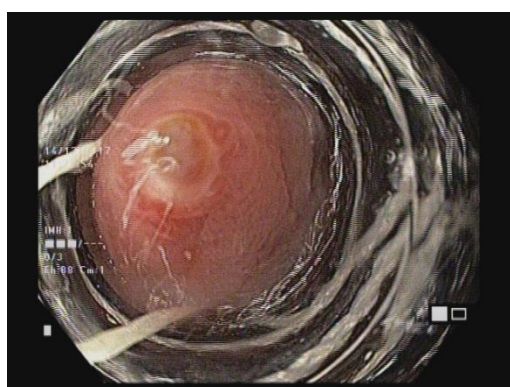On colonoscopy, there was the discovery of a fibrin-based ulcer on the sigmoid without any active bleeding, which confirmed that polypectomy was previously carried out in that area. However, the patient developed hematochezia, which prompted enteroscopy that revealed erosive enteritis without active bleeding. She did not recover from the recurrent haemorrhage despite the discontinuation of antithrombotic therapy from the first onset of bleeding, and the administration of a proton pump inhibitor, as well as other drug analogues, such as rebamipide, and sucralfate. Therefore, another colonoscopy was performed to determine the source of the bleeding. Eventually, a Dieulafoy lesion was found, which was in the form of a pulsated ulcer, with a diameter of 3 mm. Furthermore, it was at about 2 cm from the anocutaneous line, protruding into the lumen. Ligation was then performed on the lesion, and



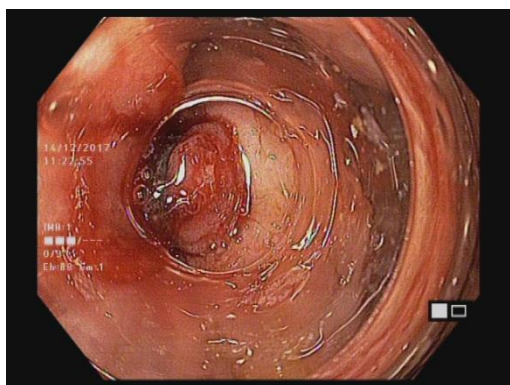
**Figure 1.** Massive hematochezia on each episode of bleeding.



**Figure 2.** Dieulafoy lesion presented as a 3mm, pulsated lesion in the rectum.



**Figure 3.** Rubber band ligation of Dieulafoy lesion.



**Figure 4.** Dieulafoy lesion post rubber band ligation.

after a month, the patient confirmed that she no longer experienced lower gastrointestinal bleeding during the follow-up.

## DISCUSSION

Despite its rarity, Dieulafoy's lesion should always be considered as a cause of gastrointestinal bleeding due to its potential to cause massive, life-threatening, and recurring

bleeding, as well as its amenability to life-saving endoscopic therapy. DL occurs mostly in the stomach, with only a small percentage of cases occurring in the lower gastrointestinal tract. According to epidemiological data, males are more likely to be affected than females at a proportion of approximately 2:1.<sup>2</sup> Furthermore, this condition can occur within any age group, but the majority of reported cases were older people, particularly those in their sixth or seventh decades. Non-gastrointestinal comorbidities such as cardiovascular disease, hypertension, diabetes, and chronic renal insufficiency are common in affected patients. Patients who are on nonsteroidal anti-inflammatory drugs (NSAIDs) or anticoagulants may also experience bleeding symptoms, which increases the likelihood of bleeding due to Dieulafoy lesions.<sup>4</sup> All of these conditions are consistent with the age and comorbidity of our patient.

Meanwhile, the patient usually presented with sudden, massive gastrointestinal bleeding, which led to a hemodynamically unstable condition that required multiple blood transfusions. Also, the initial gastrointestinal endoscopy is only useful in diagnosing up to 70% of patients. That low rate is due to the small and inconspicuous lesions, which cannot be observed during examination.<sup>5</sup> However, we could use CT angiography if endoscopy fails to locate the source of the bleeding, but its role is limited due to a lack of therapeutic capabilities.

Endoscopic therapy can be classified into three, which include ablation, mechanical therapy and injection involving the use of epinephrine or sclerosing agent. The most effective is mechanical therapy, such as band ligation or endoscopic clips, which has been shown in some studies to stop bleeding by mechanically closing off the bleeding vessel.<sup>6,7</sup> According to studies, band ligation in rectal Dieulafoy is relatively safe and effective in the treatment of active bleeding from colorectal Dieulafoy lesion.<sup>8,9</sup>

Additionally, there are other options aside from endoscopic therapy, which include angiography and embolization, as well as surgical treatment. In cases where endoscopic therapy fails to stop the bleeding, angiography can be used to embolize the active bleeding caused by

the DL. However, embolization increases the risk of bowel ischaemia in the area supplied by the relevant artery.<sup>2</sup> Lastly, surgery is reserved for 5% of the cases that are not amenable to endoscopic or angiographic methods.<sup>3</sup>

## CONCLUSION

DL should be considered as a potential cause of profuse gastrointestinal bleeding. Mechanical endoscopic therapy such as band ligation of the rectum is relatively safe and effective in the treatment of active bleeding from colorectal DL.

## REFERENCES

1. Jeon HK, Kim GH. Endoscopic management of Dieulafoy's lesion. *Clin Endosc.* 2015;48(2):112–20.
2. Baxter M, H Aly E. Dieulafoy's lesion. *Current Trends Diagnosis and Management.* 2010;92:548.
3. Chaer RA, Helton WS. Dieulafoy's disease. *J Am Coll Surg.* 2003;196(2):290–6.
4. Nojkov B, Cappell MS. Gastrointestinal bleeding from Dieulafoy's lesion: Clinical presentation, endoscopic findings, and endoscopic therapy. *World J Gastrointest Endosc.* 2015;7(4):295–307.
5. Marangoni G, Cresswell AB, Faraj W, Shaikh H, Bowles MJ. An uncommon cause of life-threatening gastrointestinal bleeding: 2 synchronous Dieulafoy lesions. *J Pediatr Surg.* 2009;44(2):441–3.
6. Chung I-K, Kim E-J, Lee M-S, et al. Bleeding Dieulafoy's lesions and the choice of endoscopic method: Comparing the hemostatic efficacy of mechanical and injection methods. *Gastrointest Endosc.* 2000;52(6):721–4.
7. Alis H, Oner OZ, Kalayci MU, et al. Is endoscopic band ligation superior to injection therapy for Dieulafoy lesion? *Surg Endosc.* 2009;23(7):1465–9.
8. Vandervoort J, Montes H, Soetikno RM, Ukomadu C, Carr-Locke DL. Use of endoscopic band ligation in the treatment of ongoing rectal bleeding. *Gastrointest Endosc.* 1999;49(3):392–4.
9. Gil Park J, Chul Park J, Hwan Kwon Y, Young Ahn S, Jeon S. Endoscopic management of rectal Dieulafoy's lesion: A case series and optimal treatment. *Clin Endosc.* 2014;47:362–6.