

The Management of Pulmonary Fibrosis in COVID-19

Cleopas Martin Rumende, Erwin C. Susanto, Truely P. Sitorus

Division of Respiriology and Critical Care, Department of Internal Medicine, Faculty of Medicine Universitas Indonesia - Cipto Mangunkusumo Hospital, Jakarta, Indonesia.

Corresponding Author:

Cleopas Martin Rumende, MD, PhD. Division of Respiriology and Critical Care, Department of Internal Medicine, Faculty of Medicine Universitas Indonesia - Cipto Mangunkusumo Hospital. Jl. Diponegoro no. 71, Jakarta 10430, Indonesia. email: rumende_martin@yahoo.com.

ABSTRAK

Fibrosis paru pasca infeksi COVID-19 dapat terjadi akibat komplikasi ARDS yang ditandai dengan adanya kegagalan re-epitelisasi alveolar, aktivasi fibroblast, akumulasi kolagen dan matriks ekstraseluler lain secara berlebihan sehingga menyebabkan kelainan arsitektur paru. Ada beberapa faktor risiko untuk terjadinya fibrosis paru pasca-COVID yaitu usia lanjut, riwayat ARDS, penggunaan ventilator mekanik yang dapat menyebabkan terjadinya injury paru, riwayat merokok dan konsumsi alkohol. Diagnosis fibrosis paru pasca-COVID ditegakkan berdasarkan gejala klinis dan gambaran karakteristik kelainan CT scan paru. Hingga saat ini belum ada terapi definitif untuk fibrosis paru pasca-COVID, namun beberapa obat antifibrosis dapat dipertimbangkan untuk diberikan. Selain terapi medika mentosa, rehabilitasi paru dan terapi oksigen jangka panjang juga harus merupakan bagian dalam tatalaksana komprehensif fibrosis paru pasca-COVID-19.

Kata kunci: fibrosis paru, COVID-19.

ABSTRACT

Pulmonary fibrosis due to COVID-19 is recognized as sequel of ARDS characterized by failed alveolar re-epithelization, fibroblast activation, excessive collagen deposition and other extracellular matrix components that disrupt the normal lung architecture. There are risk factor for pulmonary fibrosis namely advanced age, severe ARDS infection, mechanical ventilation due to ventilator-induced lung injury, smoking and chronic alcoholism. Diagnosis of post-COVID pulmonary fibrosis can be made by clinical symptoms and characteristic finding from lung CT scan. To date, there is no definitive treatment for post-inflammatory pulmonary fibrosis after COVID-19 infection, however some of antifibrotic therapies may be considered. Beside medical treatment, pulmonary rehabilitation program and long-term oxygen treatment should be included as part of comprehensive treatment for pulmonary fibrosis due to COVID-19.

Keywords: pulmonary fibrosis, COVID-19.

INTRODUCTION

The novel coronavirus disease (COVID-19) pandemic caused by severe acute respiratory syndrome coronavirus 2 (SARS-CoV-2), has generated huge concern for high mortality and lack of specific and effective treatment. The most critically ill patients in the context of SARS-

CoV-2 infection may develop acute respiratory distress syndrome (ARDS). It has been found that 40% of patients with COVID-19 develop ARDS, and 20% of ARDS cases are severe.¹ Pulmonary fibrosis is recognised as sequel of ARDS characterized by failed alveolar re-epithelization, fibroblast activation, excessive

collagen deposition and other extracellular matrix (ECM) components that disrupt the normal lung architecture. Excessive deposition of ECM is therefore central to the process of lung fibrosis. It manifests as an irregular interlobar septal thickening and reticular pattern with traction bronchiectasis on chest CT scan.² The prevalence of post-COVID 19 fibrosis will become apparent with time, but early analysis from patients with COVID-19 on hospital discharge suggest that more than a third of recovered patients develop fibrotic abnormalities. A study of Italian COVID-19 pandemic survivors found that as many as 45% patients still complained of dyspnea at follow up visit conducted a mean of 60 days after the initial onset of the symptom. A follow-up study by Zhao et al.³ of pulmonary function and radiology in 55 COVID-19 survivors 3 months after recovery showed that 71% had residual CT abnormalities, including evidence of interstitial thickening in 27%. Abnormal lung function has also been identified at the time of discharge from the hospital and after 2 weeks later in up to 47% cases. Restrictive ventilatory defects is the most common abnormality of lung function seen in about 25% of cases. The pulmonary function abnormalities being worse in those with severe acute infection.

Follow up of cohorts of post-COVID survivors are already underway at several centers to determine whether fibrosis changes on CT scan are persist or gradually improved or even worsen with the passage of time. This has implications not only for patient prognosis but also for treatment. Antifibrotic may have an important role in patients with progressive lung fibrosis (**Figure 1**).³

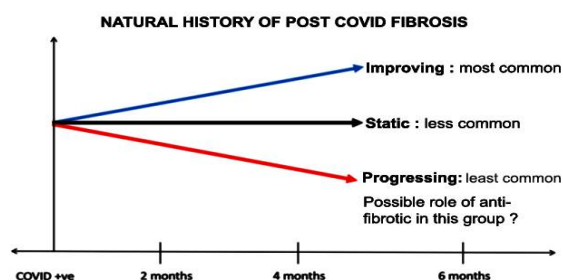


Figure 1. The natural history of post-COVID pulmonary fibrosis will be one of three possible course.

Compared with the last CT scan before discharge, the abnormalities (including focal/multiple GGO, consolidation, interlobular septal thickening, subpleural lines and irregular lines) in lung are gradually absorbed in the first and second follow-ups after discharge. The lung lesion of 64.7% discharged patients were fully absorbed after 4-week follow-up. It indicates reversible lung tissue damage of COVID-19 cases. It also suggest that the prognosis of non-severe patients is favourable, and clinical intervention should be conducted to prevent the worsening of COVID-19 patients.¹

RISK FACTORS FOR PULMONARY FIBROSIS IN SARS-COV-2

The factors mediating a profibrotic response to SARS-CoV-2 virus are not fully known, but from some studies suggest that age, severity of illness, use of mechanical ventilation, smoking and chronic alcoholism may contribute.^{2,4}

Age. Pulmonary fibrosis is reported more often in patients with advance age. The median age for diagnosis is 65 years, and it rarely occurs before 50 years. In a follow-up study, advance age correlated with the risk of developing pulmonary fibrosis at 6 months after discharge. The exact reason for this association is unknown; however, older patient are more susceptible to both SARS and MERS similar to SARS-CoV-2 infection and more likely to have severe symptoms.^{2,4}

Illness Severity. According to World Health Organization, 80% of SARS-CoV-2 infection are mild, 14% develop severe symptoms, and 6% will become critically ill. Factors associated with increased diseases severity include comorbidities such as hypertension, diabetes and coronary artery disease. Laboratory findings of lymphopenia and elevated lactate dehydrogenase (LDH) correlate with increased disease severity. Serum LDH level has been used as marker of disease severity following acute lung injury. It is an indicator of pulmonary tissue destruction and correlate with the risk of mortality. The extent of lung injury and inflammatory respons correlate with the extent of fibroblastic response required to repair the injury. Peaked LDH level was found to significantly correlate with the risk of pulmonary fibrosis following MERS-

CoV infection. Similarly, a follow-up study at 6 months after discharge in SARS patients show a significant relation between elevated levels of LDH during acute illness and an increased risk of developing pulmonary fibrosis.²

Length of ICU stay and Mechanical Ventilation. ICU care is required in 5-12% of COVID-19 patients, with the criteria for ICU admission varying from one region to another. While disease severity is closely related to the length of ICU stay, mechanical ventilation poses an additional risk of ventilator-induced lung injury (VILI). Ventilator-induced lung injury is an acute lung injury arising from or exacerbated by mechanical ventilation. Abnormalities of pressure or volume setting underlie this injury leading to release of proinflammatory mediators, worsening acute lung injury and increased mortality or pulmonary fibrosis in survivors. In a follow-up study of 27 patients who had mechanical ventilation for ARDS, 110-267 days after extubation, 23 patients (85%) had pulmonary fibrosis with a significant relationship to the duration of pressure-controlled inverse-ratio ventilation.²

Smoking. Smoking has been linked to the pathogenesis of various lung disease such as emphysema, chronic bronchitis and pulmonary fibrosis. Smoking is associated with chronic oxidative stress, increased expression of inflammatory cytokine and interstitial lung fibrosis. The injury associated with smoking continues even after cessation. A systemic review

shows that smokers were 1.4 times more likely to have severe symptoms of COVID-19 and 2.4 times more likely to need ICU admission and mechanical ventilation or die compared to nonsmokers.²

Chronic Alcoholism. Chronic alcoholism has been cited a predisposing factor for severe respiratory infection. Alcohol abuse is associated with recurrent pneumonia due to gastric aspiration. There is also evidence of additional injury to the lung in chronic alcoholism. Chronic alcoholism may cause glutathione depletion, chronic oxidative stress, inflammation and induction of TGF- β in the lung, thereby increasing the risk of acute lung injury and pulmonary fibrosis.²

PATHOGENESIS

Although ARDS seems to be the main predictor of pulmonary fibrosis in COVID-19, several studies showed that COVID induced ARDS is different from the classical ARDS. Result from CT scan finding in many cases are also not suggestive of classical ARDS. Therefore mechanism of pulmonary fibrosis in COVID-19 is different from that of idiopathic pulmonary fibrosis (IPF), especially with pathological findings pointing to alveolar epithelial cells being the site of injury and not the endothelial cells.¹ Based on pathological pattern of pulmonary fibrosis, the clinical process of COVID-19 patients can be divided into three stages (**Figure 2**).⁵ The first stage: the SARS-CoV-2 has just invaded the upper respiratory tract. Patients

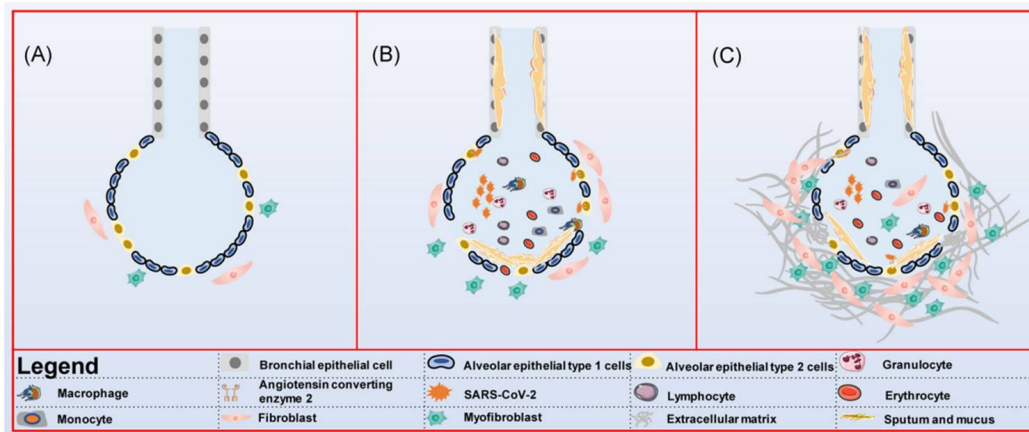


Figure 2. Pathological pattern of pulmonary fibrosis caused by COVID-19.

often have only cough, fatigue and sore throat. From the imaging there is no manifestation of pneumonia. If the patient's immunity are strong enough at this time, it can be self-limited. The second stages: the stages of acute inflammatory reaction. Patients usually have fever, obvious respiratory tract symptoms (shortness of breath, dyspnea) and other symptom such as diarrhea. At this stage there are large number of inflammatory cells infiltrated in the lung and pneumonia could be seen in pulmonary tomography imaging. There is also a small number of fibroblast and myofibroblasts proliferate to repair damages alveolar epithelial cells (mainly type II alveolar epithelial cells). The third stage: the late stage of inflammation or recovery stage. With the improvement of the disease, pulmonary inflammation gradually decreased. However, due to the necrosis and shedding of abundant alveolar epithelial cells in previous stage, the human body initiate damage repair mechanisms through myofibroblast proliferation and extracellular matrix aggregation and finally the pulmonary fibrosis will occur. It is worth noted that the second and third stages often have no strict boundaries, and often develop simultaneously.⁵

The mechanisms by which SARS-CoV-2 infection cause pulmonary fibrosis are not fully understood. Most of study suggest that cytokine (especially Transforming Growth Factor- β /TGF- β), fibroblast, angiotensin converting enzyme 2, ventilator induced-lung injury (VILI) and oxygen toxicity have an important role for developing of pulmonary fibrosis in COVID-19

(Figure 3).^{2,6}

Cytokine and fibroblast. The alveolar wall has three components: the alveolar epithelium with its basement membrane, capillary endothelium with a basement membrane and an interstitium containing fibroblast, collagen fibrils, elastic fiber and macrophages. Pulmonary fibrosis usually occurs as a consequence of severe assault of the lung that cause alveolar wall injury. It occur as a result of dysregulation in one or more of the phases of wound healing: injury, inflammation and repair. SARS-CoV-2 can be act as inciting factor for alveolar wall injury. Fibroblasts as the effector cells in fibroproliferation are found in the alveolar interstitium. Following alveolar injury, fibroblast migration to site of injury is stimulated by fibroblast growth factor (FGF), platelet-derived growth factor (PDGF), TGF- β and chemokines. Fibroblast proliferate and differentiate in to myofibroblast under the influence of vascular endothelial growth factor (VEGF), PDGF, TGF- β and IL-1. Fibroblast synthesize collagen, fibronectin and extracellular matrix (ECM) ground substance. In addition, mediators of repair process such as VEGF and TGF- β are secreted by myofibroblast. Myofibroblast produce denser but more disorganized ECM than fibroblast and persist longer at the site of injury. Transforming growth factor- β is multifunctional cytokine playing a key role in the process of tissue repair following injury. Importance source of TGF- β including granule of platelets and macrophage. Transforming growth factor- β is

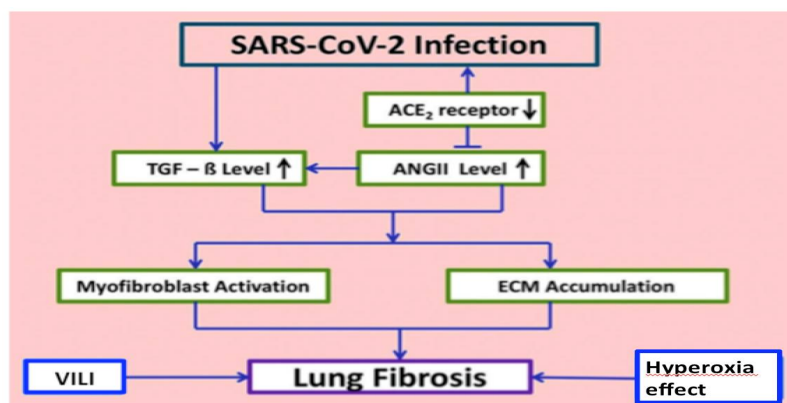


Figure 3. Postulated mechanism of SARS-CoV2 induced pulmonary fibrosis stressing the pivotal role of Angiotensin 2.

predominantly expressed in the pathogenesis of pulmonary fibrosis because it stimulates extracellular matrix formation namely collagen, fibronectin, elastic fibres and ground substance. Transforming growth factor- β has fibrogenic potential by stimulating fibroblast migration and proliferation, inducing collagen and fibronectin deposition and inhibiting ECM degradation by matrix metalloproteinases. The stimulation of ECM deposition and inhibition of breakdown is fundamental to excessive accumulation of scar tissue in fibrosis. Platelet-derived growth factor are potent stimuli for migration and proliferation of fibroblast and has been reported as one of growth factors playing a key role in pulmonary fibrosis.^{2,6}

Angiotensin Converting Enzyme-2.

Molecular basis of progression to pulmonary fibrosis in COVID-19 is still unclear, but is believed to be multifactorial. The role of renin-angiotensin system has also been looked at with great interest as the high-affinity binding between the SARS-CoV-2 viral spike protein and the angiotensin-converting enzyme-2 (ACE2) receptor. Interaction between SARS-CoV-2 and ACE2 receptor has been shown to down regulate the level of the ACE2 receptor. Angiotensin-converting enzyme-2 have protective role in lung fibrosis. The decreased ACE-2 expression in turn leads to high angiotensin 2 (ANG II) level. ANG II is a potent vasoconstrictive peptide directly involved in development of inflammation and fibrosis. In addition to its role in regulating blood pressure, ANG II plays a pivotal role in fibrotic process signaling cellular and molecular events that lead to the development of aberrant wound healing and pulmonary fibrosis. These include production of pro-inflammatory cytokines such as IL-6 and IL-8, production of reactive oxygen species among infected alveolar cells and activation of TGF- β which in turn leads to proliferation, migration and differentiation of fibroblasts to myofibroblasts with resultant deposition of collagen and fibronectin.^{2,6}

Oxygen toxicity and VILI. The role two iatrogenic factors potentially contributing to the fibrosis encountered in survivor of severe COVID-19 pneumonia are oxygen toxicity and ventilator induced lung injury (VILI).

Patients who develop post-COVID lung fibrosis are invariably those who are more sick with extensive, bilateral lung involvement, hence are more likely to required high oxygen concentration. High oxygen concentration on the other side; may result in heightened production of oxygen-derived free radicals which can damage the pulmonary epithelium. The sickest patients with ARDS from COVI-19 pneumonia are also more likely to require prolonged mechanical ventilation, often with generation of high plateau pressures in attempts to ventilate the stiff, noncompliant lungs. The role of mechanical stress as an inciting factor for lung injury is also well recognized and it is likely that VILI may also contribute to the pulmonary fibrosis.^{2,6}

CLINICAL MANIFESTATIONS

Pulmonary fibrosis presents with the following symptoms : dry cough, fatigue and dyspnea. Furthermore physical condition of the patients may deteriorates, accompanied by reducing of their body weight. Therefore, the quality of life patients suffering from this disorder are systematically regresses.⁶ Knowledge of the natural evolution of lung abnormalities in COVID-19 may help the clinician to determine the stage of disease and indistinguishing them from potential complications when evaluating chest CT examinations. Roughly four stages of COVID-19 at chest CT scan have been described : (a) Early stage (0-5 days after symptom onset), which characterized by either normal findings or mainly ground-glass opacities; (b) Progressive stage (5-8 days after symptom onset), which is characterized by increased ground-glass opacities and crazy-paving appearance;(c) Peak stage (9-13 days after symptom onset) which is characterized by progressive consolidation and (d) late stage (?14 days after symptom onset), which is characterized by a gradual decrease of consolidation and ground-glass opacities, while signs of pulmonary fibrosis may appear. Pulmonary fibrosis signs consisting of parenchymal bands, architectural distorsion and traction bronchiectasis (**Figure 4**). It should be noted that the temporal evolution and extend of lung abnormalities are heterogenous among different patients, dependent on the severity of

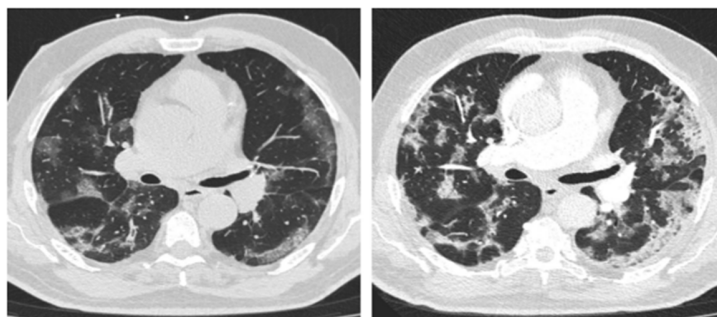


Figure 4. Natural evolution from ground-glass opacities to multifocal organizing consolidation.

the disease.⁷

Previous studies highlight that duration of disease is an important determinant for developing of post-ARDS pulmonary fibrosis. This study showed that 4% of patients with a disease duration of less than 1 week, 24% of patients with a disease duration of between weeks 1 and 3, and 61% of patients with a disease duration of greater than 3 weeks, developed fibrosis.¹

DIAGNOSIS

The diagnosis of pulmonary fibrosis requires integration of clinical symptoms and radiologic information and history of severe ARDS due to COVID-19. Clinical symptoms of pulmonary fibrosis consisting of dry cough, fatigue and dyspnea.⁶ Lung CT scan finding from pulmonary fibrosis consisting of parenchymal bands, architectural distortion and traction bronchiectasis.⁷ Although there is no specific finding from laboratory testing, TGF- β and VEGF may increase as a marker of pulmonary fibrosis.

MANAGEMENT

Until now there is no specific therapy to handle post-inflammatory pulmonary fibrosis due to COVID-19 infection. Several studies are on going to determine an effective treatment for this chronic complication. While ARDS seems to be the main cause of pulmonary fibrosis in COVID-19, the pathogenesis of ARDS caused by SARS-CoV-2 is different from the typical ARDS. Some therapies may be considered for reducing the fibrosis process in lung after COVI-

19 infection namely pirfenidone, nintedanib and mesenchymal stem cells.⁸⁻¹¹ Based on WHO guideline for clinical management of COVID-19, treatment with antifibrotic agent should be in context of clinical trial. Therefore for the legal aspect, outside of clinical trial all of these antifibrotic drugs should be given as investigational therapeutics based on the following criteria : no proven effective treatment exist, preliminary data from serial cases reports support the efficacy and safety of these drugs, treatments has been suggested by qualified scientific advisory committee on the basis of a favourable risk-benefit analysis, appropriately qualified ethich committee have approved such use, the patients informed consent is obtained and the results are documented and shared in timely manner with the wider medical and scientific community.¹²

Pirfenidone. Pirfenidone is a pyridone that is 2-pyridone substituted at positions 1 and 5 by phenyl and methyl groups respectively. Pirfenidone has both antifibrotic and anti-inflammatory properties and is able to mitigate the proliferation of fibroblast and production of protein and cytokines associated with fibrosis. It also mitigates the accumulation of extracellular matrix in response to cytokine growth factors such as TGF- β and PDGF. Pirfenidone can be administered as a monotherapy or combined with anti-inflammatory drug, IL-1 or IL-6 inhibitor which will exhibit a synergy effect in reducing its complication. The efficacy of pirfenidone has yet to be determined. Pirfenidone is given according to the principle of gradual increase in drug dose. The first week of treatment is 267

mg three times daily; second week of treatment is 534 mg three times daily, the third week and after is 801 mg three times daily (taking it with meal). Pirfenidone is given for 4 weeks or more, depend on the clinical respons. Pirfenidone can be associated with hepatotoxicity, whereas liver dysfunction is common in patients infected with SARS-CoV-2. Evaluation of liver and kidney function is necessary especially in patients with risk of liver and kidney damage (glomerular filtration rate of less than 30 mL/min per 1.73 m²).⁸⁻¹¹

Nintedanib. Nintedanib act as tyrosine kinase inhibitor that works on the receptors for FGF, PDGF, VEGF and on non-receptor kinases results in a broad inhibitory activity on the downstream signalling cascades of fibroblasts and myofibroblasts and potentially also on cells involved in angiogenesis in the lung. Dose for nintedanib is 150 mg twice daily for 12 months, in addition to standard of care. Similar to pirfenidone, it should be taken with food. Nintedanib also relates to liver and kidney damage, therefore closely monitored for these organ function should be performed. If necessary the dose of nintedanib can be reduced to 100 mg twice daily to prevent occurring of the liver and kidney injury.^{7,9}

Mesenchymal stem cells (MSCs). Stem cells are the cells with a specific function with the ability of self-renewal, possess varied potency and differentiate into multilineages. Stem cell therapy has proven itself to be one of the most promising therapeutic approaches that provide opportunities to treat several diseases that were considered incurable like in post-COVID-19 pulmonary fibrosis. Mesenchymal stem cell therapy is preferred over other therapeutic strategies because they are free of ethical and social issues, they have a high proliferation rate and a low invasive nature. Mesenchymal cells are harvested from various sources, including adipose tissues, dental pulp, bone marrow, umbilical cord, fetal liver, various adult tissues (such as the infrapatellar fat pad, abdominal fat pad) and tissues associated with neonates (placenta, Wharton's jelly, cord blood, and amniotic fluid).¹³⁻¹⁹

Infection of COVID-19 triggers an

exaggerated immune reaction in the body by producing large amounts of various inflammatory factors including several cytokines, chemokines and immune reactive cells. The MSCs therapy might prevent the triggering of cytokine storm by the activated immune system, and the reparative properties of the stem cells might promote endogenous repair. Mesenchymal stem cells when intravenously injected will lead to some part of the population getting entrapped in the lungs. The pulmonary micro-environment could be recovered with the help of these MSCs, thus protecting the alveolar epithelial cells. Hence, pulmonary fibrosis of the lungs could be prevented, which may lead to curing COVID-19 caused pneumonia. In the multiple disease condition, the immunomodulatory effects will be responsible for improved function after MSCs infusion. A variety of paracrine factors are secreted by these cells. These paracrine factors interact with the immune cells, eventually leading to immunomodulation. The vigorous anti-inflammatory activities of MSCs will actually be responsible for improvements after their infusion in COVID-19 patients.¹¹⁻¹⁹

In the Guidelines for Quality Control and Preclinical Study of Stem Cell Preparations (Trial), indications for stem cell therapy in COVID-19 include severe or critical illness from COVID-19-related pneumonia. Mesenchymal stem cells can be given via intravenous injection or intravenous cell infusion with dosage 1×10^6 cells/kg. The dose can be repeated for 3 times with 5 days interval. Intravenous injection of MSCs may produce a first-order lung effect, which leads to significant cell retention in the lungs, thus providing an advantage for lung tissue repair in COVID-19.^{14, 16}

RESPIRATORY SUPPORT

Breathing Exercise. About 80% of the work of breathing is done by the diaphragm. After illness or general deconditioning, the breathing pattern may be altered, with reduced diaphragmatic movement and greater use of neck and shoulder accessory muscles. This results in shallow breathing, increasing fatigue and breathlessness, and higher energy expenditure. The "breathing control" technique is aimed at

normalizing breathing patterns and increasing the efficiency of the respiratory muscles (including the diaphragm) resulting in less energy expenditure, less airway irritation, reduced fatigue and improvement in breathlessness. The patient should sit in a supported position and breathe in and out slowly, preferably in through the nose and out through the mouth, while relaxing the chest and shoulders and allowing the tummy to rise. They should aim for an inspiration to expiration ratio of 1:2. This technique can be used frequently throughout the day, in 5-10 minute bursts (or longer if helpful).²⁰

Pulmonary Rehabilitation. Many patients are still recovering spontaneously in the first six weeks after acute COVID-19 infection and do not generally require fast-track entry into a pulmonary rehabilitation programme. Those who have had significant respiratory illness may benefit from pulmonary rehabilitation, defined as “a multidisciplinary intervention based on personalised evaluation and treatment which includes, but is not limited to, exercise training, education, and behavioural modification designed to improve the physical and psychological condition of people with respiratory disease.” In the context of COVID-19, rehabilitation is being delivered by various virtual models, including video linked classes and home education booklets with additional telephone support.²⁰

Pulse Oximetry Self Monitoring. Hypoxia may reflect impaired oxygen diffusion and is a recognized feature of COVID-19. It may be asymptomatic or symptomatic. Oxygen saturation probes (pulse oxymeters) have been used as part of a package of care for patients with COVID-19. Patients should be provided with pulse oximeter and an observational diary and given instructions for how to perform self monitoring. This would be a daily reading taken on a clean, warm finger without nail polish, after resting for 20 minutes; the device should be left to stabilize and the highest reading obtained should be recorded. The target range for oxygen saturation as 94-98% and a level of 92% or below as requiring supplementary oxygen (unless the patient is in chronic respiratory failure. Normal assessment without red flag, an oxygen saturation of 96% or above and the absence of

desaturation on exertional test is very reassuring. Oxymeter readings persistently in the 94-95% range or below require assessment and further investigation. Appropriate adjustments should be made for patients with lung disease and known in whom the range of 88-92% is considered acceptable.²⁰

CONCLUSION

Severe acute respiratory tract infection due to COVID-19 infection is an extremely serious disease. One of the complications of respiratory system infection is pulmonary fibrosis, leading to permanent disability. Diagnosis of pulmonary fibrosis can be made based on history of suffering from severe ARDS, following by clinical symptoms and characteristic pattern of pulmonary fibrosis from CT scan finding. There are few options available for its treatment. The most important factor in limiting pulmonary fibrosis is timely antiviral treatment and elimination of the causative agent. There is no fully definitive treatment for post-inflammatory pulmonary fibrosis after COVID-19 infection. Antifibrotic therapies may be considered consisting of pirfenidone, nintedanib and MSCs. Beside medical treatment, pulmonary rehabilitation program and longterm oxygen treatment should be included as part of comprehensive treatment for pulmonary fibrosis due to COVID-19.

REFERENCES

1. Rai DK, Sharma P, Kumar R. Post COVID-19 pulmonary fibrosis is it reversible? *Indian J Tuberculosis*. <https://doi.org/10.1016/j.ijb.2020.11.003>.
2. Ojo AS, Balogun SA, Williams OT, Ojo OS. Pulmonary fibrosis in COVID-19 survivors: Predictive factors and risk reduction strategies. *Pulmonary Medicine*. <https://doi.org/10.1155/2020/6175964>.
3. Udawadia ZF, Koul PA, Richeldi L. Post COVID-19 lung fibrosis: the tsunami that will follow the earthquake. *Indian Chest Society*. http://doi:10.4103/lungindia.lungindia_818_20.
4. McDonald LT. Healing after COVID-19: are survivors at risk for pulmonary fibrosis? *Am J Physiol Lung Cell Mol Physiol*. 2021;320:L257-65.
5. Zhang C, Wu Z, Li JW, et al. Discharge may not be the end of treatment: Pay attention to pulmonary fibrosis caused by severe COVID-19. *J Med Virol*. 2021;93:1378-86.
6. Lechowicz K, Drozdal S, Machaj F, et al. COVID-19:

- The potential treatment of pulmonary fibrosis associated with SARS-CoV-2 infection. *J Clin Med*. 2020;9:2-20.
7. Kwee TC, Kwee RM. Chest CT scan in COVID-19: what the radiologist needs to know. <https://doi.org/10.1148/rg.2020200159>.
 8. Al Mamun SM, Jahan R, Islam QT, Nazrin T, Shajalal K. Rationale of using common antifibrotic therapy in post COVID pulmonary fibrosis. *J Medicine*. 2021; 22:46-50.
 9. Seifirad S. Pirfenidone: A novel hypothetical treatment for COVID-19. <https://doi.org/10.1016/j.mehy.2020.110005>.
 10. George PM, Wells AU, Jenkins RG. Pulmonary fibrosis and COVID-19: the potential role for antifibrotic therapy. [https://doi.org/10.1016/S2213-2600\(20\)30225-3](https://doi.org/10.1016/S2213-2600(20)30225-3).
 11. Vitiello A, Pelliccia C, Ferrara F. COVID-19 patients with pulmonary fibrotic tissue: clinical pharmacological rational of antifibrotic therapy. *SN Comprehensive Clinical Medicine*. 2020;2:1709-12.
 12. Clinical management of COVID-19: Living guidance. WHO/2019-nCoV/clinical/2021.1.
 13. Qin H, Zhao A. Mesenchymal stem cell therapy for acute respiratory distress syndrome: from basic to clinics. *Protein Cell*. 2020;11:707-22.
 14. Li Z, Niu S, Guo B, et al. Stem cell therapy for COVID-19, ARDS and pulmonary fibrosis. *Cell Proliferation*. 2020;53:e12939.
 15. Can A, Coskun H. The rationale of using mesenchymal stem cells in patients with COVID-19-related acute respiratory distress syndrome: What to expect. *Stem Cells Transl Med*. 2020;1–16.
 16. Esquivel D, Mishra R, Soni P, et al. Stem cells therapy as a possible therapeutic option in treating COVID-19 patients. *Stem Cell Rev and Rep*. 2020;17:144-52.
 17. Li C, Zhao H, Wang B. Challenges for Mesenchymal Stem Cell-Based Therapy for COVID-19. *Drug Design, Development and Therapy*. 2020;14:3995–4001.
 18. Shetty R, Murugeswari P, Chakrabarty K, et al. Stem cell therapy in coronavirus disease 2019: current evidence and future potential. *Cytotherapy*. <https://doi.org/10.1016/j.jcyt.2020.11.001>.
 19. Eiro N, Cabrera JR, Fraile M, Costa L, Vizoso FJ. The Coronavirus pandemic (SARS-CoV-2): New problems demand new solutions, the alternative of mesenchymal (stem) stromal cells. *Front Cell Dev Biol*. Doi: 10.3389/fcell. 2020.00645.
 20. Greenhalgh T, Knight M, A'Court C, Buxton M, Husain L. Management of post-acute COVID-19 in primary care. *BMJ*. 2020;370:3026. <http://dxdoi.org/10.1136/bmj.m3026>.