

## Thyroid Abscess as a Clinical Manifestation of Papillary Thyroid Carcinoma

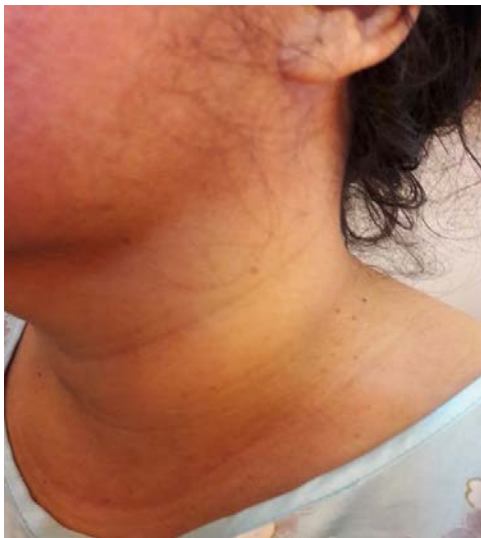**Tri Juli Edi Tarigan<sup>1\*</sup>, Marina Epriliawati<sup>2</sup>**

<sup>1</sup>Division of Endocrinology and Metabolism, Department of Internal Medicine, Faculty of Medicine Universitas Indonesia – Cipto Mangunkusumo Hospital, Jakarta, Indonesia.

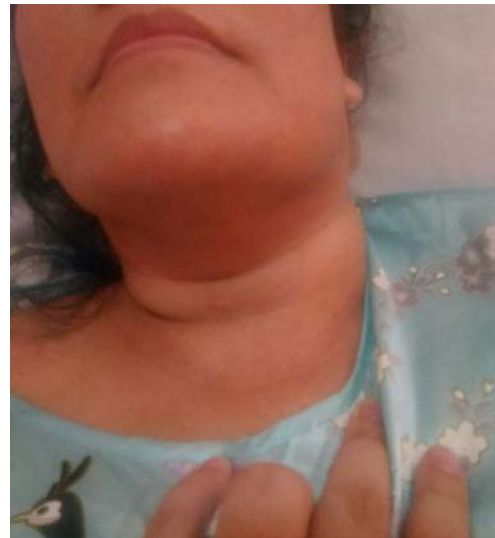<sup>2</sup>Division of Endocrinology and Metabolism, Department of Internal Medicine, Fatmawati General Hospital, Jakarta, Indonesia.

**\* Corresponding Author:**

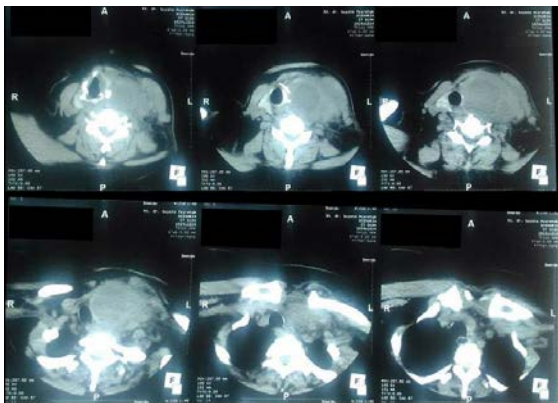
*Tri Juli Edi Tarigan, MD., PhD. Division of Endocrinology and Metabolism, Department of Internal Medicine, Faculty of Medicine Universitas Indonesia - Dr. Cipto Mangunkusumo Hospital. Jl. Diponegoro no. 71, Jakarta 10430, Indonesia. Email: tri.judi@ui.ac.id.*



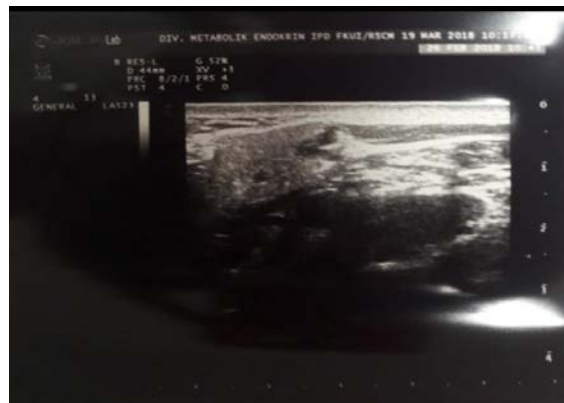**Figure 1.** Lateral view of the neck in a patient with a thyroid abscess at the left lower pole



**Figure 3.** Anterior view of the neck in a patient with a thyroid abscess at the left lower pole



**Figure 2.** Computed tomography imaging of the neck



**Figure 4.** Neck ultrasound

Thyroid abscess is a relatively uncommon condition. It accounts for less than 1% of all thyroid diseases and less than 0.7% of surgical pathology in the thyroid gland. The thyroid gland has protective factors, including high iodine content that acts as a bacterial effect, well-developed capsule, adequate lymphatic drainage, a plentiful blood supply, and hydrogen peroxide production within the gland, which inhibits infection development in the thyroid tissue. Predisposing factors that may increase the susceptibility of the thyroid gland to infection include pyriformis sinus fistulae, thyroid nodule or cancer, or immunocompromised patients. Around 5-10% of the population is estimated to have a palpable nodule, but with ultrasound, it could increase to 50-60% and approximately 5% of the detected nodules are malignant. Therefore, a thorough examination of the thyroid nodule is essential in order to rule out thyroid cancer. Usually, thyroid cancer is present with a mass. However, it is rare for thyroid cancer to present with a thyroid cyst or thyroid abscess, even with infection symptoms.

Numerous reports indicate that females with a pre-existing thyroid nodule had a higher incidence of thyroid abscesses. Although thyroid abscesses are uncommon, they can result in significant morbidity and mortality. Therefore, once a thyroid abscess is diagnosed, aggressive management should be initiated to avoid dangerous complications. The majority of thyroid abscesses are successfully treated with a combination of antibiotics and surgery. Percutaneous drainage and intracavitary antibiotic injection are conservative and is a less invasive alternative management strategy.

A 50-year-old woman presented with a 7-day history of an enlarged, painful, and warm neck mass resulting in swallowing difficulty, as well as a high fever and headache. She had no history of upper respiratory tract infection or neck trauma but had previously been diagnosed with a thyroid nodule a year prior without being treated.

She was found critically ill with a temperature of 38°C and a heart rate of 100 beats per minute. Other vital signs were within normal limits. Her left anterolateral neck was swollen (10x10x5cm), warm and tender, and was reddish. Due to neck

tenderness, cervical lymphadenopathy was difficult to assess. The white blood cell count was 16,800/uL with an elevated neutrophil count (78%), ESR of 120 mm/h (0-20), procalcitonin of 0.09 ng/mL (<0.05), and quantitative CRP of 86.0 mg/L (<5.0). TSHs were within the normal range (0.580 uIU/mL, reference 0.270-4.200), free T4 was 1.390 ng/dL (reference 0.930-1.700), random blood glucose was 161 mg/dL (<140), electrolytes were normal, and both anti-HIV and HbsAg were non-reactive.

Chest X-ray revealed a soft tissue mass in the left inferior neck, displacing the trachea to the right between the C6 and T1 levels. A computed tomography scan of the neck revealed a 7.2x5.4x7.1cm cystic lesion in the left lobe with a thick wall, dislodging the glottis and trachea to the right and extending inferiorly to the supraclavicular, consistent with a left thyroid abscess. The patient was diagnosed with thyroid abscess and treated with ceftriaxone at a dose of 2 grams per day and metronidazole for 500 mg three times daily.

Neck sonography revealed a cystic lesion in the left lobe, surrounded by a thick wall and contain a ruptured lateral capsule.

Ultrasound-guided aspiration of this lesion was performed for diagnostic purposes and to alleviate pain; 100 cc of thick yellow-brown liquid was aspirated from the lesion. Following aspiration, the cavity was twice injected with 50 cc of metronidazole. The patient was scheduled for left isthmolobectomy due to pus expanding into the tissue from a ruptured capsule. Histopathological examination revealed that the specimen was composed primarily of thyroid tissue that had partially formed a cyst cavity. Granulation tissue lined with necrotic tissue and inflammatory cells formed the cyst wall. The pericystical area contained thyroid tissue with epithelium-lined follicles with round nuclei, clear chromatin, and nuclear groove. This finding confirmed the presence of a thyroid abscess associated with a follicular variant of papillary thyroid carcinoma with no extrathyroidal extension.

All symptoms were relieved following surgery on the eighth day of admission, including the neck tenderness that was the patient's chief

complaint. The WBC count was reduced to 7,950/uL in the laboratory, and no bacteria were detected in blood culture or fluid specimens. She was then discharged and prescribed ampicillin sulbactam 375 mg twice daily for three days.

Thyroid abscesses are uncommon, even in patients with compromised host defenses.<sup>1-3</sup> It is more common in women aged 20-40 and affects the left lobe more than the right.<sup>3-5</sup> It accounts for less than 1% of all thyroid diseases and less than 0.7% of surgical pathology in the thyroid gland.<sup>1-3</sup> It is even more uncommon to see thyroid carcinoma presenting as thyroid abscess.

The patient is a 50-year-old woman who has had an untreated thyroid nodule for a year. The patient was then admitted to the hospital with acute symptoms of an enlarged, painful, and warm mass on the left side of the neck that caused difficulty swallowing and was accompanied by a high fever and headache. At first, we suspected it purely as an infection of thyroid abscess. She had no history or laboratory evidence of respiratory infection or immunodeficiency; however, she had a history of thyroid nodule since a year ago. The patient's initial laboratory test results revealed an elevated WBC count of 16,800/uL, an elevated neutrophil count (78 %), ESR of 120 mm/h, and CRP of 86.0 mg/L, but normal TSH and free T4 levels. It is common to see increased non-specific markers of infection such as leukocyte and ESR with normal thyroid function tests. However, hyperthyroidism or hypothyroidism may be present in some cases of thyroid abscess.<sup>3,4,9</sup>

Ultrasound and computed tomography (CT) scans are highly sensitive for the detection of abscess collection.<sup>9</sup> Ultrasound examinations provide sufficient information about intra- or extra-thyroid abscesses, solid or mixed lesions, and the thyroid gland's echostructure and vascular flow. A CT scan can be used to pinpoint the abscess's location and any adjacent organs or structures.<sup>4</sup> When a pyriform sinus fistula is suspected, barium swallow has a high sensitivity for detecting it. This test, however, should be done after the infection has been resolved.<sup>8</sup> In our case, the CT scan revealed the abscess and its relationship to neighboring structures. It revealed a cystic lesion in the left lobe measuring 7.2x5.4x7.1cm with a thick wall, dislodging the

glottis and trachea to the right and extending inferiorly to the supraclavicular, consistent with a left thyroid abscess. At the same time, neck sonography revealed a cystic lesion in the left lobe that was encased in a thick wall and contained a ruptured lateral capsule.

Although the incidence is rare, thyroid abscesses may lead to significant morbidity and mortality, especially if left untreated. Thyroid storm, airway obstruction due to laryngeal oedema or tracheal compression, tracheal and esophageal perforation, descending necrotizing mediastinitis, internal jugular vein thrombosis, and generalized sepsis are all severe complications of thyroid abscess that can occur at any time.<sup>7,9,11</sup> FNA (fine needle aspiration) is a minimally invasive procedure that can be used to diagnose a thyroid abscess, differentiate benign from malignant thyroid nodules, and obtain culture specimens of the causative organism. Thus, a more targeted antibiotic therapy can be prescribed.<sup>4,10</sup> *Staphylococcus aureus* is the most frequently implicated causative organism in thyroid abscesses. However, other organisms, such as oropharyngeal anaerobes or Gram-negative aerobes, are also involved.<sup>7</sup> *Mycobacterium tuberculosis*, *Candida albicans*, and *Brucellosis*, all of which are mixed flora, have been reported occasionally.<sup>3,4,8,12</sup> As a result, this should be considered when initiating empiric antibiotic therapy in the absence of a culture result.<sup>9</sup>

As no organism grew in the culture of blood and fluid specimens in this patient, antibiotics were given empirically in combination with percutaneous drainage and intracavitary antibiotic injection to resolve the symptoms. However, because the thyroid capsule has ruptured and the abscess has spread to adjacent tissue, the isthmolobectomy procedure is necessary in this case. Surgical intervention and dual antimicrobial therapy were used to resolve the thyroid abscess. Histological examination confirmed thyroid abscess with a follicular variant of papillary thyroid carcinoma without extrathyroidal extension.

The management of a thyroid abscess is appropriate systemic antibiotics and abscess drainage. Aspiration of the abscess may resolve

in cases with small abscesses, although a larger one will need partial or total thyroidectomy.<sup>7,11</sup> Percutaneous image-guided drainage of thyroid abscesses with catheter irrigation and intracavitary antibiotics also have been reported as conservative management. Yeow, et al. recommended needle aspiration drainage for small lesions (<3 cm) and catheter drainage for lesions larger than 3 cm or with the involvement of thyroid or parotid gland. Percutaneous needle drainage was performed twice in each case and antibiotics were injected inside the cavity after pus evacuation and rinsing the lesions with 0.02% chlorhexidine gluconate.<sup>5</sup> In the presence of underlying pathology such as the pyriformis sinus tract, operative management is recommended to achieve definite control and prevent a recurrence.<sup>9</sup>

We presented a rare case of thyroid cancer presenting as thyroid abscess. A year before, the patient was diagnosed with an unevaluated thyroid nodule, which could be a malignant lesion, while benign or malignant nodule is a risk factor of thyroid abscess. The patient was initially planned to be treated conservatively by intravenous and intracavitary antibiotic injections. Ultrasound-guided aspiration was conducted for diagnostic and to relieve pain. However, surgical intervention was needed due to the rupture of the capsule and the expansion of the abscess to the surrounding tissue. The histopathological findings from the surgery confirmed thyroid abscess with a follicular variant of papillary thyroid carcinoma. In this case report, this rare finding (cancer presenting as an abscess) explained that physicians must be aware of thyroid abscess in acute tender neck swelling, as it may present as thyroid cancer.

## REFERENCES

1. Yedla N, Pirela D, Manzano A, et al. Thyroid abscess: Challenges in diagnosis and management. *J Invest Med High Impact Case Rep.* 2018;6:1–3.
2. Hoffmann CJ, Brown TT. Thyroid function abnormalities in HIV-infected patients. *Clin Infect Dis.* 2007;45(4):488–94.
3. Akdemir Z, Karaman E, Akdeniz H, et al. Giant thyroid abscess related to postpartum brucella infection. *Case Rep Infect Dis.* 2015;2015:1–3.
4. Ghaemi N, Sayedi J, Bagheri S. Acute suppurative thyroiditis with thyroid abscess: A case report and review of the literature. *Iran J Otorhinolaryngol.* 2014;26(74):51–5.
5. Ilyin A, Zhelonkina N, Severskaya N, Romanko S. Nonsurgical management of thyroid abscess with sonographically guided fine needle aspiration. *J Clin Ultrasound.* 2007;35(1):333–7.
6. Nguyen QT, Lee EJ, Huang MG, et al. Diagnosis and treatment of patients with thyroid cancer. *Res Article Am Health Drugs Ben.* 2015;8(1):30-40.
7. Brown J, Nguyen HH, Cohen SH. A pain in the neck: Thyroid abscess. *Am J Med [Internet].* 2014;127(3):e5.
8. Stavreas NP, Amanatidou CD, Hatzimanolis EG, et al. Thyroid abscess due to a mixed anaerobic infection with *Fusobacterium mortiferum*. *J Clin Microbiol.* 2005;43(12):6202–4.
9. Cawich SO, Hassranah D, Naraynsingh V. Idiopathic thyroid abscess. *Int J Surg Case Rep [Internet].* 2014;5(8):484–6. Available from: <http://dx.doi.org/10.1016/j.ijscr.2014.05.019>
10. Lu Y, Zhang J, Liang X, Hu M, Zheng R, Li L. Efficacy of fine-needle aspiration cytology for a thyroid abscess in children: Two case reports. *Exp Ther Med.* 2015;9(3):860–2.
11. Kale SU, Kumar A, David VC. Thyroid abscess - An acute emergency. *Eur Arch Oto-Rhino-Laryngology.* 2004;261(8):456–8.
12. Raza T, Nm K. Gi microbiome in thyroid abscess. 2017;2(1):2017.