

Adult Necrotising Enterocolitis: a Rare Entity

Mahesh Gupta¹, Subhash Goyal¹, Milan Verma¹, Rekha Goyal²

¹ Department of Surgery, M.M. Institute of Medical Sciences and Research, Mullana, (Distt - Ambala), Haryana, India.

² Department of Radiodiagnosis, M.M. Institute of Medical Sciences and Research, Mullana, (Distt - Ambala), Haryana, India.

Correspondence mail:

Dr Mahesh Gupta. Dept of Surgery M.M. Institute of Medical Sciences And Research, Mullana, (Distt -AMBALA) Pin Code – 133203, Haryana, India. email: gm982003@yahoo.co.in.

ABSTRAK

Dilaporkan sebuah kasus Enterokolitis Nekrotikans pada Orang Dewasa yang dialami oleh seorang wanita dewasa, yang sebelumnya didiagnosis menderita obstruksi usus. Pada laparotomi eksploratif, penyebab mekanik tidak ditemukan meskipun sebagian besar usus halus, sekum dan kolon ascendens proksimal sudah mengalami gangren yang diselingi oleh beberapa bagian normal. Reseksi usus yang terkena gangren tersebut dilakukan dan diikuti oleh yeyunostomi dan kolostomi transversal. Sayangnya, pasien tidak mampu bertahan hidup pasca pembedahan.

Enterokolitis Nekrotikans pada Orang Dewasa dapat menyerupai obstruksi usus, baik secara klinis maupun radiologis dan intervensi medis dan intervensi bedah diindikasikan segera pada kasus-kasus yang mencurigakan walaupun prognosisnya ternyata buruk.

Kata kunci: *Enterokolitis nekrotikans pada orang dewasa, iskemia mesenterika non-oklusif, usus yang mengalami gangren.*

ABSTRACT

A case of Adult Necrotising Enterocolitis in an adult female whom diagnosed with intestinal obstruction was reported. On exploratory laparotomy, the mechanical caused was not found although major part of small bowel, caecum and proximal ascending colon were gangrenous along with intervening normal parts. Resection of affected bowel was performed followed by jejunostomy and transverse colostomy. Unfortunately, the patient not survive in the postoperative periods.

Adult Necrotising Enterocolitis may mimic intestinal obstruction clinically or radiologically and prompt medical and surgical intervention is indicated in doubtful cases although it carries a poor prognosis.

Key words: *adult necrotizing Enterocolitis, non-occlusive mesenteric ischemia, gangrenous bowel.*

INTRODUCTION

Adult necrotizing enterocolitis (ANEC) and non occlusive mesenteric ischemia (NOMI) are rare causes of acute abdomen.^{1,2} Necrotising enterocolitis usually affects children and only few cases have been described in adults. Accurate

preoperative diagnosis is often difficult in these cases. It is characterized by diffuse ulceration and necrosis of the distal small bowel and the colon. The surgical options in advanced cases in both these diseases are minimal and the prognosis is poor. We report one such case of necrotising

enterocolitis in an adult female with a fatal outcome after surgery.

CASE ILLUSTRATION

A 45-year-old female, presented with acute abdominal pain, vomiting and abdominal distension of one day duration and clinical features suggestive of intestinal obstruction and hypovolemic shock. Four days prior to her current presentation she passed dark loose stools. Her past medical history was significant for paraumbilical hernioplasty two years ago. At the time of admission, pulse was 130 beats/min, blood pressure was 86/50 mmHg, and respiratory rate was 36/min with cold extremities. Total leucocyte count was 39,0000/cu mm and creatinine 2.39 mg%. A plain erect abdominal radiograph revealed multiple air-fluid levels, thereby suggesting strangulation following obstruction of the intestines most likely due to adhesions from her previous surgery. She was taken to operation theatre for surgical treatment of her intestinal obstruction. During exploratory laparotomy, foul smelling dark coloured fluid was found along with gangrene of large part of small intestine, cecum and the proximal part of the ascending colon with intervening normal gut. (**Figure 1**). There was no evidence of adhesions or any other evidence of mechanical obstruction. A right hemicolectomy with resection of major part of small bowel was performed leaving approximately one feet of proximal jejunum (**Figure 2**). The jejunum was brought out as jejunostomy and the proximal end of the transverse colon was brought out as colostomy

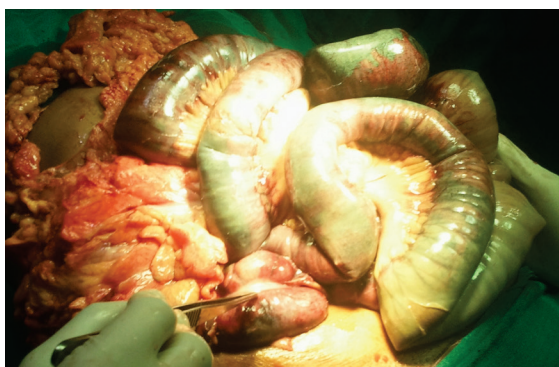

Figure 1. Intraoperative picture showing gangrene of major part of small bowel and caecum.

through the same opening. Unfortunately patient could not survive in the postoperative period. Histopathological examination revealed a non-specific picture of infarction necrosis of the bowel wall.

DISCUSSION

The exact cause of ANEC is not known. Various theories include infection with certain bacteria and viruses, inflammatory mediators, circulatory disturbances leading to hypoxic injury with release of oxygen free radicals and loss of the bowel's cellular integrity. This mechanism is similar to bowel necrosis occurring in non occlusive mesenteric ischemia (NOMI).³⁻⁵ Mesenteric vasoconstriction leads to gut hypoperfusion and intestinal necrosis, with bacterial translocation as the secondary event. However the primary etiology of ANEC seems to be different from neonatal necrotizing enterocolitis (NNEC). In children due to poor development of defence systems, an initial infective insult seems to be the cause of intestinal necrosis than the primary vascular cause as seen in ANEC or NOMI.⁶ Radiological and laboratory data are seldom helpful in diagnosing this entity. Findings on X-ray of these patients may show dilated bowel loops with multiple air-fluid levels are non specific. The common findings in ANEC at laparotomy include dilated and thickened loops of bowel with segments of necrosis often separated by segments of normal bowel (skip lesions) which are usually absent in NOMI.^{7,8} Histological examination is

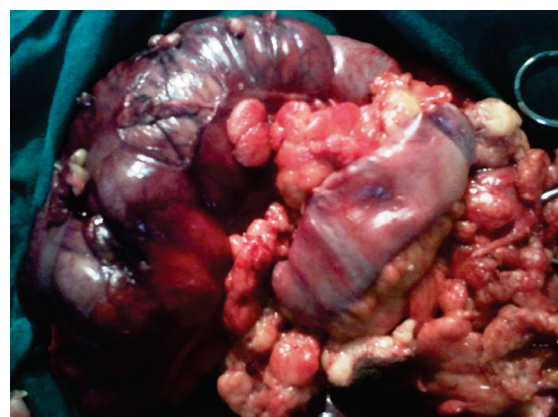


Figure 2. Specimen of right hemicolectomy showing gangrenous caecum and proximal ascending colon

characterized by pathological features such as an intestinal necrosis beginning in the mucosa, without obstruction of the mesenteric vessels. Management is both medical and surgical. Medical management attempts at producing local vasodilatation whenever possible and surgical resection of the affected intestinal segment. In many cases the diagnosis is made during exploratory laparotomy. However, in advanced cases surgical options are limited.⁹ Late complications include short bowel syndrome and malnutrition in case patients survive after surgical resection.

CONCLUSION

There is strong correlation between the vascular and infective events occurring in the mechanism of massive bowel necrosis in ANEC. The clinical and radiological findings, laboratory investigations, histopathology features might be non-specific in advanced disease. A high index of suspicion is necessary in making a diagnosis although it carries a very poor prognosis.

REFERENCES

1. Howard TJ, Plaskon LA, Wiebke EA, et al. Non-occlusive mesenteric ischemia remains a diagnostic dilemma. *Am J Surg.* 1996;171:405-8.
2. Lahmiti S, Aboussad A. Neonatal necrotizing enterocolitis. *Scientific World J.* 2011;22(11):655-6.
3. Schnabl KL, Van Aerde JE, Thomson AB, Clandinin MT. Necrotizing enterocolitis: A multifactorial disease with no cure. *World J Gastroenterol.* 2008;14:2142-61.
4. Reinus JF, Brandt LJ, Boley SJ. Ischemic diseases of the bowel. *Gastroenterol Clin North Am.* 1990;19:319-43.
5. Acosta S, Ogren M, Sternby NH, Berqvist D, Björck M. Fatal nonocclusive mesenteric ischemia: Population-based incidence and risk factors. *J Intern Med.* 2006;259:305-13.
6. Walsh MC, Kleigman RM. Necrotizing enterocolitis: Treatment based on staging criteria. *Pediatr Clin North Am.* 1986;33:179-201.
7. Smerud M, Johnson CD, Stephens DH. Diagnosis of bowel infarction: A comparison of plain films and CT scans in 23 cases. *AJR Am J Roentgenol.* 1990;154:99-103.
8. Bakal CW, Sprayregen S, Wolf EL. Radiology in intestinal ischaemia. Angiographic diagnosis and management. *Surg Clin North Am.* 1992;72:125-41.
9. Boley SJ, Sprayregen S, Siegelman SS, Veith FJ. Initial results from an aggressive roentgenological and surgical approach to acute mesenteric ischaemia. *Surgery.* 1977;82:848-55.