

# Acute Appendicitis in a Patient with Systemic Lupus Erythematosus

*Hendra Gunawan, Awalia, Joewono Soeroso*

Department of Internal Medicine, Faculty of Medicine, Airlangga University - dr. Soetomo Hospital, Surabaya, Indonesia.

**Corresponding Author:**

*Prof. Joewono Soeroso, MD., PhD. Department of Internal Medicine, Faculty of Medicine, Airlangga University - dr. Soetomo Hospital. Jl. Mayjen Prof. Dr. Moestopo 4-6, Surabaya 60132, Indonesia. email: joewono.soeroso4@gmail.com..*

## ABSTRAK

*Lupus eritematosus sistemik (LES) adalah suatu penyakit autoimun kronis eksaserbatif dengan manifestasi klinis yang sangat beragam. Manifestasi gastrointestinal merupakan manifestasi yang sering dijumpai namun dapat terjadi efek masking oleh karena penggunaan obat-obatan untuk mengontrol penyakitnya seperti obat anti-inflamasi non-steroid (OAINS) dan kortikosteroid. Appendisitis akut merupakan salah satu penyebab nyeri abdomen pada penderita LES. Patofisiologi appendisitis akut dapat terjadi primer oleh aktivitas penyakitnya maupun sekunder oleh sebab lain. Membedakan etiologi appendisitis akut perlu dilakukan untuk memberikan tatalaksana yang komprehensif pada penderita dengan LES.*

**Kata kunci:** *lupus eritematosus sistemik (LES), appendisitis akut, nyeri abdomen.*

## ABSTRACT

*Systemic lupus erythematosus (SLE) is a chronic exacerbative autoimmune disease with wide clinical spectrum. Gastrointestinal manifestation is a frequent clinical manifestation seen in SLE. Management with glucocorticoid and non-steroid anti-inflammatory drugs (NSAID) can mask the gastrointestinal symptoms in patient with SLE. One of the etiologies of gastrointestinal manifestations in SLE is acute appendicitis. Patients with acute appendicitis usually have abdominal pain as its chief complaint. The pathophysiology of acute appendicitis can occur primarily from SLE and secondary from other causes eg: infection, inflammation, etc. When a SLE patient has acute appendicitis as its initial assessment, determining its etiology is pivotal to give comprehensive management and preventing life-threatening complications.*

**Keywords:** *systemic lupus erythematosus (SLE), acute appendicitis, abdominal pain.*

## INTRODUCTION

Systemic Lupus Erythematosus (SLE) is a chronic exacerbative autoimmune disease, with a wide clinical spectrum as its clinical manifestations.<sup>1</sup> Gastrointestinal manifestations is a frequent clinical manifestation in SLE patient though not as common as lupus nephritis. William Osler stated that gastrointestinal manifestations in SLE patient can mimic a lot of

abdominal abnormalities. The clinical spectrum is very wide, ranging from simple abdominal pain, nausea vomiting to acute abdomen. The prevalence of abdominal pain, nausea, and vomiting is 50%, whereas acute abdomen can be seen in 8-40% patient with active SLE.<sup>2,3</sup>

Acute abdomen is a serious clinical condition that needs surgical intervention. Its presentation can manifest as acute or insidious abdominal pain

due to masking effect of using non-steroid anti-inflammatory drugs (NSAID) and glucocorticoid as a medication for symptom relief or underlying disease. Gastrointestinal vasculitis can lead to life threatening ischemia, perforation, and infarction.<sup>2-4</sup> Surgical intervention should be considered when there is possibility of bowel perforation. The prevalence of acute appendicitis in SLE patient with abdominal pain is 4.2%.<sup>5</sup> The initial presentation of SLE patient with acute appendicitis can be abdominal pain, nausea, and vomiting, therefore it is very similar with gastrointestinal vasculitis. The etiology of acute appendicitis can be classified into primary from SLE and secondary from other causes.<sup>6</sup> We reported a case of secondary acute appendicitis in patient with SLE.

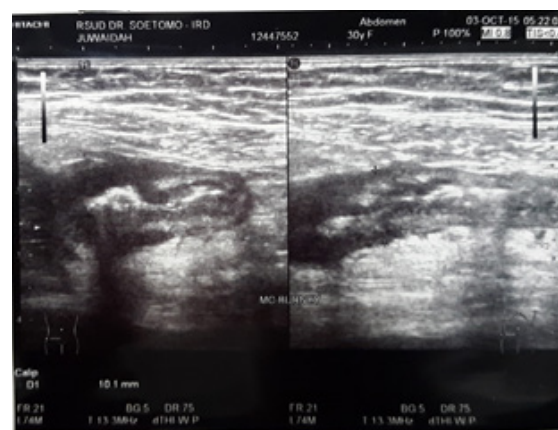
### CASE ILLUSTRATION

A 30-year old woman was brought into the emergency department due to abdominal pain in right lower quadrant. The pain occurred since 14 days before admission. It was sudden, continuous, getting steadily worse, and referred into stomach. She also complained of nausea, vomiting. There was shortness of breath since 2 days before admission that limited her household activities. She had had a history of lupus nephritis since 15 years ago, routinely visited rheumatology outpatient clinic. Her last medication was methylprednisolone 4 mg TID, omeprazole 20 mg BID, and calcium tablets.

On physical examination, her general appearance was weak, blood pressure 90/70 mmHg, respiratory was 24 times per minute, VAS 5, and body temperature was 38.5°C. There were anemia and alopecia. Rhonchi were found in both sides of lung. Abdomen was slightly distended, the point of pain was at McBurney site. There were Rovsing sign, psoas sign, and rebound tenderness, without defence musculaire, darm contour, nor darm steifung. Blood test showed hemoglobin levels 9.2 g/dL, leukocytes 7,030 cells/mm<sup>3</sup>, neutrophil 88.2%, albumin 2.72 g/dL, random plasma glucose 89 mg/dL, BUN 14 mg/dL, creatinine serum 0.75 mg/dL, CRP 82.93 mg/dL, aPTT 36.3 seconds (control 26.2 seconds), PPT 11.8 seconds (control 10.8 seconds), HbsAg rapid test (-), ESR 18, C3 59.5

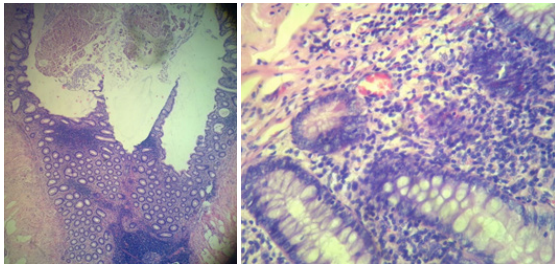
mg/dL, C4 39.1 mg/dL, potassium 3.2 mmol/L.

Chest X-ray showed paracardial infiltrate. Abdominal USG revealed edematous appendix with diameter of 10.1 mm. donut sign, and probe tenderness at McBurney site (**Figure 1**) without the presence of extraluminal fluid. Her initial assessment was SLE, acute appendicitis, s. CAP, sepsis, and hypokalemia. She was consulted to surgery department but refused to have surgical intervention. She was given intravenous methylprednisolone 1 mg/kgBW, ceftriaxone 1 gram intravenous BID and metronidazole 500 mg TID as empirical antibiotics for sepsis, oral KSR for hypokalemia, and nebulization. Proper education was given to patient and her family about the risk and benefit of surgical appendectomy.



**Figure 1.** The USG examination of the patient showed donut sign and outer to outer diameter  $\pm$ 10.1 mm

Abdominal pain became steadily worse until the 6th day of admission, her VAS was 7. She finally agreed to have appendectomy. The surgery succeeded with perioperative intravenous methylprednisolone was given before surgical procedure. The pathology examination of appendix revealed intact mucosa, the presence of faeces without fecalith. Microscopic examination revealed infiltration of neutrophils, lymphocytes, and plasma cells in lamina propria of the appendix without vasculitis in the appendix nor periappendicular tissue (**Figure 2**). Her abdominal pain was relieved after appendectomy and she was discharged 3 days post surgery.



**Figure 2.** The Microscopic examination of Appendix of the Patient.

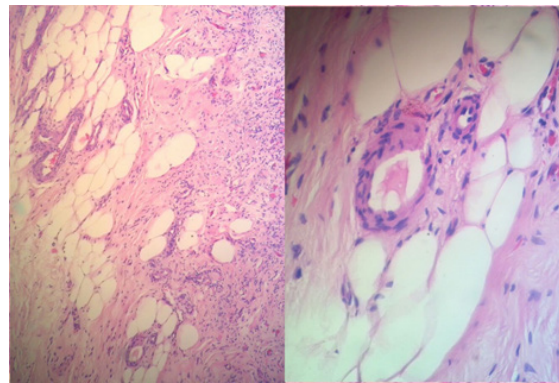
## DISCUSSION

Acute appendicitis' prevalence is 4,2% among patients with SLE that presents with abdominal pain.<sup>7</sup> The diagnosis of our case was made based on history taking, physical diagnostic, and radiographic evaluation. The history taking which revealed abdominal pain in lower right quadrant with nausea, vomiting, and shortness of breath. Pain at McBurney site along with rovsing sign, psoas sign, and rebound tenderness were found in physical examination. Ultrasonography examination revealed a donut sign, with diameter of appendix approximately 10,1 mm, and tenderness with probe at McBurney site.<sup>4,8,9</sup>

Acute appendicitis in patients with SLE has 2 distinctive mechanisms. The first mechanism is from the underlying disease. Acute appendicitis in patient with SLE can be the complication of gastrointestinal vasculitis. Cellini reported that gastrointestinal vasculitis in periappendicular tissue caused ischemia. Ischemia of appendix enhances bacterial proliferation. The underlying mechanism in secondary acute appendicitis is obstruction of the appendix lumen. Obstruction of appendix lumen will increase intraluminal pressure and trigger ischemia of the appendix. Careful history taking and physical diagnosis should be carried out in order to determine the etiology of acute appendicitis.<sup>2,3,10</sup>

Patients with acute appendicitis due to lupus vasculitis will present with gastrointestinal manifestations such as abdominal pain, bloating, nausea, vomiting, along with manifestations in other organs such as musculoskeletal, lupus nephritis, or hematology. Abdominal muscle guarding, rebound tenderness, pain at McBurney

site, rovsing sign, and psoas sign are the most prominent finding in physical examination. Laboratory findings of patient with acute appendicitis due to vasculitis revealed the SLE in active state such as decreased C3 and C4, elevated ESR or the presence of serology marker. Pathology examination will reveal the appearance of small vessel vasculitis and large vessel vasculitis in periappendicular tissue without intramural inflammation of the appendix tissue. Cellini stated that small vessel vasculitis was evident by transmural infiltration of lymphocytes. Large vessel vasculitis was characterized by the presence of neutrophil infiltration and endothelialitis. Secondary acute appendicitis was characterized by the presence of suppurative appendicitis, appendicitis gangrenosum, and periappendicitis. Suppuratis appendicitis was evident by the infiltration of neutrophil on lamina propria of the appendix.<sup>4,10</sup> There were no signs of vasculitis in periappendicular tissue in our case, therefore we concluded that her acute appendicitis was a secondary process. (**Figure 3**)



**Figure 3.** The periappendicular tissue microscopic view. Left: The periappendicular tissue of the appendicitis showed no vasculitis. Right: detailed view of the periappendicular artery showed no vasculitis.

The management of acute appendicitis are conservative and surgical treatment. Defining the etiology of acute appendicitis is important to give proper treatment in SLE patients with acute appendicitis as its initial presentation. Pulse dose of glucocorticoid along with cyclophosphamide might be given when vasculitis were suspected as the underlying mechanism of acute appendicitis.<sup>11</sup>

Methylprednisolone 1-2 mg/kgBW/day might be given for 24-48 hours since there were numerous reports of successful treatment of gastrointestinal vasculitis with high dose intravenous methylprednisolone. Patient with gastrointestinal vasculitis should respond to steroid therapy within 12-48 hours. Surgical treatment may be necessary if the patient's symptoms do not improve in 48 hours or the signs of perforation, large bowel ischemia, or acute abdomen present.<sup>9</sup> The combination of ceftriaxone and metronidazole can be given when intra abdominal infection is suspected. Ceftriaxone and metronidazole are the preferred combination because of its activity against aerob and anaerob bacteria. Early laparotomy within 48 hours is critical to improve the prognosis in patient with gastrointestinal vasculitis.<sup>2,9,12</sup>

Intravenous methylprednisolone was given to our case with dose 1 mg/kgBW while we evaluated the activity of her SLE by requesting C3, C4, and ESR. Patient and her family refused any surgical intervention initially. There were no improvement in clinical condition after 48 hours with intravenous methylprednisolone. The presence of pain at McBurney site was found until 6th day of hospital care. There was no sign of active disease state nor flare found in this patient, seen by her C3, C4, and ESR level were 59,5 mg/dL, 39,1 mg/dL, and 18 respectively. Surgical intervention was performed in 7th day of hospital care. The pathology examination revealed appendix with intact mucosa, with the presence of faeces without fecalith. Microscopically, infiltration of lymphocytes, plasma cell, and neutrophils were found in appendix without the presence of vasculitis in periappendicular tissue (**Figure 2** and **3**). Thus, we assumed that her acute appendicitis was not related to gastrointestinal vasculitis

## CONCLUSION

A case report of SLE patient with acute appendicitis that was not related with her underlying disease activity. Acute appendicitis clinical manifestations can mimic any other

gastrointestinal manifestations in SLE patient. When patient present with clinical manifestations of acute appendicitis, the possibility of gastrointestinal vasculitis and secondary cause should be considered. Accurate history taking, physical examination, laboratory, and radiographic examination are useful to define the etiology of acute appendicitis in order to give comprehensive management in SLE patient with acute appendicitis.

## REFERENCES

- Merrill JT, Buyon JP, Utset T. A 2014 update on the management of patients with systemic lupus erythematosus. *Seminars in Arthritis and Rheumatism*. 2014;44(2):e1-e2.
- Tian X-P, Zhang X. Gastrointestinal involvement in systemic lupus erythematosus: Insight into pathogenesis, diagnosis and treatment. *World J Gastroenterol*. 2010;16(24):2971-7.
- Daruwala C, Mercogliano G, Harder TP. Gastrointestinal manifestations of systemic lupus erythematosus and scleroderma. *Clin Med: Gastroenterol*. 2009;2:7-12.
- Cellini C, Hoda SA, Spigland N. Lupus-associated vasculitis manifesting as acute appendicitis in a 16 year old girl. *Pediatric Rheumatol*. 2008;6(10):1-3.
- Al-Hakeem MS, McMillen MA. Evaluation of abdominal pain in systemic lupus erythematosus. *American J Surg*. 1998;176(1):291-4.
- Yuan S, Lian F, Chen D, et al. Clinical features and associated factors of abdominal pain in systemic lupus erythematosus. *J Rheumatol*. 2013;40(12):2015-22.
- Sultan SM, Ioannou Y, Isenberg D. A review of gastrointestinal manifestations of systemic lupus erythematosus. *Rheumatol*. 1999;38(2):917-32.
- Parks NA, Schroepel TJ. Update on imaging for acute appendicitis. *Surg Clin North Am*. 2011;91(1):141-54.
- Anoosh. F, Shariff R, Ambujakshan D, et al. Acute abdomen as initial presentation in a patient with systemic lupus erythematosus. *Am J Case Rep*. 2009;10(3):55-8.
- Carr NJ. The pathology of acute appendicitis. *Annals Diag Pathol*. 2000;4(1):46-58.
- Indonesia Rheumatology Association. Diagnosis dan pengelolaan lupus eritematosus sistemik. 1st edition. Jakarta: Indonesia Rheumatology Assoc; 2011. p. 17.
- Solomkin JS, Mazuski JE, Rodvold KA, et al. Diagnosis and management of complicated intra-abdominal infection in adults and children: Guidelines by the surgical infection society and the infectious diseases society of America. *Clin Infect Dis*. 2008;50(4):133-64.