

# Prevalence of Hematotoxic Effect of Intravenous Chemotherapy among Retinoblastoma Population in Tertiary Hospital in Bandung, Indonesia

Jennifer Hadiman,<sup>1</sup> Susi Susanah,<sup>2</sup> Adhi Kristianto Sugianli<sup>3</sup>

<sup>1</sup>Faculty of Medicine Universitas Padjadjaran

<sup>2</sup>Division of Microbiology, Department of Biomedical Science, Faculty of Medicine Universitas Padjadjaran

<sup>3</sup>Division of Ankle and Foot, Department of Orthopaedics and Traumatology, Faculty of Medicine, Universitas Padjadjaran-Dr. Hasan Sadikin Hospital, Bandung

## Abstract

**Objective:** To observe the prevalence of hematotoxic effect in retinoblastoma patients who were given intravenous chemotherapy with vincristine, etoposide, and carboplatin (VEC) regimen. Retinoblastoma is the second most common cancer in children in Indonesia. Standard chemotherapy agents used in retinoblastoma treatment is VEC given in 7 cycles intravenously. The most common side effect of VEC regimen is hematotoxic effect which might lead to chemotherapy failure.

**Methods:** This study used descriptive method with cross sectional study design. Data were collected from medical records of retinoblastoma patients in Dr. Hasan Sadikin General Hospital Bandung, Indonesia, from 2014 until 2016 using total sampling technique.

**Results:** Forty-six patients were included in this study. Of those subjects, 36 (78.3%) patients experienced hematotoxic effect. The most common hematotoxic effect occurred were anemia and neutropenia, that occurred in 32 (69.6%) and 18 (39.1%) patients, respectively. The most common hematotoxic effect severity occurred were grade 1 anemia, grade 1 leukopenia, grade 1 neutropenia, and grade 3 thrombocytopenia. Percentage of patients experienced anemia tended to increase until the 7<sup>th</sup> cycle. Seven (15.2%) patients had anemia prior to chemotherapy administration.

Received:  
December 11, 2018

Revised:  
March 12, 2019

Accepted:  
March 21, 2019

**Conclusions:** The majority (78.3%) of the patients experienced hematotoxic effect on intravenous chemotherapy administration with VEC regimen. Anemia was the most common hematotoxic effect occurred.

**Keywords:** Hematotoxic effect, intravenous chemotherapy, retinoblastoma

pISSN: 2302-1381; eISSN: 2338-4506; <http://doi.org/10.15850/ijhs.v7n1.1520>  
IJHS. 2019;7(1):34-8

## Introduction

Retinoblastoma is a tumor of retina originating from neuronal progenitor cell and is the most common ocular malignancy of childhood.<sup>1</sup> In Indonesia, retinoblastoma is regarded as the second of most common malignancy in children after leukemia.<sup>1</sup> The retinoblastoma treatment required multidisciplinary approach with considering the effectivity and toxicity of

therapy in order to preserve life, eyeball, and vision.<sup>2</sup> There are several treatment choices for retinoblastoma, including chemotherapy, focal therapy, radiotherapy, and enucleation.<sup>3</sup>

Chemotherapy can be given intravenously (systemically), intra-arterially, intravitreally, or subconjunctivally.<sup>4</sup> Standard chemotherapy agent used for retinoblastoma is the combination of vincristine, etoposide, and carboplatin (VEC protocol), that is given intravenously, due to their good intraocular penetration.<sup>4</sup> Systemic chemotherapy might cause several side effects, including hematotoxicity, fever, ototoxicity, nephrotoxicity, and secondary leukemia.<sup>2</sup>

## Correspondence:

Jennifer Hadiman, Faculty of Medicine,  
Universitas Padjadjaran  
Jl. Raya Bandung-Sumedang KM 21 Jatinangor,  
Indonesia  
e-mail: jenniferhadiman@gmail.com

Hematotoxicity is the effect of chemical agent exposure on the hematopoietic system, including blood and its components, and blood-forming organs.<sup>5</sup> Chemotherapy drugs can destroy cancer cells by inhibiting cancer cells ability to grow and divide, however, the damage might also occur on normal cells, including the cells in hematopoietic system, which might cause several hematotoxic effects such as anemia, thrombocytopenia, and neutropenia.<sup>5</sup>

Hematotoxicity occurs due to chemotherapy failure caused by several mechanisms.<sup>6</sup> Anemia could cause delay in initiating chemotherapy, failure to complete the chemotherapy, and resistance to chemotherapy, so that it had impact on quality of life, disease progression, and survival of cancer patients.<sup>7</sup>

Neutropenia could increase the risk of developing infections that could lead to oncology emergencies. Thrombocytopenia is primary cause of bleeding in cancer patients and could cause anemia.<sup>8</sup>

The study relating to hematotoxic effect as the most common chemotherapy side effects was still limited in Indonesia. This study aimed to observe prevalence of hematotoxic effect in retinoblastoma patients received intravenous chemotherapy in Dr. Hasan Sadikin General Hospital, Bandung.

## Methods

This study used descriptive method with cross-sectional study design. Data were collected based on medical records of patients who diagnosed as retinoblastoma in Department of Child Health Dr. Hasan Sadikin General Hospital Bandung, West Java province, Indonesia.

Population of this study was retinoblastoma patients who were given the systemic chemotherapy in Dr. Hasan Sadikin General Hospital, Bandung between January 2014 to December 2016. The inclusion criteria were retinoblastoma patients that were given first cycle of systemic chemotherapy with VEC regimen between 1 January 2014 to 31 December 2016. Data were excluded if there was incomplete medical records data, absence of seventh cycle hematological data and the available hematological data were less than 4 cycles of chemotherapy. In this study, data were collected and observed until the first 7 cycle of chemotherapy, according to the standard regulation chemotherapy with VEC regimen.

**Table 1 Retinoblastoma Patients Characteristics**

Characteristic	Number (n=46)	Percentage (%)
Age (months)		
<13	5	10.9
13-36	25	54.3
37-60	10	21.7
>60	6	13.0
Sex		
Male	28	60.9
Female	18	39.1
Residency		
West Java	33	71.7
Central Java	2	4.3
Special Region of Yogyakarta	1	2.2
South Kalimantan	1	2.2
Lampung	7	15.2
No data	2	4.3
Nutritional Status		
Undernutrition	8	17.4
Normal	34	73.9
Overnutrition	2	4.3
No data	2	4.3
Family History		
No	46	100.0
Yes	0	0.0
First Clinical Presentation		
Leukocoria	25	54.3
Strabismus	0	0.0
Red eye	4	8.7
Proptosis	2	4.3
Periorbital edema	1	2.2
Others	1	2.2
No data	13	28.3
Laterality		
Unilateral	39	84.8
Bilateral	7	15.2

The data were collected and recorded for age, sex, nutritional status, family history,

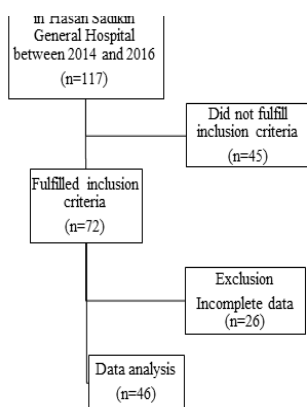
**Prevalence of Hematotoxic Effect of Intravenous Chemotherapy among Retinoblastoma Population in Tertiary Hospital in Bandung, Indonesia**

first clinical manifestation, laterality of retinoblastoma, and hematological data (hemoglobin, leukocyte, absolute neutrophil count, and thrombocyte). Nutritional status was assessed by using World Health Organization (WHO) weight-for-length/height growth chart.<sup>9</sup> All the hematological data were data prior to each chemotherapy cycles. The hematotoxic effects were categorized into anemia, leukopenia, neutropenia, and thrombocytopenia based on WHO toxicity grading scale recommendation.<sup>10</sup> The WHO classification was listed in table as supplement. Data were analyzed using IBM® SPSS® version 24 and presented as tables and graphs with number and percentage. This study was approved by Research Ethics Committee Faculty of Medicine Universitas Padjadjaran (Number 228/UN6.KEP/EC/2018).

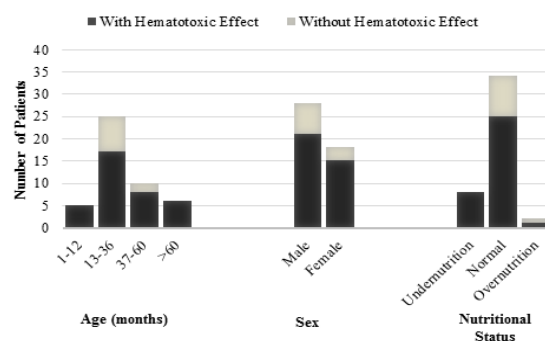
**Results**

There were 117 retinoblastoma patients came to Department of Child Health Dr. Hasan Sadikin General Hospital Bandung between 2014 and 2016. From 117 patients, 72 patients fulfilled inclusion criteria and 26 from 72 patients were excluded from this study (Fig. 1).

Among 46 patients included in this study, 25 (54.3%) patients were between 13–36 months old. Age range in this study was 3–130 months old. The numbers of males were higher than female patients. The majority of the patients (71.7%) were from several cities in West Java province. All patients (100%) did not have family history of retinoblastoma.



**Fig. 1 Flow Chart of Patients who Met Inclusion/Exclusion Criteria of the Study**



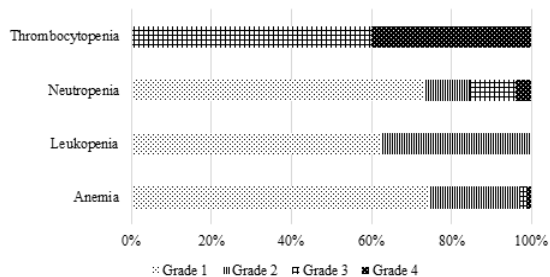
**Fig. 2 Hematotoxic Effect Based on Patients Characteristics**

First clinical presentation in 25 (54.3%) patients was leukocoria. Thirty-nine (84.8%) patients had unilateral retinoblastoma. The characteristics of the patients were described (Table 1).

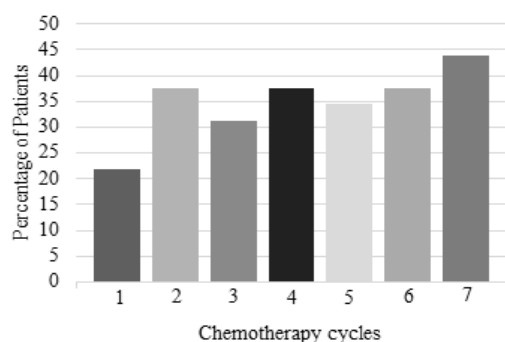
There were 36 (78.3%) patients experienced hematotoxic effect, either anemia, leukopenia, neutropenia, or thrombocytopenia. In addition, the hematotoxic effect was more common in age group 13–36 months, male patients, and normal nutritional status (Fig. 1).

Among 46 subjects, anemia, leukopenia, neutropenia and thrombocytopenia were observed in 32 (69.6%), 8 (17.4%), 18 (39.1%), and 4 (8.7%) patients, respectively. The most common hematotoxic effect severity occurred was grade 1 for anemia, leukopenia, and neutropenia, and grade 3 for thrombocytopenia (Fig. 2).

In this study, anemia commonly occurred as the hematotoxic effect. There were 7 patients already experienced anemia before given the first cycle of chemotherapy. The percentage of patients experienced anemia tended to increase from cycle 1 until cycle 7 (Fig. 3).



**Fig. 3 Hematotoxic Effect Severity Based on WHO Toxicity Grading<sup>9</sup>**



**Fig. 4 Percentage of Patients Experienced Anemia in Each Chemotherapy Cycle**

## Discussion

Retinoblastoma patients in this study were mostly between 13–36 months old. This was similar with the previous study in East Java that retinoblastoma most common occurred in children aged 12–<36 months old.<sup>11</sup> A study in India also found that 54% of retinoblastoma patients were between 1–3 years old.<sup>12</sup>

The most common first clinical presentation was leukocoria. This finding was similar to studies in other countries in Asia Pacific that leukocoria was the most common first clinical manifestation.<sup>12,13</sup> Because of high incidences of leukocoria as the first clinical presentation in retinoblastoma, a child should be suspected retinoblastoma if his/her eye reflects light like a cat's eye, particularly in children less than 3 years old.

In this study, it was found that 36 (78.3%) patients experienced hematotoxic effect and the most common hematotoxic effect was anemia. A study conducted by Qaddoumi *et al.*<sup>14</sup> on retinoblastoma patients given topotecan and vincristine combination chemotherapy discovered that neutropenia occurred in all (100%) patient, while anemia occurred in 70% patients, and thrombocytopenia occurred in 59% patients. In other study by Caubet *et al.*<sup>15</sup> on prostate cancer patients that were given carboplatin and etoposide combination chemotherapy also found that the most common hematotoxic effect was anemia that occurred in 33.3% patients.

The standard chemotherapy regimen for retinoblastoma consisted of 3 chemotherapy agents: vincristine, etoposide, and carboplatin. Hematotoxic effect caused by vincristine was mild and not significant.<sup>16</sup> Hematotoxic effect

caused by etoposide were mainly leukopenia and thrombocytopenia.<sup>16</sup> The main side effect caused by carboplatin was hematotoxic effect, mainly neutropenia and thrombocytopenia.<sup>17</sup> Besides damaging hematopoietic cells in bone marrow, platinum-based chemotherapy agent like carboplatin was also nephrotoxic, so that erythropoietin production in kidney was impaired.<sup>18</sup> This made carboplatin frequently caused anemia.

In this study it was found that percentage of patients experienced anemia tended continue to increase until 7th cycle. In a study on breast, lung, colon/rectal, stomach, and ovarian cancer patients given chemotherapy, it was found that anemia occurrence continued to increase until 5<sup>th</sup> or 6<sup>th</sup> cycle.<sup>19</sup> This was likely due to hematotoxic effect accumulation during chemotherapy administration.<sup>19</sup>

The most common hematotoxic effect severity occurred in this study tended to be mild, that was grade 1 for anemia, leukopenia, and neutropenia, and grade 3 for thrombocytopenia. In another study on retinoblastoma patients that were given intravenous chemotherapy with vincristine, etoposide, and carboplatin regimen in 3 cycles and vincristine, cyclophosphamide, and doxorubicin regimen in 3 cycles, the most common hematotoxic effect occurred were grade 3 anemia, grade 3 leukopenia, grade 4 neutropenia, and grade 3 thrombocytopenia.<sup>20</sup> This difference was likely due to the different chemotherapy regimen given and the small number of subjects in this study.

There were 32 patients experienced anemia in this study and in this study, it was found that 7 (15.2%) patients experienced anemia before given the first cycle of chemotherapy. Therefore, anemia was a challenge in retinoblastoma treatment because besides retinoblastoma itself caused anemia due to chronic disease, the chemotherapy given also caused anemia by depressing bone marrow. Because there were patients who had anemia prior to chemotherapy, it was important to do hematological screening before initiating chemotherapy.

Based on the result of the study, a conclusion can be made that there are 78.3% retinoblastoma patients who received intravenous chemotherapy with VEC regimen experience hematotoxic effect. Anemia is the most common hematotoxic effect that occur in 69.6% patients and 15.2% patients have anemia prior to initiating chemotherapy.

Limitation of this study was this study was done retrospectively from the medical record

of retinoblastoma patients and there were many incomplete or unreadable data. This study was beneficial to physicians, particularly pediatricians, to anticipate hematotoxic effects related to chemotherapy administration, and anemia, as well. The physicians should also anticipate anemia occurrence which

tended to increase as more chemotherapy cycles were given. It is important to do hematological screening before chemotherapy administration, so that the cause of anemia can be investigated and treated prior to chemotherapy.

## References

1. Kementerian Kesehatan Republik Indonesia. Pedoman penemuan dini kanker pada anak: Jakarta: Kementerian Kesehatan Republik Indonesia; 2011.
2. Ghassemi F, Khodabande A. Risk definition and management strategies in retinoblastoma: current perspectives. *Clin Ophthalmol*. 2015;9(3):985–94.
3. Mendoza PR, Grossniklaus HE. Therapeutic Options for Retinoblastoma. *Cancer Control*. 2016;23(2):99–109.
4. Yanik Ö, Gündüz K, Yavuz K, Taçyıldız N, Ünal E. Chemotherapy in retinoblastoma: current approaches. *Turk J Ophthalmol*. 2015;45(6):259–67.
5. Sherley JL. Human stem cell toxicology. Cambridge: The Royal Society of Chemistry; 2016.
6. Papiież MA. The effect of quercetin on oxidative DNA damage and myelosuppression induced by etoposide in bone marrow cells of rats. *Acta Biochimica Polonica*. 2014;61(1):7–11.
7. Busti F, Marchi G, Ugolini S, Castagna A, Gerelli D. Anemia and iron deficiency in cancer patients: role of iron replacement therapy. *Pharmaceuticals*. 2018;11(94):1–14.
8. Brigle K, Pierre A, Oliver EF, Faiman B, Tariman JD, Miceli T, *et al*. Myelosuppression, bone disease, and acute renal failure. *Clin J Oncol Nurs*. 2018;21(5):60–76.
9. World Health Organization. WHO multicentre growth reference study group. Geneva: World Health Organization; 2006.
10. World Health Organization. Guidelines for monitoring and reporting adverse events drug reactions 2013. [cited 2018 Dec 6]. Available from: <https://apps.who.int/medicinedocs/documents/s18571en/s18571en.pdf>.
11. Soebagio HD, Prastyani R, Sujuti H, Lyrawati D, Sumitro SB. Profile of retinoblastoma in East Java, Indonesia. *World J Med Med Sci Res*. 2013;1(3):51–6.
12. Subha L, Reddy AS, Ramyaa. A clinical study of retinoblastoma. *J Pharm Bioallied Sci*. 2015;7(Suppl 1):S2–S3.
13. Choi S, Han JW, Kim H, Kim BS, Kim DJ, Lee SC, *et al*. Combined chemotherapy and intra-arterial chemotherapy of retinoblastoma. *Korean J Pediatr*. 2013;56(6):254–9.
14. Qaddoumi I, Billups CA, Tagen M, Stewart CF, Wu J, Helton K, *et al*. Topotecan and vincristine combination is effective against advanced bilateral intraocular retinoblastoma and has manageable toxicity. *Cancer*. 2012;118(22):5663–70.
15. Caubet M, Dobi E, Pozet A, Almotlak H, Montcuquet P, Maurina T *et al*. Carboplatin-etoposide combination chemotherapy in metastatic castration-resistant prostate cancer: A retrospective study. *Molecular and Clinical Oncology*. 2015;3(6):1208–12.
16. Chu E, DeVita VT. Physicians' Cancer chemotherapy drug manual. Massachusetts: Jones & Bartlett Learning; 2015.
17. Chen X, Wang J, Fu Z, Zhu B, Wang J, Guan S, *et al*. Curcumin activates DNA repair pathway in bone marrow to improve carboplatin-induced myelosuppression. *Sci Reprt*. 2017;7(1):1–11.
18. Doleschel D, Rix A, Arns S, Palmowski K, Gremse F, Markle R, *et al*. Erythropoietin improves the accumulation and therapeutic effects of carboplatin by enhancing tumor vascularization and perfusion. *Theranostics*. 2015;5(8):905–18.
19. Xu H, Xu L, Page JH, Cannavale K, Sattayapiwat O, Rodriguez R, *et al*. Incidence of anemia in patients diagnosed with solid tumors receiving chemotherapy. *Clin Epidemiol*. 2016;8(1):61–71.
20. Sullivan EM, Wilson MW, Billups CA, Wu J, Merchant TE, Brennan RC, *et al*. Pathologic risk-based adjuvant chemotherapy for unilateral retinoblastoma following enucleation. *J Pediatr Hematol Oncol*. 2014;36(6):335–40.