

Case Report

The Mystery of the Disappearing Nasal Packs

Wong Kim Yew Richard¹, Shamim Rahman Bin S.M.A. Abdul Rasheed¹

Abstract

Nasal packing is commonly used for hemostasis post nasal surgeries. It is cheap, easily available and is routinely practiced in many centres. However, they may be associated with complications. Some of the complications include pain during nasal packing removal, damage or injury to the nasal mucosa leading to synechiae formation, crusting, and septal perforation. We describe a case of a 39-year-old gentleman who underwent a septoturboplasty procedure, to address his nasal problem and subsequently nasal packing was inserted into bilateral nasal cavity for hemostasis. However, prior to extubation, it was noted that the nasal packing were not in situ. Nasoendoscopy and direct laryngoscopy were performed but were unable to trace the missing nasal packs. An Oesophagogastroduodenoscopy (OGDS) was done and revealed the presence of the nasal packing in the stomach. This case highlighted the risk of nasal packing to be dislodged from the nasal cavity into the stomach if not secured properly, and therefore we recommended securing the nasal packing in its position by tying a knot using the strings attached with the nasal packing together.

Keywords: Haemostasis, nasal surgery, polyvinyl acetal

International Journal of Human and Health Sciences Vol. 06 No. 04 October'22 Page : 442-444
DOI: <http://dx.doi.org/10.31344/ijhhs.v6i4.485>

Introduction

There are multiple modalities of nasal hemostasis post nasal surgery. One commonly used modality is by inserting nasal packing into the nasal cavity. We present a rare case of nasal packing which was inserted into the nasal cavity for hemostasis, and subsequently dislodged into the stomach. We also review the associated literatures to determine the available methods of nasal hemostasis post nasal surgery, discussing on the benefits and disadvantages of each modality.

Case Report

A 39-year-old Malay gentleman, with underlying bronchial asthma; presented with history of daily rhinorrhea & bilateral nasal blockage which became worse for the past three years. It is associated with sneezing and nasal itchiness, which worsens with seafood intake. Examination of the nose via nasoendoscopy shows narrow

internal nasal valve area bilaterally, hypertrophy of bilateral inferior turbinates, and left septal deviation with right sided septal spur. There were no abnormality detected in the bilateral osteomeatal complexes and nasopharynx. Based on the symptoms and finding, he was diagnosed as Allergic Rhinitis with Deviated Nasal Septum. He was initially treated with Fluticasone intranasal steroid spray, which did not help much with the symptoms. He was then advised to undergo a septoturboplasty procedure in view of persistent nasal symptoms despite being on intranasal corticosteroids. Intra-operative findings confirmed the clinic nasoendoscopic findings of a left sided nasal septal deviation, and bilateral inferior turbinate hypertrophy. The procedure was done in the usual manner and was uneventful with no intra-operative complication. At the end of the surgical procedure, Meroce[®] nasal packs, enveloped with an outer layer of glove; were inserted into bilateral

1. Department of Otorhinolaryngology-Head & Neck Surgery, Kulliyah of Medicine, International Islamic University Malaysia, Kuantan, Pahang, Malaysia.

Correspondence to: Dr. Wong Kim Yew Richard, Resident, Department of Otorhinolaryngology-Head & Neck Surgery, Kulliyah of Medicine, International Islamic University Malaysia, Kuantan, Pahang, Malaysia. E-mail: richardwky@gmail.com

nasal cavity for hemostasis. The strings at the end of the nasal pack were not tied, but placed onto the patient's nasal tip using a surgical tape..

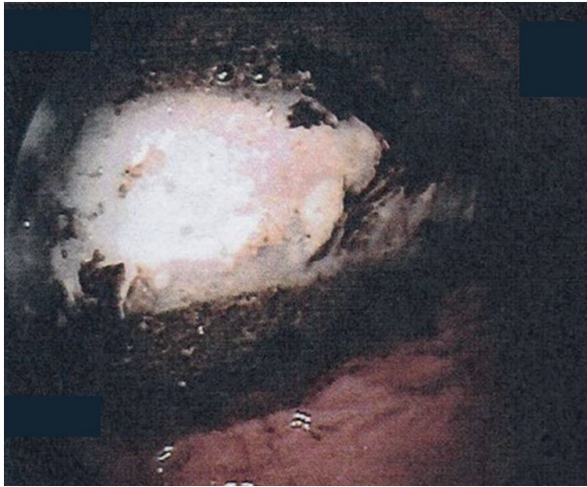


Figure 1: View of the dislodged Merocel® nasal packs in the body of the stomach located using an OGDS.

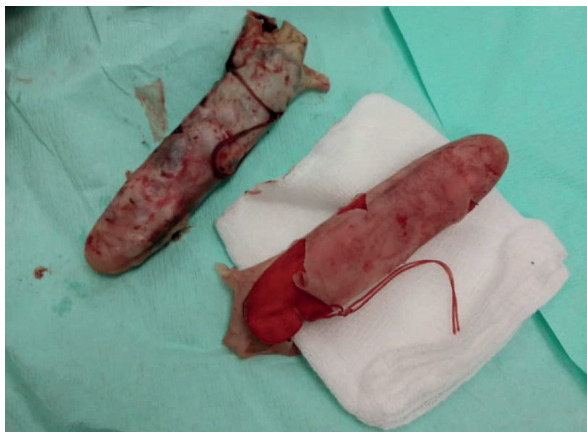

Figure 2: Nasal packs, enveloped with an outer layer using glove, after removal from the stomach.

Discussion

Bleeding is the most frequent complication of endoscopic nasal surgeries. It may occur intra-operatively or post-operatively, increasing the risk of morbidity to the patient.¹ Therefore, various methods of nasal hemostasis have been developed to address the problem of bleeding. This ranges from the usage of formed nasal packs, thrombogenic foams and gels, and usage of cautery devices. Nasal packs are extremely useful tools for hemostasis in endoscopic nasal surgeries. With an increased demand, there is also an increasing number of products on the market made of different materials. The advantages of nasal packs are that

they not only provide hemostasis after surgery, but they also provide support for the cartilaginous and bony nasal structures, or soft tissues which require time to regain their strength via the wound healing process post-operatively. They may also prevent adhesions or stenosis, especially following functional endoscopic sinus surgery. Nasal packs also reduce the risk of the formation of septal hematomas. Nasal packs can be generally divided into two main groups made of different materials, which are the formed nasal packs (e.g. Polyvinyl acetal, carboxymethylcellulose and alginates) and the new generation of hemostatic or resorbable and biodegradable packs (e.g. gelatin, thrombin, and polyurethane foams) Polyvinyl acetal (PVA) nasal packs are expandable type which increases in volume after the contact with blood or water. The classic type of PVA nasal pack is the Merocel®. Merocel® is soft and elastic, as they can absorb up to 20 times their weight in fluid. This property allows them to apply light to moderate pressure in the nasal cavity.² As it is packed in a compressed and dehydrated state, it requires rehydration with saline to activate it. The pores within the Merocel® swells, causes haemostasis, and exerts equal pressure on both sides of the septum, thus keeping the septum straight following the surgery.

Conclusion

To conclude, there are multiple methods of haemostasis which can be used post nasal surgery, which includes the usage of formed nasal packs, thrombogenic foams and gels, and usage of cautery devices. Formed nasal packs, especially those of the polyvinyl acetal type (e.g., Merocel®) is widely used in many centres. We would like to highlight the rare but possible complication of nasal packs being dislodged into the stomach if not anchored properly. Therefore, if polyvinyl acetal nasal packs are used, we recommend that a knot is tied between the strings of the two nasal packs to prevent dislodgement out of the nasal cavity.

Conflict of interest: The authors declare no conflict of interest.

Funding statement: Nil

Author's contribution: WKYR and SRSAR contributed to the concept, design and drafting of the manuscript. SRSAR contributed to obtaining the clinical and radiological images. All authors revised and approved the final manuscript.

References:

1. Pagella F, Pusateri A, Berardi A, Zacchari D, Avato I and Matti E. A novel device for intraoperative cauterization of bleeding points in endoscopic sinus surgery. *European Archives of Oto-Rhino-Laryngology*. 2016;273(8):2257-2260.
2. Weber R. Nasal packing and stenting. *GMS Current Topics in Otorhinolaryngology - Head and Neck Surgery*. 2009;8:1-16.
3. Kaur J, Singh M, Kaur I, Singh A and Goyal S. A comparative study of gloved versus ungloved Merocel® as nasal pack after septoplasty. *Nigerian Journal of Clinical Practice*. 2018;21:1391-5.
4. Garzaro M, Dell'Era V, Rosa MS, Cerasuolo M, Garzaro G, AluffiValletti P. Effects of glove finger-versus lidocaine-soaked nasal packing after endoscopic nasal surgery: a prospective randomized controlled trial. *European Archives of Oto-Rhino-Laryngology*. 2019;277(2):439-43.
5. Eta RA, Eviatar E, Pitaro J, Gavriel H. Post-Turbinectomy Nasal Packing with Merocel versus Glove Finger Merocel: A Prospective, Randomized, Controlled Trial. *Ear, Nose & Throat Journal*. 2018;97(3):64-8.
6. Rohit K, Shivakumar AM, Munish KS, Mohan Kumar C and JeyashanthRiju J. Unusual Foreign Bodies of the Nasal Cavity: A Series of Four Cases. *IOSR Journal of Dental and Medical Sciences*. 2015;14(5):100-104.
7. Eipe N, Choudhrie A. Nasal Pack Causing Upper Airway Obstruction. *Anesthesia & Analgesia*. 2005;100(6):1861.
8. Novoa E, Junge H. Nasal packing: When a routine practice becomes a life-threatening emergency. *Clinical Case Reports*. 2020;8:2638-2640.
9. Badran K, Malik TH, Belloso A and Timms MS. Randomized controlled trial comparing Merocel® and RapidRhino® packing in the management of anterior epistaxis. *Clinical Otolaryngology*. 2005;30(4):333-337.
10. Chevillard C, Rugina M, Bonfils P, Bougara A, Castillo L, Crampette L, et al. Evaluation of calcium alginate nasal packing (Algostérial) versus Polyvinyl acetal (Merocel) for nasal packing after inferior turbinate resection. *Rhinology*. 2006;44(1):58-61.
11. Weitzel EK, Wormald PJ. A Scientific Review of Middle Meatal Packing/stents. *American Journal of Rhinology*. 2008;22(3):302-307.
12. Wang J, Cai C, and Wang S. Merocel versus Nasopore for Nasal Packing: A Meta-Analysis of Randomized Controlled Trials. *PLOS ONE*. 2014;9(4):e93959.
13. Mcleod RWJ, Price A, Williams RJ, Smith ME, Smith M, Owens D. Intranasal cautery for the management of adult epistaxis: systematic review. *The Journal of Laryngology & Otology*. 2017;131(12):1056-64.
14. Weber R, Keerl R, Hochapfel F, Draf W, Toffel PH. Packing in endonasal surgery. *American Journal of Otolaryngology*. 2001;22(5):306-20.