

Histopathological Effect of Zinc Oxide Nanoparticles on Kidney and Liver Tissues in Albino Male Mice

Ruqayah Ali Salman

University of Al-Forat Al-Awsat Techniques

rokayaalibio@gmail.com

Received in:4 /July/2017, Accepted in:17/September/2017

Abstract

Objective: The present study investigated the effects of different dose levels of Zinc oxide Nanoparticles (ZnO NPs) on the liver and kidney tissues in albino male mice. **Methodology:** ZnO NPs was administrated as a daily oral dose of (150, 350 mg/kg body weight) gavage for 2 weeks. Eighteen male mice were used by dividing them into three groups. **Result:** Histopathological examination of kidney and hepatic tissues treated with ZnO NPs showed toxicity changes compared with control group. **Conclusion:** This study demonstrated the ability of ZnO NPs to effect on kidney and liver tissues. **Recommendation:** More study needed to know the effect of different doses of nanoparticles on human health.

Key words: Nanoparticles, Zinc oxide nanoparticles, Albino male mice, kidney and liver.

Introduction

Nanoparticles can enter the human body through the different rolls such as inhalation, ingestion and injection [1]. Then, translocate to blood causing negative feedback in several organs [2]. Some research looking at biological trace element of the human body and are usually found in foods or added as a food supplement. Zinc concentration determines the toxicity [3]. It is the high concentration of zinc that leads to toxic effect [4]. Other research indicated the histopathological changes of kidney tissues mice treated with ZnO NPs such as hydropic degeneration in epithelial cells, necrosis and glomeruli segmentation [5]. The activity of metal oxides nanoparticles such as zinc oxide (ZnO NPs), silicon oxide and selective toxicity of biological systems proposed potential entail application that includes herapeutics, diagnostics surgical devices and nano medicine based on antimicrobial agents [6]. The increasing production and use of metal oxide nanoparticles in many applications lead to negative effects on health [7]. Several studies have demonstrated nanoparticle toxicity and increased cytotoxic potential of these materials [8]. ZnO NPs can enter bodies water not only through dikardligh dyes and paints but also get rid of cosmetics [9,10]. ZnO is one of the few semiconductors quantum confinement effect and it is an environmental friendly oxide, because of its no toxicity (depended on the concentration and dose) and the ability to absorb in the UV range that use absorbent UV sunscreens in transferring power [11]. Aragon G and Younossi ZM. suggest that the toxicity of NPs depended on species, ZnO NPs significant changes the levels of ALT, ALP and AST enzymes. The elevated of these enzymes are indicative of the functional efficiency of the liver. Due to damaged liver cells, these enzymes are released into the blood, therefore, a high amount of these enzymes indicates destruction of liver cells [12].

In the current study, the effect of different dose levels of Zinc oxide Nanoparticles (ZnO NPs) on kidney and liver tissues in Albino male mice was investigated.

Materials and Methods

Zinc oxide nanoparticles have been obtained from Nanjing, China. Structure and size measurement of nanoparticles sample were recognized by the Scanning Electron Microscope SEM (Electronic Microscope Center-College of Applied Science, University of Technology, Iraq). Different concentrations of nanoparticles colloids were prepared from stock solution of 300 µg/ml ZnO NPs in (3:1) distill water and ethanol as a solvent.

Eighteen albino male mice obtained from the animal house of biotechnological center in Al-Nahrain University. The age of mice was 3 weeks and the weight was 20-25 gm. Animals cages were kept in standardized conditions (25 ± 5 °C, 12 hr light/ dark cycle). Allow free taken water and pelleted. In this study, the male albino mice were divided into three groups (each group comprises six mice). First group (control group) received food and water. The second and third groups were oral gavages by 150 mg/kg and 350 mg/kg body weight of ZnO NPs. All animals were sacrificed at the end of experiment.

A small piece of kidney and liver were taken and fixed in 10% formalin solution, after that routine histological preparations was conducted [13].

Results

The current study revealed that ZnO NPs (150 mg/kg body weight) induced changes of kidney and liver tissue after 15 days of exposure. Kidney sections of control group showed normal structure; normal renal cortex and normal nephritic tubules figure (1), liver section

showed normal hepatocytes, central vein and hepatic portal traid figure (2). In the second group that treated with (150 mg/kg body weight/ day ZnO NPs) showed pathological changes which includes: medulla revealed slight enlargement in collecting tubules and normal cortex composed in the kidney figures (3) & (4) and proliferation of kupffer cell in the liver figure (5) compared to the control group figure (1)

The third group that treated with (350 mg/kg body weight/ day) of Zinc oxide nanoparticles showed marked, inflammatory cells particularly mononuclear cells aggregation around blood vessels and between renal tubules in the kidney figure (4), and amyloid like substance deposition in the wall of liver sinusoids and replacement of hepatic cords deposition in the wall of sinusoids Figure (8). The liver also showed inflammatory cells infiltration particularly neutrophils and mononuclear cells appear around congested blood vessels. Figure (9)

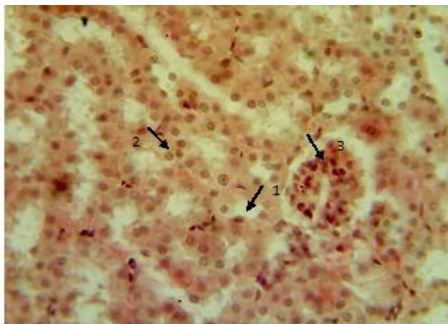


Figure (1): Section in mouse kidney of control groups showed normal kidney structures; medulla, collecting tubules (1), lined by simple cuboidal epithelium (2) with normal renal corpuscles with their glomeruli (3). H &E stain 400X

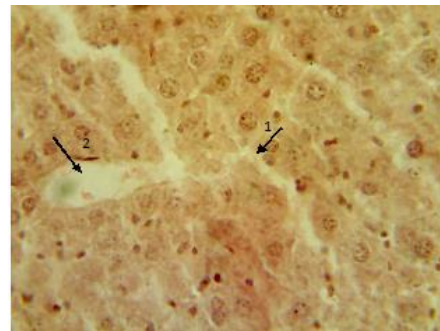


Figure (2): Section in mouse liver of control groups showed normal structures of hepatic cord (1), liver sinusoids (2). H &E stain 400X.

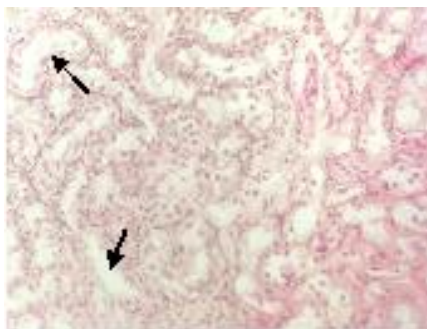


Figure (3): Section in mouse kidney of animal treated with 150 mg/kg body weight/ day of ZnO NPs for 15 days showed reveal slight enlargement in collecting tubules. H &E stain 400X.

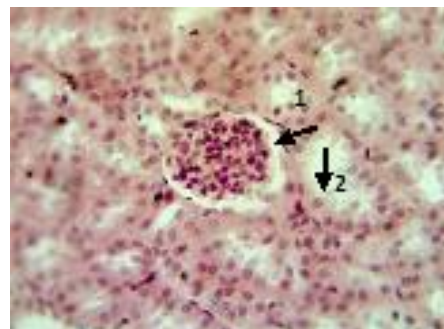


Figure (4): Section in mouse kidney cortex of animal treated with 150 mg/kg body weight/ day of ZnO NPs for 15 days showed normal glomeruli (1), normal convoluted tubules (2). H &E stain 400X.

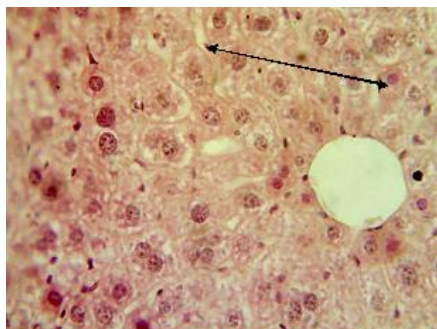


Figure (5): Section in mouse liver of animal treated with 150 mg/kg body weight/ day of ZnO NPs for 15 days showed proliferation of kupffer cells. H & E stain 400X.

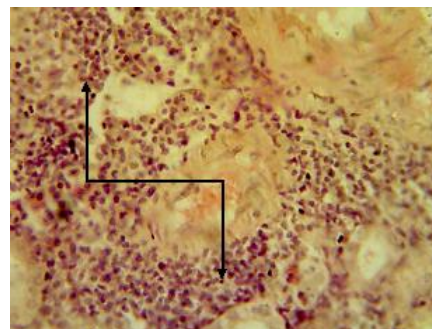


Figure (6): Section in mouse kidney of animal treated with 350 mg/kg body weight/ day of ZnO NPs for 15 days showed marked inflammatory cells particularly mononuclear cells aggregation around blood vessels and I between renal tubules. H & E stain 400X.

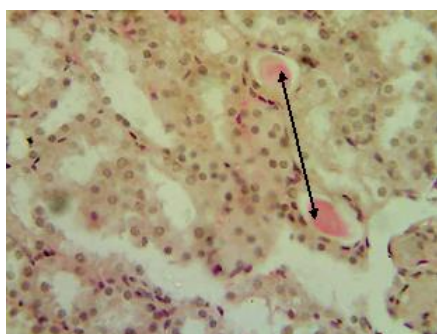


Figure (7): Section in mouse kidney of animal treated with 350 mg/kg body weight/ day of ZnO NPs for 15 days showed proteinous material in the lumen of renal tubules. H & E stain 400X.

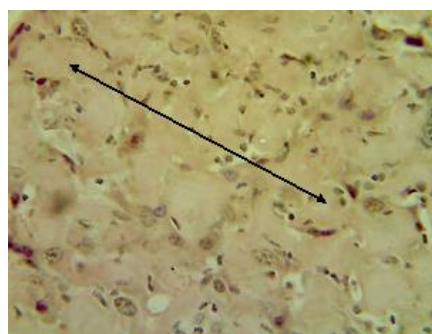


Figure (8): Section in mouse liver of animal treated with 350 mg/kg body weight/ day of ZnO NPs for 15 days showed amyloid like substance deposition in the wall of sinusoids and replacement of hepatic cords deposition in the wall of sinusoids. H & E stain 400X.

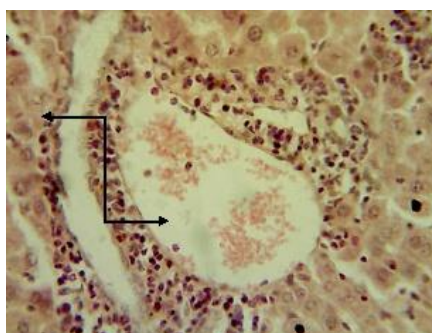


Figure (9): Section in mouse liver of animal treated with 350 mg/kg body weight/ day of ZnO NPs for 15 days showed inflammatory cells infiltration particularly neutrophils and mononuclear cells around congested blood vessels. H & E stain 400X.

Discussion

The small sizes of the particles have the ability to enter and damage the organism allows to penetrate the physiological barriers traveling with circulatory systems [14]. The study found that oral exposure to nano-forms of different particles was more toxic than micro-counterparts [15]. This study investigates the effect of ZnO NPs on the kidney and liver tissues. It can spread more in blood, kidney, liver and other organs [16]. This study agrees with Sharma V. *et al* results [17] showed that oral acute exposure to ZnO NPs causes apoptosis in mice liver cells and induces severe oxidative stress. Histopathological section showed that ZnO NPs is able to induce changes in tissues of kidney and liver in albino male mice. Liver damage could be induced due to excess oral ZnO NPs, and this agrees with another study in 2012 [18]. The histo-toxicity of ZnO NPs in high doses (350 mg/kg body weight/ day) was more than in low doses (150 mg/kg body weight/ day) in kidney and liver tissues.

Dietary exposure to titanium dioxide NPs caused liver toxicity and resulted in un activity of mice liver catalogs homogenate GOT [19]. Other studies have demonstrated that pathogenic mechanisms initiated by some NPs were dominated by inflammation-driven effects, which occurred due to the oxidative stress or DNA damage [20], This explains the influence of oxidative stress in cellular death by necrosis or degeneration in the mouse kidney and liver treated with ZnO NPs.

Conclusion

This study demonstrated the ability of ZnO NPs to effect on kidney and liver by causing pathological changes in these organs.

Recommendation

Further studies are needed to determine the effect of ZnO NPs on liver enzymes, blood parameters and histological study to other organs.

References

- [1] B A. Koeneman; Y. Zhang; P. Westerhoff; Y. Chen, and J C. Crittenden, Toxicity and cellular responses of intestinal cells exposed to titanium dioxide. *Cell Biol. Toxicol.* 26:225-238, 2010.
- [2] HJ. Johnston; G. Hutchison; FM. Christensen; S. Peters, and S. Hankin, A review of the in vivo and in vitro toxicity of silver and gold particles attributes and biological mechanisms responsible for the observed toxicity. *Cri. Rev. Toxicol.*, 40: 328-346, 2010.
- [3] B. Wang; W. Feng, and M. Wang, Acute toxicological impact of nano- and submicro-scaled zinc oxide powder on healthy adult mice. *J Nanopart Res* 10:263-276, 2008.
- [4] LM. Plum; L. Rink, and H. Haase, The essential toxin: impact of zinc on human health. *Int J Environ Res Public Health* 7: 1342-1365, 2010.
- [5] M.Esmaeillou; M. Moharamnejad, R. Hsankhani, AA. Tehrani and H. Maadi, Toxicity of ZnO nanoparticles in healthy adult mice. *Environment. Toxicol. Pharm.*, 35: 67-71, 2013.
- [6] J. Mohsen, and B. Zahra, Protein nanoparticle, Aunique system as drug delivery vehicles. *African J. of biotechnology*.7(25):2926-4934, 2008.

- [7] S.Galdiero;A. Falanga; M. Vitiello; M.Cantisani; M. Cantisani; V. Marrya, and M .Galdiero, Silver Nanoparticles as potential antiviral agents.Molecules 16, 8894-8918, 2011.
- [8] N.Duran; S. S.Guterres, and O.L. Alves, Nanotoxicology : Materials, Methodologies, and Assessments; Springer : New York, NY, USA, P. 412, 2014.
- [9] A. A.Taylor; I. M. Marcus; R.L. Guysi, and S. L. Walker, Metal Oxide Nanoparticles Induce Minimal Phenotypic Changes in a Model Colon Microbiota .Environ. Eng. Sci., V (00): NUM.00, 2015.
- [10] A.Keller;S. McFerran;A. Lazareva, and S. Suh, Global life cycle releases of engineered nanomaterials. J. Nanopart. Res. 15, 1, 2013.
- [11] S.S.Bhinder, and P.Dadra , Application of Nanostructure and New nanoparticles as advanced biomaterials. Asian J. of Chemistry, 21(10):5167-171, 2009.
- [12] G. Aragon, and Z.M. Younossi, When and how to evaluate mildly elevated liver enzymes in apparently healthy patients. Cleve. Clin. J. Med., 77(3): 195-204, 2010.
- [13] L. Vacca, Laboratory manual of histochemistry (1st ed.), Raven Press: New York. USA. 1985.
- [14] J. Wany;G. Zhou; H. Yu; T. Wang; et al, Acute toxicity and biodistribution of different sized titanium dioxide particles in mice after oral administration. Toxicol. Lett. 168: 176-185, 2007.
- [15] A. Dhawan, and V. Sharma, Toxicity assessment of nanomaterials: methods and challenges. Anal Bioanal Chem 398: 589-605, 2010.
- [16] JF. Hillyer, and RM. Albercht. Gastrointestinal per sorption and tissue distribution of differently sized colloidal gold nanoparticles. J Pharm. Sci. 90: 1927-1936, 2001.
- [17] V. Sharma; P. Singh; AK. Pandey, and A. Dhawan. Induction of oxidative stress DNA damage and apoptosis in mouse liver after sub-acute oral exposure to zinc oxide nanoparticles. Mutal Res 745: 84-91.
- [18] Sanaa A.A; Maha Z.R.; Samy A.A.; Hebatallah A.D., Mai O.K. Roll of potent antioxidants in regulation of SMAD-2 transcription and TGF-B1 signaling in nano sized titanium dioxide-induced oxidative injury in mice liver. Inter. J. Pharma. 5:17-26, 2015.
- [19] D. Xiong;T. Fang; L. Yu, X. Sima, and W. Zhu, Effect of nano-scale TiO₂, ZnO and their bulk counterparts on zebrafish: acute toxicity, oxidative stress and oxidative damage. Sci Total Environ, 409:1444-1452, 2011.
- [20] J X. Wang; GQ. Zhou; CY. Chen;HW .Yu; TC .Wang; YM. Ma; G. Jia; YX Gao; B. Li;J. Sun; YF. Li; F. Jia; YL. Zhao, and ZF. Chai,Acute toxicity and biodistribution of different sized titanium dioxide particles in mice after oral administration. Toxicol. Lett., 168 :176-185, 2007.