



## Dermatology Reports

<https://www.pagepress.org/journals/index.php/dr/index>

eISSN 2036-7406



**SIDCO**

Società Italiana di Dermatologia  
Chirurgica, Oncologica, Correttiva ed Estetica

**Publisher's Disclaimer.** E-publishing ahead of print is increasingly important for the rapid dissemination of science. **Dermatology Reports** is, therefore, E-publishing PDF files of an early version of manuscripts that undergone a regular peer review and have been accepted for publication, but have not been through the copyediting, typesetting, pagination and proofreading processes, which may lead to differences between this version and the final one.

The final version of the manuscript will then appear on a regular issue of the journal. E-publishing of this PDF file has been approved by the authors.

*Please cite this article as [Epub Ahead of Print] with its assigned doi:  
10.4081/dr.2023.9634*

 © the Author(s), 2023  
Licensee PAGEPress, Italy

Note: The publisher is not responsible for the content or functionality of any supporting information supplied by the authors. Any queries should be directed to the corresponding author for the article.

All claims expressed in this article are solely those of the authors and do not necessarily represent those of their affiliated organizations, or those of the publisher, the editors and the reviewers. Any product that may be evaluated in this article or claim that may be made by its manufacturer is not guaranteed or endorsed by the publisher.

## **A case of squamous cell carcinoma arising in a giant porokeratosis previously diagnosed as psoriasis**

Lorry Aitkens, BS<sup>1\*</sup>, Joel Byrne, MD<sup>1</sup>, Charay Jennings-Dover, MD<sup>2</sup>, Kathryn Anne Potter, MD<sup>1</sup>

<sup>1</sup>Department of Dermatology, Medical College of Georgia at Augusta University, Augusta, GA 30912

<sup>2</sup>SkinPath Solutions, Smyrna, GA 30080

\*Lorry Elizabeth Aitkens, 1399 Walton way Apt. 205 Augusta, GA 30901, [laitkens@augusta.edu](mailto:laitkens@augusta.edu), 404-313-8036

**Acknowledgements:** The authors would like to thank the Department of Dermatology at the Medical College of Georgia at Augusta University.

**Key-Words:** Giant Porokeratosis, Porokeratosis, Psoriasis, Squamous Cell Carcinoma

**Author contributions:** Each author contributed significantly to the preparation, analysis, writing and revision of this manuscript.

**Conflict of interest:** The authors have no conflicts to disclose.

**Funding:** None

**Ethical approval and consent to participate:** Written informed consent was obtained from the patient.

**Availability of data and material:** Data and materials are available by the authors.

**Abstract:**

Porokeratosis (PK) is a disorder of keratinization with a clinical presentation of an atrophic center surrounded by a hyperkeratotic border. Lesions of porokeratosis carry a risk of malignant transformation with giant porokeratosis (GPK) being a high-risk variant. We report a case in which a single, large, erythematous, scaly plaque in an immunocompromised patient showed initial histopathological features consistent with psoriasis and subsequent histological features consistent with GPK. This plaque underwent malignant transformation to SCC on three occasions. This case highlights that specimens taken from central portions of porokeratosis may resemble a variety of dermatoses histologically, including psoriasis, resulting in misdiagnosis as seen in our patient. When a patient presents with a diagnosis previously made that isn't responding to therapy as expected, repeat biopsy is appropriate.

**Introduction:**

Porokeratosis (PK) is a disorder of keratinization with a clinical presentation of an atrophic center surrounded by a hyperkeratotic border. It has a distinct histologic hallmark of cornoid lamella, an area of tightly packed parakeratotic cells in the superficial dermis, usually located at the peripheral border of the lesion. Lesions of porokeratosis carry a risk of malignant transformation with studies suggesting 6.9 to 30% of cases progress to nonmelanoma skin cancer (NMSC), most commonly squamous cell carcinoma (SCC).<sup>1</sup> While many variants of porokeratosis exist, linear porokeratosis and giant porokeratosis (GPK) are most commonly associated with malignant change.<sup>2</sup> There also seems to be an association between porokeratosis and immunosuppression, with one study noting 9 of 20 cases occurred in the setting of organ transplant.<sup>3</sup>

We report a case in which a single, large, erythematous, scaly plaque in an immunocompromised patient showed initial histopathological features consistent with psoriasis and subsequent histological features consistent with GPK. This plaque underwent malignant transformation to SCC on three occasions.

**Case Presentation:**

A 76-year-old male with Crohn's disease managed with 6-Mercaptopurine was clinically diagnosed with psoriasis on his left elbow and was prescribed topical steroids and vitamin d analogs for years. A new lesion subsequently appeared within the plaque, and biopsy revealed a well differentiated SCC, which was excised (Figure 1a). After another biopsy of the original plaque resulted as psoriasis, topical therapy was continued but never provided significant improvement. Two years later, biopsy of a discrete lesion within the plaque revealed another well differentiated SCC, which was also excised (Figure 1b). At this time, patient was started on tildrakizumab, which was chosen based on insurance coverage, but showed no improvement after 6 months. Another new lesion then arose within the plaque which prompted biopsy of the new lesion and repeat biopsy of the plaque given lack of response to biologic treatment (Figure 2). Biopsy of the lesion within the plaque revealed another well differentiated SCC. Biopsy of the leading edge of the plaque revealed cornoid lamellae, and a new diagnosis of GPK was secured (Figure 3). Given the unusual clinical presentation, previous biopsies were reviewed and were consistent with the original diagnoses of psoriasis and SCC.

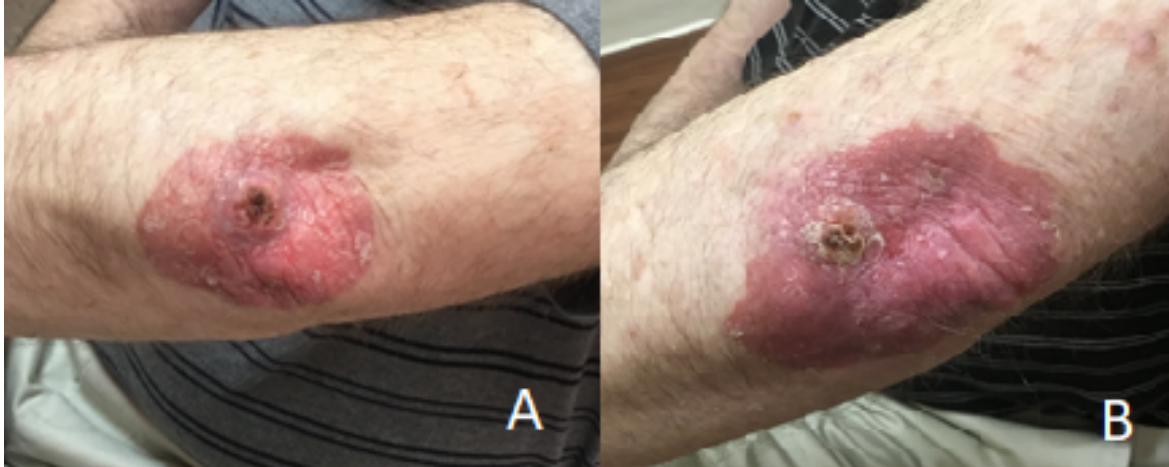


Figure 1A: 2018; 1B: 2021. An erythematous plaque with overlying scale on the left elbow exhibiting a new growth on the mediolateral portion with serosanguinous crust.

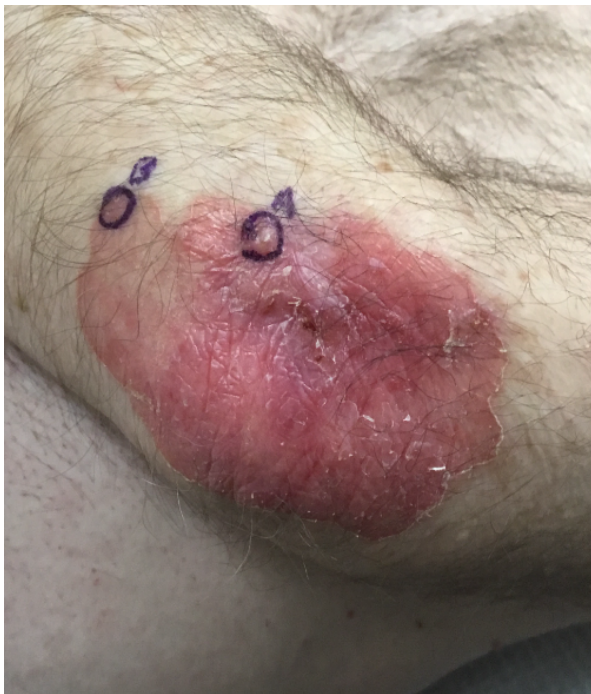

Figure 2: 2022: An erythematous, scaly plaque on the left elbow with a hyperkeratotic border exhibiting a new, discrete papule crust. Locations A and B were biopsied and revealed SCC and GPK, respectively.

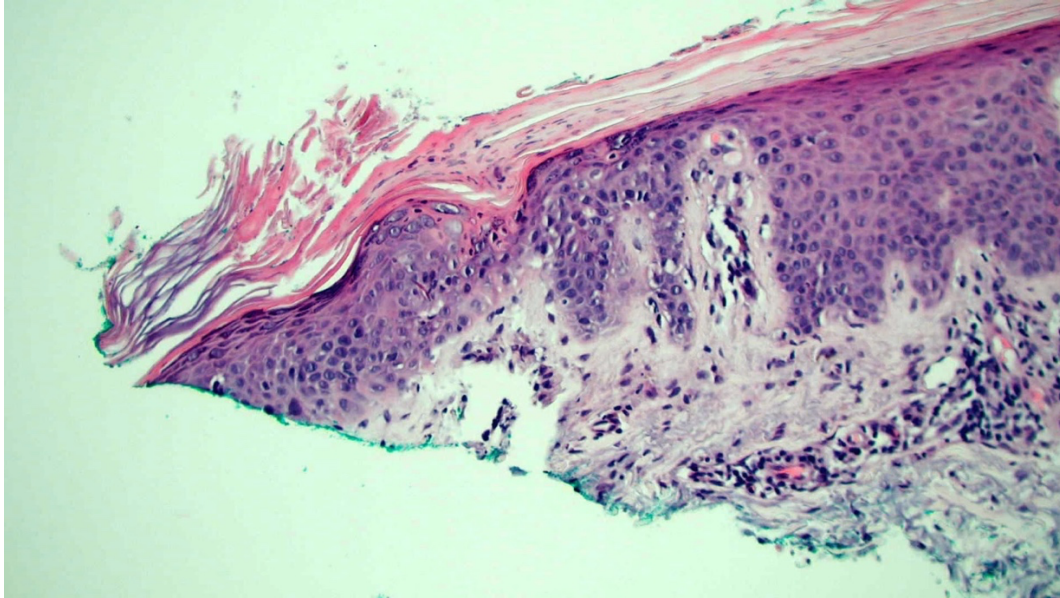


Figure 3: The biopsy shows classic microscopic features of porokeratosis, including hyperkeratosis and cornoid lamella (angulated tiered parakeratosis overlying a localized area of epidermal dyskeratosis).

### **Discussion:**

GPK, often classified as a type of porokeratosis of Mibelli, is an extremely rare variant of porokeratosis.<sup>4</sup> Clinically, it presents similar to porokeratosis of Mibelli with an atrophic center surrounded by a hyperkeratotic border, but it is larger in size. There is no strict definition for size, but most consider giant porokeratosis to be at least 10–20 cm in diameter.<sup>4</sup> The exact pathogenesis for PK remains unknown at this time but ultraviolet radiation and immune status have been proposed as potential contributors.<sup>3,5,6</sup>

Evidence suggests a risk of malignant transformation of PK, with GPK being one of the highest-risk variants.<sup>2</sup> PK is more likely to develop malignant lesions in patients with the following risk factors: (1) large lesions on the extremities; (2) a long disease course; (3) older persons; (4) sun exposure; (5) immunosuppression (8). Zhang et al. reported a rare case of metastatic SCC that arose within a lesion of GPK previously misdiagnosed as psoriasis.<sup>9</sup> This emphasizes the importance of having a low threshold to biopsy lesions arising within plaques of porokeratosis or plaques that may have previously been diagnosed as psoriasis, as was the case for our patient.

Multiple treatment options exist for porokeratosis. However, there are no published randomized control trials and therefore no standard treatment regimen exists. Current therapies include 5-fluorouracil, imiquimod cream, topical or systemic retinoids, topical vitamin D derivatives, topical steroids, cryotherapy, lasers, dermabrasion, and surgical intervention.<sup>7,8</sup>

This case highlights that specimens taken from central portions of PK may resemble a variety of dermatoses histologically, including psoriasis, resulting in misdiagnosis as seen in our patient. When a patient presents with a diagnosis previously made that isn't responding to therapy as expected, repeat biopsy is appropriate. In this case, repeat biopsies were performed twice before the actual diagnosis was made.

**Conclusion:**

Giant porokeratosis is an extremely rare variant of porokeratosis and is one of the highest-risk variants of porokeratosis for malignant potential. Dermatologists should be aware that central biopsies from a giant porokeratosis may resemble psoriasiform or lichenoid histopathologic change. Psoriatic plaques resistant to standard treatment should be re-biopsied to rule out alternative diagnoses.

**References:**

1. Ahmed A, Hivnor C. A case of genital porokeratosis and review of literature. *Indian J Dermatol*. 2015;60(2):217.
2. Williams GM, Fillman EP. Porokeratosis. *StatPearls*. Treasure Island (FL)2022.
3. Kanitakis J, Euvrard S, Faure M, Claudy A. Porokeratosis and immunosuppression. *Eur J Dermatol* 1998;8:459-465.
4. Vence L, Thompson CB, Callen JP, Brown TS. Giant Porokeratosis With Malignant Transformation to Squamous Cell Carcinoma. *Dermatol Surg* 2018;44:580-581.
5. Yazkan F, Turk BG, Dereli T, Kazandi AC. Porokeratosis of Mibelli induced by topical corticosteroid. *J Cutan Pathol* 2006;33:516-518.
6. Hazen PG, Carney JF, Walker AE, Stewart JJ, Engstrom CW. Disseminated superficial actinic porokeratosis: appearance associated with photochemotherapy for psoriasis. *J Am Acad Dermatol* 1985;12:1077-1078.
7. Koley S, Hassan SM, Saha S. Giant Porokeratosis: Report of Three Cases. *Indian Dermatol Online J* 2020;11:983-987.
8. Weidner T, Illing T, Miguel D, Elsner P. Treatment of Porokeratosis: A Systematic Review. *Am J Clin Dermatol* 2017;18:435-449.
9. Zhang F, Bai W, Sun S, Li N, Zhang X. Squamous cell carcinoma arising from giant porokeratosis and rare postoperative recurrence and metastasis: A case report. *Medicine (Baltimore)* 2020;99:e18697.
10. Podder I, Bandyopadhyay D. A Case of Psoriasis Encircled by Porokeratosis. *Indian J Dermatol* 2016;61:676-678.