

Zosteriform metastases from colon carcinoma: an unusual pattern

Paula Maio,¹ Cristina Amaro,¹
Ana Rodrigues,¹ Adelaide Milheiro,²
Jorge Cardoso¹

¹Department of Dermatology and Venereology and ²Department of Pathology, Hospital de Curry Cabral, Lisbon, Portugal

Abstract

Cutaneous metastases of internal malignancies occur infrequently and the zosteriform spread of the skin lesions represents a rare entity. We report here a case of cutaneous metastases from a colon carcinoma clinically mimicked Herpes varicella-zoster. The literature is also reviewed.

Introduction

Cutaneous metastases of internal malignancies occur infrequently and the zosteriform spread of the skin lesions represents a rare entity with only a few cases reported in the literature.

Skin metastases are more frequently seen as papules or nodules overlaying the skin that can show ulceration in later stages. The zosteriform pattern of distribution of these lesions is a particular and an even rarer form of presentation.

The authors report a case in which cutaneous metastases from a colon carcinoma clinically mimicked *Herpes varicella-zoster*. The corresponding literature is also reviewed.

Case Report

A 72-year-old-man presented with a six-week history of small papules and plaques limited to the inframammary region and left flank denying pruritus or pain with respect to this specific lesions.

He had been previously diagnosed with a Herpes varicella-zoster infection by a general practitioner and was treated with oral valacyclovir, 1000 mg three times a day. After the third day of therapy, he described clinical worsening and the additional appearance of multiple papules with similar morphology. The patient had a known medical history of

hemicolectomy for adenocarcinoma of the colon 5 years before and was being followed up regularly for known loco-regional lymph node metastasis (Modified Dukes staging system C2 and T3N1M0). He had been treated with adjuvant chemotherapy with 5-fluorouracil and folinic acid until two months before the time of evaluation at our clinic.

Clinical examination revealed patches, papules and small nodules limited to the skin on a background of erythema. The lesions had a zosteriform distribution pattern (Figure 1). The histopathological examination revealed infiltration by adenocarcinoma that was consistent with colorectal origin, showing an immunostaining that was CK 20 positive and CK7 negative (Figures 2 and 3). The search for varicella zoster virus DNA was negative.

Regarding treatment and follow-up, the area was too extensive to excise and the concomitant existence of multiple lesions was not suitable for surgical removal. The patient returned for systemic chemotherapy with capecitabine with slight improvement of the preexisting lesions. This partial remission was maintained for nine months until progression of the systemic disease, resulting from the patient death.

Discussion and Conclusions

The pattern of presentation of zosteriform cutaneous metastasis is rare and should be included in the differential diagnosis of zosteriform eruptions in immunocompromised patients.^{1,2} The common clinical characteristics are mainly of a topographic nature, with lesion distribution along dermatomes. The skin lesions can be heterogeneous, including papular, nodular or vesicobullous forms.^{3,4}

Cutaneous metastasis is defined as cancer spreading through the blood stream or lymphatic system to involve the skin.^{5,6} Cutaneous involvement by direct extension of the tumor or iatrogenic implantation is normally excluded from this specific definition.

The mechanisms that might predispose certain types of internal malignancies to give rise to cutaneous metastasis have rarely been discussed in the literature. In recent years, chemokines and their receptors have been shown to mediate tumorigenesis and the metastasis spreading process.⁷

One proposal mechanism for cutaneous metastatization is the expression of the chemokine receptor CCR10, which is involved in cutaneous metastasis of melanomas by mediating the survival, migration and growth of melanoma cells. The ligand CCL27/CTACK is a skin-specific chemokine that is expressed by epidermal keratinocytes. These interactions (CCR10 on tumor cells and CCL27/CTACK on the epidermis) may mediate the colonization

Correspondence: Paula Maio, Department of Dermatology and Venereology, Hospital de Curry Cabral, Lisbon, Portugal.
E-mail: paulamaio@gmail.com

Key words: cutaneous metastases, zosteriform, skin-homing mechanisms.

Conflict of interests: the authors report no potential conflict of interests.

Received for publication: 29 October 2011.

Revision received: 19 November 2011.

Accepted for publication: 7 December 2011

This work is licensed under a Creative Commons Attribution NonCommercial 3.0 License (CC BY-NC 3.0).

©Copyright P. Maio et al., 2012

Licensee PAGEPress, Italy

Dermatology Reports 2012; 4:e9

doi:10.4081/dr.2012.e9

by melanoma cells of non-primary cutaneous sites.^{7,8}

Other potentially implicated chemokines include CXCR4, which has been shown to be of major importance on not only the growth, angiogenesis and invasion of cutaneous basal cell carcinomas but also in the skin-homing mechanisms of Sézary cells.^{7,9}

The molecular mechanisms by which tumor metastasis occurs, are complex and incompletely understood.

Because the majority of cutaneous metastasis is found in the dermis, it is probable that the interaction between tumor cells and dermal and epidermal factors may play a crucial role in the skin-homing mechanism of metastatic cells.⁷

Different internal malignancies metastasize to the skin with different frequencies.^{10,11} The dermis may provide a favorable environment for the colonization and survival of metastatic breast carcinoma, as cutaneous adnexa and lactiferous ducts share similar embryonic origins. This may provide at least a partial explanation for the occurrence of a higher rate of skin metastasis of breast adenocarcinoma compared with adenocarcinomas of the gastrointestinal tract.

Usually, the median survival after diagnosis is approximately six months although it was slightly higher in the case of our patient.^{12,13}

The vast majority of cases exhibit a poor prognosis and an upgrading of the tumor staging.

We found that most of the reported cases in the literature (about one third) had previous been medicated with antiviral therapy before the correct diagnosis was made.¹²⁻¹⁴ The high degree of clinical suspicion and the histopathological examination are therefore essential for diagnosis and the correct therapeutic approach.

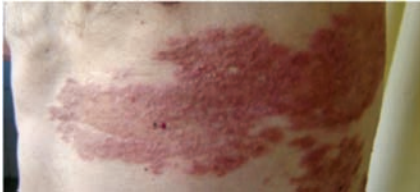

Figure 1. Clinical presentation with zosteriform pattern distribution.

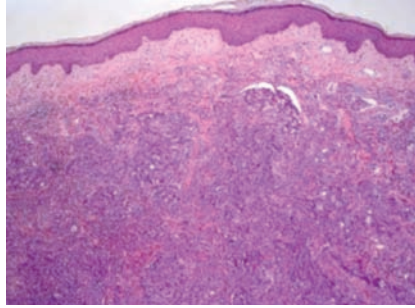


Figure 2. Histopathology (Hematoxylin and Eosin 10x).

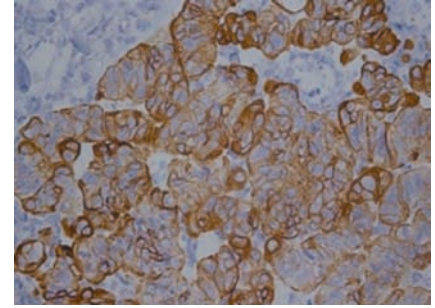


Figure 3. Immunohistopathology showing CD20 positivity.

Several theories have been proposed to explain the pathogenic mechanism by which zosteriform dissemination occurs, but none was adequately proven to date.^{12,14} Additional studies and proper biological profiling of the tumor cells may allow for better understanding of this pathogenesis and for the also proposal of new biological therapeutic targets.

References

1. Lookingbill DP, Spangler N, Sexton FM. Skin involvement as the presenting sign of internal carcinoma: a retrospective study of 7316 cancer patients. *J Am Acad Dermatol* 1990;22:19-26.
2. White JW Jr. Evaluating cancer metastatic to the skin. *Geriatrics* 1985;40:67-73.
3. Augustin G, Kekez T, Bodgdaria B. Abdominal popular zosteriform cutaneous metastasis from endometrial carcinoma. *Int J Gynaecol Obstet* 2010;110:74.
4. Manteaux A, Cohen PR, Rapini RP. Zosteriform and epidermotropic metastasis. Report of two cases. *J Dermatol Surg Oncol* 1992;18:97-100.
5. Ahmed I, Holley KJ, Charles-Holmes R. Zosteriform metastasis of colonic carcinoma. *Br J Dermatol* 2000;142:182-3.
6. Bauzá A, Redondo P, Idoate MA. Cutaneous zosteriform squamous cell carcinoma metastasis arising in an immunocompetent patient. *Clin Exp Dermatol* 2002;27:199-201.
7. Murakami T, Cardones AR, Finkelstein SE, et al. Immune evasion by murine melanoma mediated through CCR10 chemokine receptor. *J Exp Med* 2003;198:1337-47.
8. Cuerda E, Sanchez F, Mansilla I, et al. Malignant melanoma with zosteriform metastases. *Cutis* 2000;312-4.
9. Bianchi L, Orlandi A, Carboni I, et al. Zosteriform metastasis of occult bronchogenic carcinoma. *Acta Derm Venereol* 2000;80:391-2.
10. Werchau S, Hartschuh W, Hartmann M. Zosteriform metastasis of endometrial cancer. *Eur J Dermatol* 2009;19:401-2.
11. Shafiqat A, Viehman GE, Myers SA. Cutaneous squamous cell carcinoma with zosteriform metastasis in a transplant recipient. *J Am Acad Dermatol* 1997;37:1008-9.
12. Savoia P, Fava P, Deboli T, et al. Zosteriform cutaneous metastases: a literature meta-analysis and a clinical report of three melanoma cases. *Dermatol Surg* 2009;35:1355-63.
13. Hu SC, Chen GS, Wu CS, et al. Rates of cutaneous metastases from different internal malignancies: experience from a Taiwanese medical center. *J Am Acad Dermatol* 2009;60:379-87.
14. Niiyama S, Satoh K, Kaneko S, et al. Zosteriform skin involvement of nodal T-cell lymphoma: a review of the published work of cutaneous malignancies mimicking herpes zoster. *J Dermatol* 2007;34:68-73.