

# Vasculitis with panniculitis following botulinum toxin A injection for cosmetic use

Nastaran Namazi<sup>1</sup>, Reza M. Robati<sup>1</sup>, Sahar Dadkhahfar<sup>1</sup>, Anoush Shafiee<sup>1</sup>,  
Farahnaz Bidari-Zerehpoush<sup>2</sup>

1 Skin Research Center, Shahid Beheshti University of Medical Sciences, Tehran, Iran

2 Department of Pathology, Loghman Hakim Hospital, Shahid Beheshti University of Medical Sciences, Tehran, Iran

**Key words:** botulinum, botulinum toxin A, vasculitis

**Citation:** Namazi N, Robati RM, Dadkhahfar S, Shafiee A, Bidari-Zerehpoush F. Vasculitis with panniculitis following botulinum toxin A injection for cosmetic use. *Dermatol Pract Concept* 2016;6(1):6. doi: 10.5826/dpc.0601a06

**Received:** November 17, 2015; **Accepted:** December 29, 2016; **Published:** January 31, 2016

**Copyright:** ©2016 Namazi et al. This is an open-access article distributed under the terms of the Creative Commons Attribution License, which permits unrestricted use, distribution, and reproduction in any medium, provided the original author and source are credited.

**Funding:** None.

**Competing interests:** The authors have no conflicts of interest to disclose.

All authors have contributed significantly to this publication.

**Corresponding Author:** Reza M. Robati, MD, Skin Research Center, Shahid Beheshti University of Medical Sciences, Shohada-e Tajrish Hospital, Shahrdari St, 1989934148, Tehran, Iran. Tel. +98-21- 22741507; Fax; +98-21-22744393. Email. rezarobati@sbm.ac.ir

**ABSTRACT** Botulinum toxin A injection is performed most frequently for facial rejuvenation all over the world. Some bizarre and severe side effects have been reported after botulinum toxin A injection. Herein, we present a case of vasculitis with panniculitis after a patient underwent a cosmetic procedure that included injection of purported botulinum toxin A.

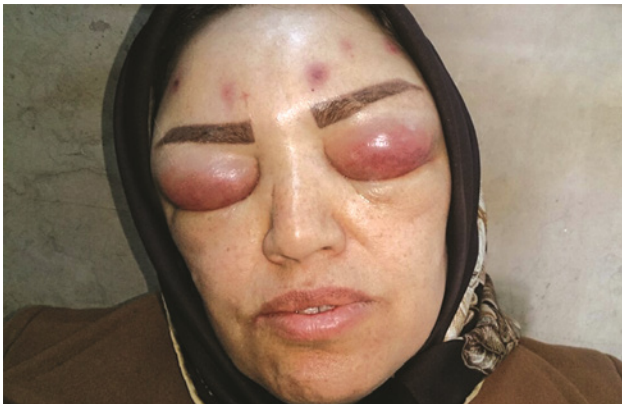## Introduction

Injections of botulinum toxin A (BTX-A) targeting the facial muscles is widely used in the treatment of hyperdynamic facial lines, and it could be completely useful to correct the glabellar, forehead, temporal and crow's feet lines [1]. As overall use of BTX-A increases, it is not far from expectation to come across unusual complications of this product. A number of minor cutaneous complications might be observed after BTA injection. Local irritation and bruising at the site of injections are the most common side effects [2,3]. Other rare adverse effects are necrotizing fasciitis and psoriasisiform eruption [4,5]. Unfortunately, the use of fake brands of BTX-A has been reported mainly due to their lower cost. These

unlicensed materials could probably cause more severe and bizarre side effects [6]. Herein, we present a case of vasculitis with panniculitis after a patient underwent a cosmetic procedure that included injection of purported botulinum toxin A.

## Case report

A 45-year-old female presented to our dermatology clinic with the complaint of progressive periorbital edema and erythema since the night before. She could not open her eyes due to prominent edema. She mentioned BTX-A injection for periorbital and glabellar rhytides for the first time in a private skin care office two weeks before that. She has been told to return after two weeks for further follow up and BTX-A re-



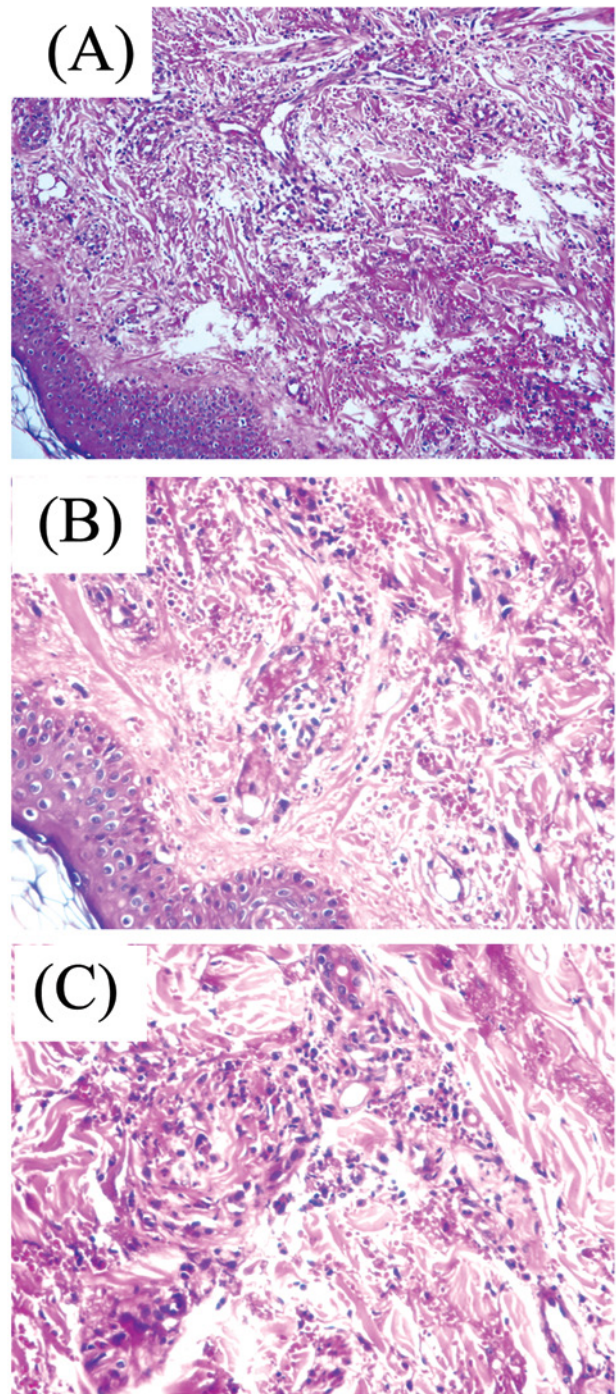
**Figure 1.** Prominent edema, purpuric papules and erythema in periorbital region and at the sites of BTX-A injection in the forehead. [Copyright: ©2016 Namazi et al.]

injection. Two hours after the second injection, she noticed progressive swelling and redness in the injection sites as well as periorbital area. She neither suffered from any systemic disease or allergy to the specific drug or products. There are limited registered brands of BTX-A in Iran, including Dysport (Ipsen Biopharmaceuticals Ltd, UK) and Neuronox (MedytoxInc, South Korea). The patient mentioned that the injected BTX-A was not of these registered brands and that she had had this injection done at a very low cost. After calling the clinic where this procedure was performed, we found the injected product to be Canitox, which is an unlicensed Chinese brand of BTX-A available in Iran.

On admission, her vital signs were stable. She did not have respiratory distress. The only abnormal finding in the physical examination was the prominent edema, purpuric papules and erythema in periorbital region and at the sites of BTX-A injection in the forehead (Figure 1). On the ophthalmological consult, her best corrected visual acuity, intraocular pressure and examination of anterior segment were normal. There were no signs of preseptal cellulitis.

The routine laboratory findings were normal. The histopathological examination revealed transmural infiltration of neutrophils and eosinophils with endothelial swelling and fibrinoid necrosis of the vessel walls. Leukocytoclasia and extravasation of RBC were the other findings. Moreover, there was infiltration of neutrophils and eosinophils in the subcutaneous fat. The infiltration consisted predominantly of neutrophils with scattered eosinophil aggregations. All these findings suggested the diagnosis of vasculitis with panniculitis (Figure 2).

Treatment was initiated with oral prednisolone at the dose of 0.5 mg/kg and hydroxyzine 25 mg daily. The response to treatment was dramatic and she showed significant improvement within two days. The prednisolone was continued for three consecutive days and tapered over two weeks. The patient's condition had not recurred at the two-month follow up.



**Figure 2.** (A and B). Transmurial infiltration of neutrophils and eosinophils with endothelial swelling and fibrinoid necrosis of the vessel walls and leukocytoclasia and extravasation of RBC. (C) Infiltration of neutrophils and eosinophils in the subcutaneous fat [H&E (A)x10, (B)x40, (C)x40]. [Copyright: ©2016 Namazi et al.]

## Discussion

According to the previous reports, a variety of skin reactions, such as exanthematous reactions, edema, pruritus, alteration in skin color at the site of injection, psoriasiform eruption and anaphylactic reactions can occur after BTX-A injection for both therapeutic and cosmetic purposes [5]. Sarcoidal granuloma was also reported after BTX-A injection [7]. Sev-

eral brands of BTX-A have been reported to cause bizarre reactions [6,8]. There is also a recent report of severe allergic reaction caused by Chinese botulinum toxin A injection to treat facial wrinkles [9].

The mechanism by which BTX-A induce the mentioned reaction is hardly understood. One explanation is the allergic potential of the toxin itself that may induce an immunologic reaction like any other protein. The other explanation is the effect of human serum albumin or gelatin added to the toxin in stimulating the immune reaction. The immune reactions toward biopharmaceutical products such as BTX-A can be categorized in two main types: classical immune reactions to neo-antigens that mainly occur after injection of animal products and a breakdown of immune tolerance. Several factors influence the immunogenic potential of BTX-A including its biochemical structure (e.g., denaturation through oxidation), storage setting, impurities in the preparation, dose and frequency of injections, site of application, and genetic predisposition of patients themselves [10]. These mentioned mechanisms might also have taken part in the reaction in our patient. According to the injection of BTX-A by a non-professional in this patient, the possibility of contamination or reactions to non-standard additive products, such as gelatin or sucrose, should also be considered [6,8].

In conclusion, it should be kept in mind that cosmetic procedures that involve injection of various agents may cause severe reactions, such as vasculitis that, although rare, are clinically significant to healthcare professionals.

## References

1. Ghalamkarpour F, Robati RM, Aryanejad F, Toossi P. Supraciliary wrinkles and botulinum toxin A. *Clin Exp Dermatol*. 2010;35:388-91.
2. Ascher B, Zakine B, Kestemont P, et al. A multicenter, randomized, double-blind, placebo-controlled study of efficacy and safety of 3 doses of botulinum toxin A in the treatment of glabellar lines. *J Am Acad Dermatol*. 2004;51:223-33.
3. Fagien S, Cox SE, Finn JC, et al. Patient-reported outcomes with botulinum toxin type A treatment of glabellar rhytids: a double-blind, randomized, placebo-controlled study. *Dermatol Surg*. 2007;33:S2-9.
4. Latimer PR, Hodgkins PR, Vakalis AN, et al. Necrotising fasciitis as a complication of botulinum toxin injection. *Eye (Lond)*. 1998;12:51-3. 9614517
5. Bowden JB, Rapini RP. Psoriasiform eruption from intramuscular botulinum A toxin. *Cutis*. 1992;50:415-6.
6. Coleman K, Zilinskas RA. Fake botox, real threat. *Sci Am*. 2010; 302:84-9.
7. Assmann T, Krahl D, Mang R. Cutaneous sarcoidal granuloma after botulinum toxin type A injection. *J Am Acad Dermatol*. 2013;69:e247-9.
8. Pickett A, Mewies M. Serious issues relating to the clinical use of unlicensed botulinum toxin products. *J Am Acad Dermatol* 2009;61:149-50.
9. Careta MF, Delgado L, Patriota R. Report of allergic reaction after application of botulinum toxin. *Aesthet Surg J*. 2015;35:NP102-5.
10. Schellekens H. Factors influencing the immunogenicity of therapeutic proteins. *Nephrol Dial Transplant*. 2005;20 Suppl 6: vi3-9.