

Longterm digital monitoring in the diagnosis and management of congenital nevi of the nail apparatus showing pseudo-Hutchinson's sign

Mizuki Sawada¹, Sumiko Ishizaki¹, Ken Kobayashi¹, Itaru Dekio¹, Masaru Tanaka¹

¹ Department of Dermatology, Tokyo Women's Medical University Medical Center East, Tokyo, Japan

Keywords: Hutchinson's sign, nevus of the nail apparatus, congenital, dermoscopy, periungual pigmentation, longterm digital monitoring

Citation: Sawada M, Ishizaki S, Kobayashi K, Dekio I, Tanaka M. Longterm digital monitoring in the diagnosis and management of congenital nevi of the nail apparatus showing pseudo-Hutchinson's sign. *Dermatol Pract Concept*. 2014;4(2):7. <http://dx.doi.org/10.5826/dpc.0402a07>

Received: December 16, 2013; **Accepted:** January 25, 2014; **Published:** April 30, 2014

Copyright: ©2014 Sawada et al. This is an open-access article distributed under the terms of the Creative Commons Attribution License, which permits unrestricted use, distribution, and reproduction in any medium, provided the original author and source are credited.

Funding: None.

Competing interests: The authors have no conflicts of interest to disclose.

All authors have contributed significantly to this publication.

Corresponding author: Masaru Tanaka, M.D., Department of Dermatology, Tokyo Women's Medical University Medical Center East, 2-1-10 Nishi-Ogu, Arakawa-ku, Tokyo 116-8567, Japan. Tel. +81 3 3810 1111; Fax. +81 3 3894 1441, E-mail: tanaka.twmu@gmail.com

Introduction

Congenital nail apparatus nevi often show substantial enlargement and wide involvement and greatly concern parents of a child as well as dermatologists. The differential diagnosis from melanoma is critical. The biopsy of the nail matrix is very traumatic and a fearful experience for a child. Therefore, a longterm careful follow-up with digital monitoring is very important and should be the first choice of management.

Ronger et al. [1] reported that only three cases of melanoma showed micro-Hutchinson's sign in 148 cases of melanonychia. However, similar findings are also observed in congenital nevus of the nail apparatus. We report three cases of congenital or early-onset nevus of the nail apparatus with minute periungual regular pigmentation found on dermoscopy.

We used the terms, "Hutchinson's sign" and "pseudo-Hutchinson's sign" based on the original descriptions [2, 3]. Baran and Kechijian [3] originally defined the term, pseudo-Hutchinson's sign, for three conditions, including 1) benign pigmentation of the nailfolds, 2) pigmentation of the nailfolds

due to malignant but non-melanoma tumors, 3) pigmentation seen through translucent nailfolds.

Case presentations

Case 1

A 10-year-old Japanese boy presented with pigmentation of the nail of the right ring finger. The lesion was noticed at birth. Physical examination showed melanonychia of the fingernail. He had been followed up for eight years. Dermoscopy showed regular dark brown lines and a brown band (Figure 1A–F). Dermoscopy performed from 2008 to 2012 also showed several blue-gray dots along the brown lines. These blue-gray dots disappeared on the dermoscopy performed in 2013. There was a regular minute fibrillar pattern on the proximal nailfold and subtle pigmentation on the lateral nailfold. The minute fibrillar pattern was also observed under the distal nail edge, namely the hyponychium. These minute periungual pigmentations were not noticed at the initial clinical examination (Figure 1G). The follow-up revealed that the dark brown lines were gradually decreasing and the

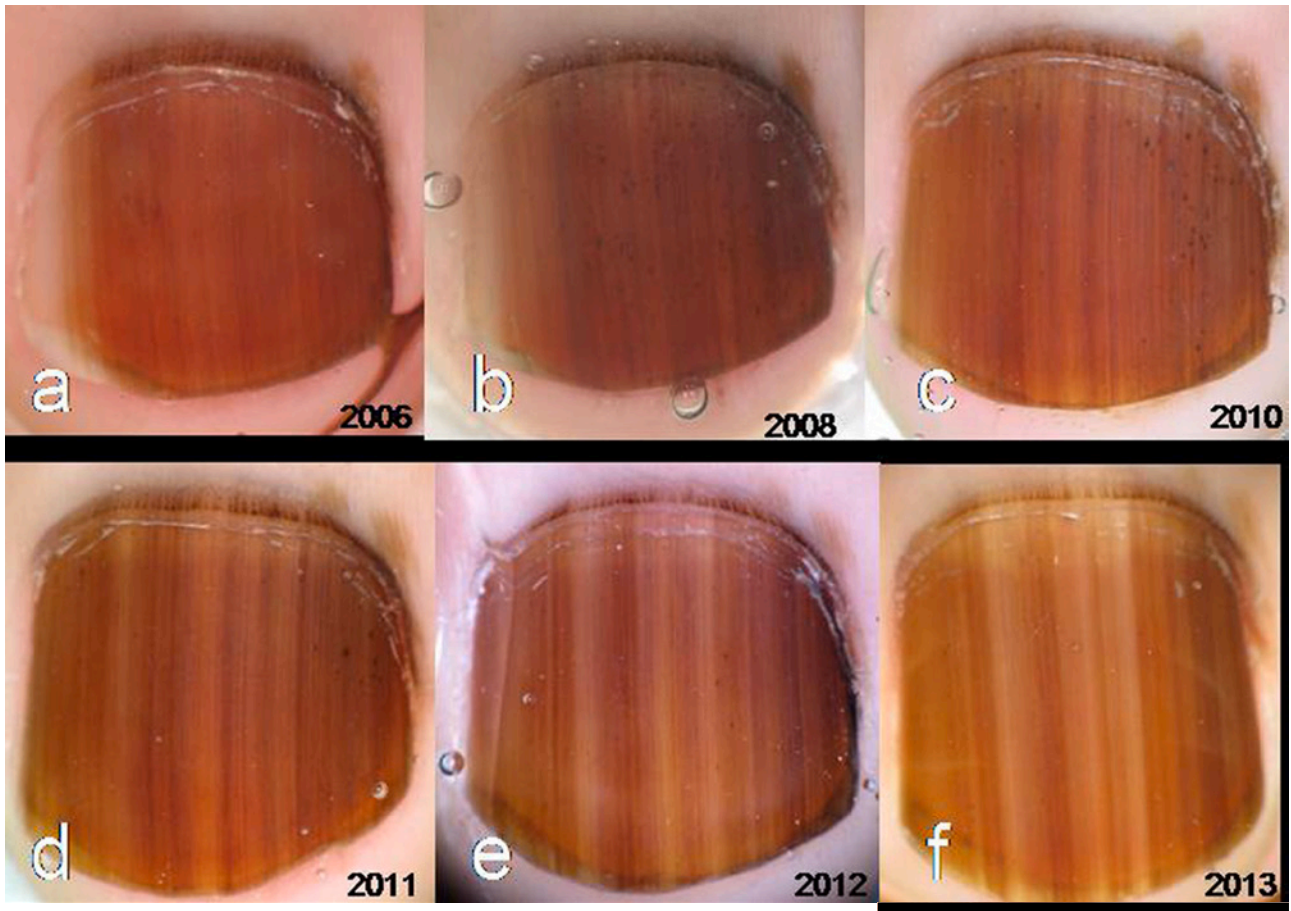


Figure 1. Dermoscopy of case 1.

Dermoscopy showed regular dark brown lines and a brown background band (A–F), and dermoscopy from 2008 (B) to 2012 (E) also showed several blue-gray dots along the brown lines. There was a regular minute fibrillar pattern on the proximal nailfold and hyponychium and subtle pigmentation on the lateral nailfold. The clinical picture disclosed prominent nail pigmentation, but periungual pigmentation was too subtle to notice (G). [Copyright: ©2014 Sawada et al.]

blue-gray dots were subsiding. A possibility of melanoma has been ruled out because of scarce change through the follow-up for eight years.

Case 2

An 11-year-old Japanese boy presented with pigmentation of the nail of the right middle finger. The lesion was noticed when he was 7 years old. Physical examination showed melanonychia of the fingernail. He had been followed up for three years. Dermoscopy showed regular dark brown lines and a brown band (Figure 2A–C). The brown background band slightly widened compared with previous dermoscopy results, however, the dark brown lines on the band were gradually decreasing. There were also blue-gray dots along the brown lines, which also seemed to be gradually decreasing. There was a regular minute fibrillar pattern on the proximal nailfold, which was not noticed at the clinical examination. A possibility of melanoma has been ruled out because of scarce change through the follow-up for three years.

Case 3

A 12-year-old Japanese boy presented with pigmentation of the nail of the right third toe. The lesion was noticed at birth. The amount of pigmentation increased after 3 years. Physical examination showed melanonychia of the fingernail. He had been followed up for three years. Dermoscopy showed regular dark brown lines and a brown band (Figure 3A–C). There was regular fibrillar minute periungual pigmentation, which was not noticed at the clinical examination (Figure 3D), on the proximal nailfold, lateral nailfold, and hyponychium. The pigmentation on the hyponychium observed in 2007 seemed to have been decreasing. A possibility of melanoma has been ruled out because of scarce change through the follow-up for three years.

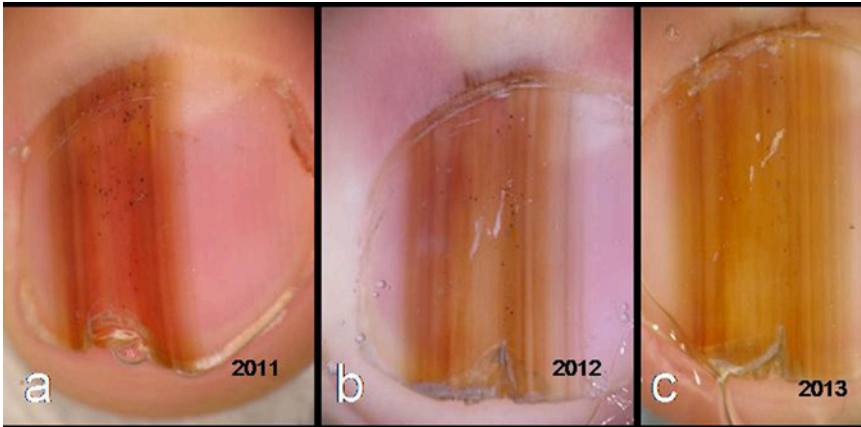


Figure 2. Dermoscopy of case 2. Dermoscopy showed regular dark brown lines and a brown background band (A–C). The brown background band slightly widened, but the dark brown lines on the band is gradually decreasing. There was a regular minute fibrillar pattern on the proximal nailfold. [Copyright: ©2014 Sawada et al.]

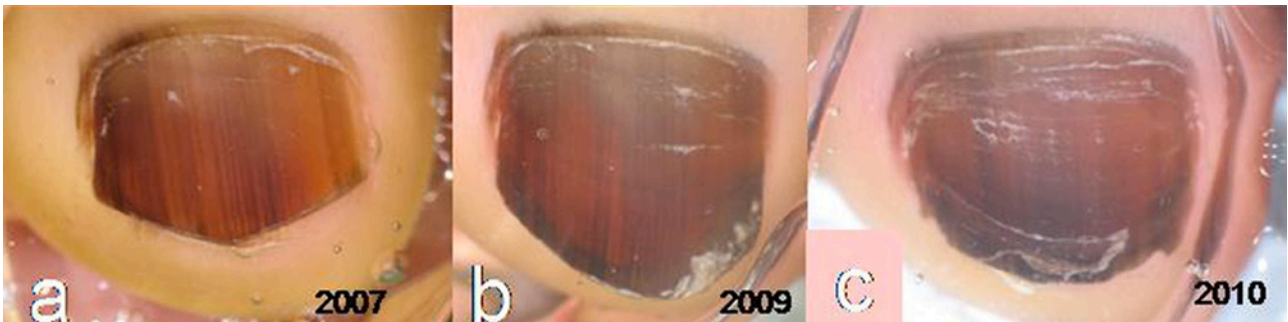
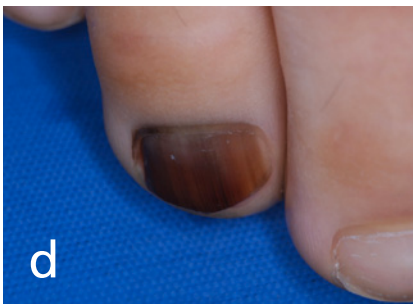

Figure 3. Dermoscopy of case 3. Dermoscopy showed regular dark brown lines and a brown band (A–C). There was regular fibrillar minute periungual pigmentation on the proximal nailfold, lateral nailfold, and hyponychium. Clinical picture disclosed prominent nail pigmentation, but periungual pigmentation was too subtle to notice (D). [Copyright: ©2014 Sawada et al.]



Discussion

The brown-black periungual pigmentation seen in melanoma is known and described as Hutchinson’s sign [2]. However, such periungual pigmentation could be found not only in melanoma but also in various benign conditions such as congenital nevus, Laugier-Hunziker-Baran syndrome, subungual hematoma, and nonmelanoma skin cancer such as Bowen’s disease, or in the pigmentation observable through the translucent nailfolds [3]. Ronger et al. described the minute periungual pigmentation in melanomas as micro-Hutchinson’s sign, which is difficult to find with the naked eye but could be observed on dermoscopy. They reported that micro-Hutchinson’s sign was observed only in three cases of nail apparatus melanoma, but not in nevi from 148 melanonychia cases [1]. As we noted similar minute periungual pigmentation in congenital nevus of the nail apparatus, we presented three such cases. Our follow-up observation revealed that congenital or early-onset nevus of the nail apparatus also showed minute periungual pigmentation. Therefore, we described and named them as “pseudo-micro-Hutchinson’s sign.” However, as this term seems to describe several different conditions, we



Figure 4. “Neumatic” pattern resembling the notation of the Gregorian chant. The dots and lines in the regressing melanonychia show a “neumatic” pattern. [Copyright: ©2014 Sawada et al.]

recommend using a simple term “periungual pigmentation” or “periungual minute pigmentation” and to describe the distribution of the pigmentation as either regular or irregular fibrillar pigmentation.

Although congenital nevus often shows periungual pigmentation, resulting in increased concern on the part of the clinician and therefore necessitating biopsy, we would like to

propose that a biopsy is not necessarily applicable. Instead, if dermoscopic features are regular in lines, longterm follow-up is important to rule out melanoma. In our opinion, all the nevi in children would increase in size for certain periods at the beginning and then decrease in pigmentation. One of the signs for regression is the “neumatic notation”-like blue-gray dots, as Murata and Kumano reported [4]. When this sign is observed, we would wait and expect that the nail pigmentation might disappear. Therefore, we think that it is more important to follow up on the changes of the nevus rather than to biopsy it. A biopsy of nail matrix would result in permanent nail deformity; additionally, the procedure of a biopsy is a fearful experience for children in this age.

The blue-gray dots are a sign of regression of melanonychia in children [4]. This finding would correspond to transepithelial elimination of melanin or apoptotic melanocytes in the nail plate. As originally described by Murata and Kumano, these dots appear like the neumatic notation of the Gregorian chant (Figure 4). Knowledge about this feature is

important because it would help explain to the patient’s family that the melanonychia might disappear in the future. We would also like to emphasize the importance of the longterm follow-up of the melanonychia in children rather than histopathological examination, which could leave permanent nail deformity, to rule out melanoma.

These cases were presented at the 65th Western Division Meeting of the Japanese Dermatological Association.

References

1. Ronger S, Touzet S, Ligeron C, et al. Dermoscopic examination of nail pigmentation. *Arch Dermatol.* 2002;138:1327-33.
2. Kopf AW. Hutchinson’s sign of subungual malignant melanoma. *Am J Dermatopathol.* 1981;3:201-2.
3. Baran R, Kechijian P. Hutchinson’s sign: a reappraisal. *J Am Acad Dermatol.* 1996;34:87-90.
4. Murata Y, Kumano K. Dots and lines: a dermoscopic sign of regression of longitudinal melanonychia in children. *Cutis.* 2012;90:293-6.