

Supplementary Material

Figure S1. The complete set of 100 dermoscopic images of intraepidermal carcinomas included in the study.

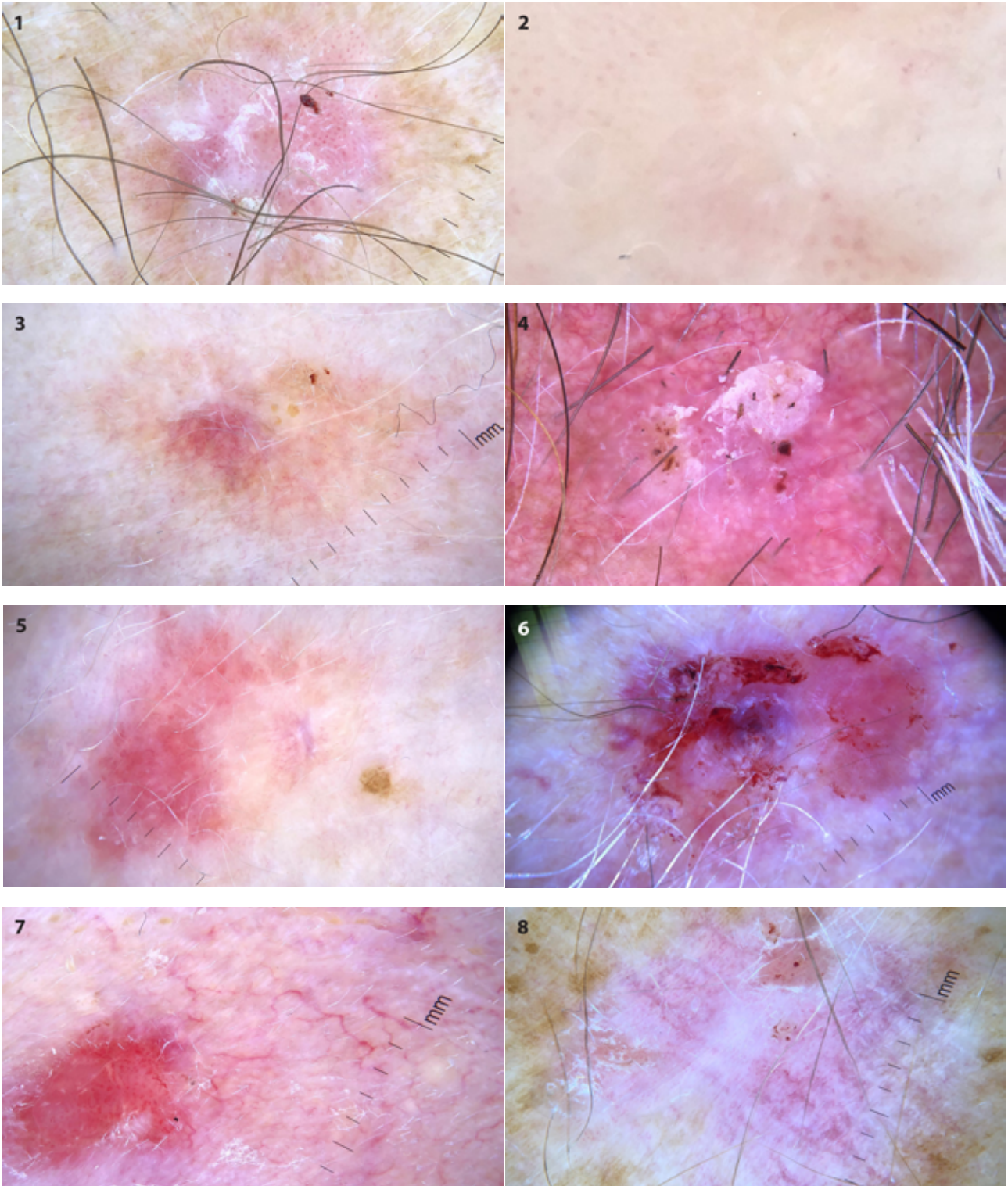
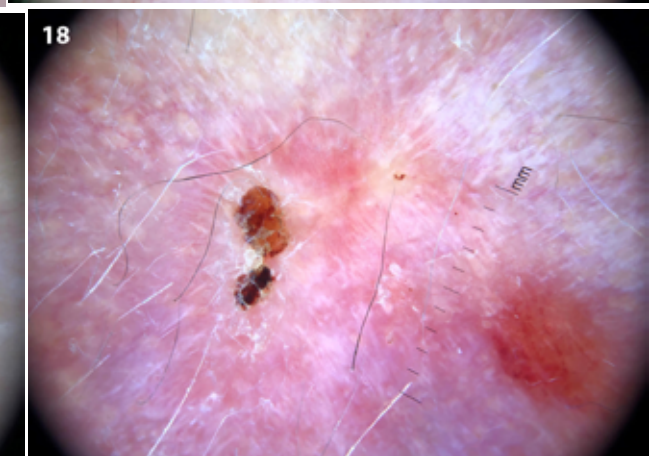
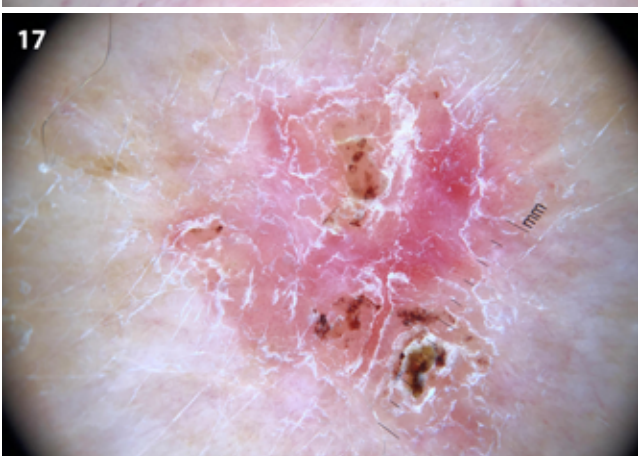
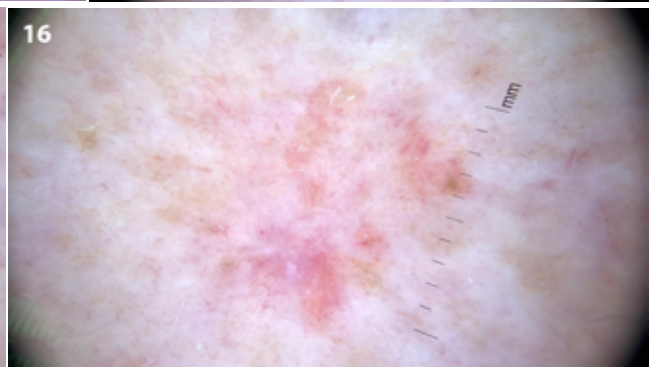
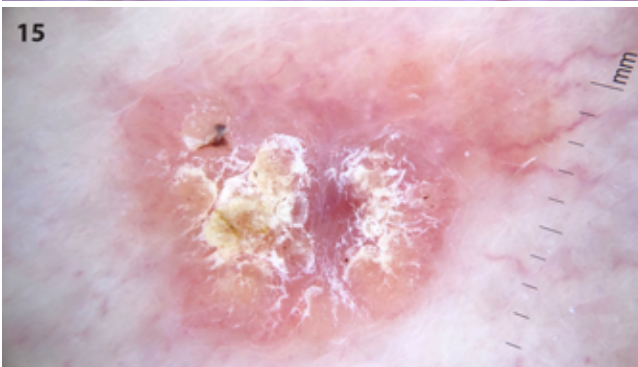
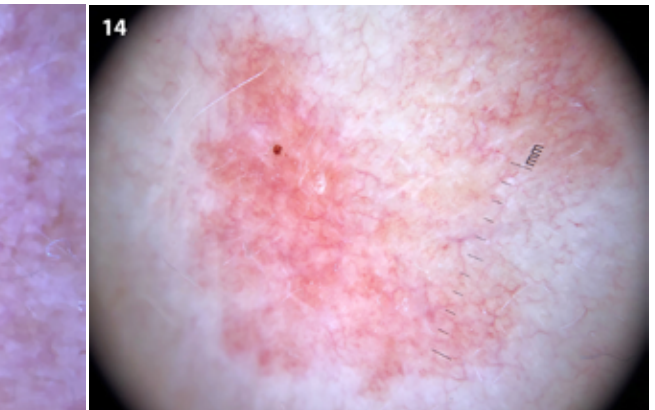
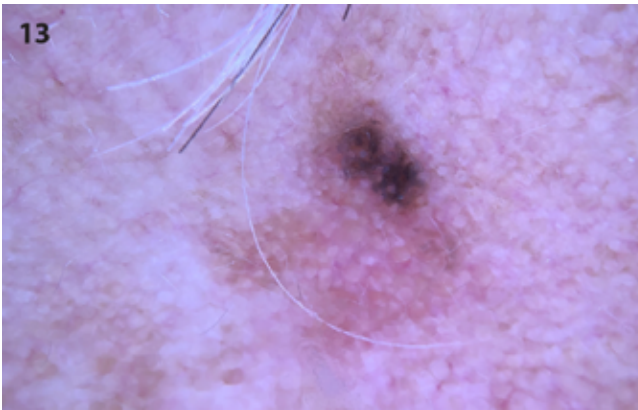
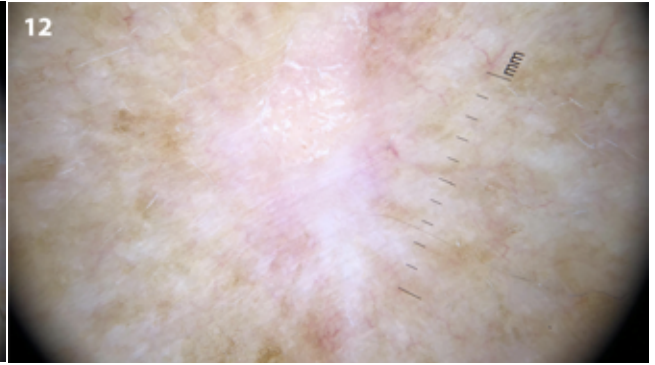
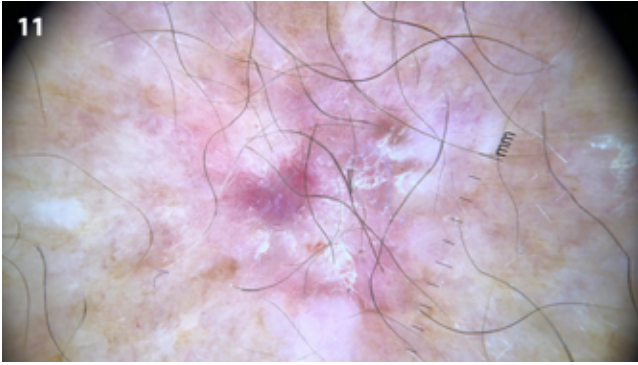
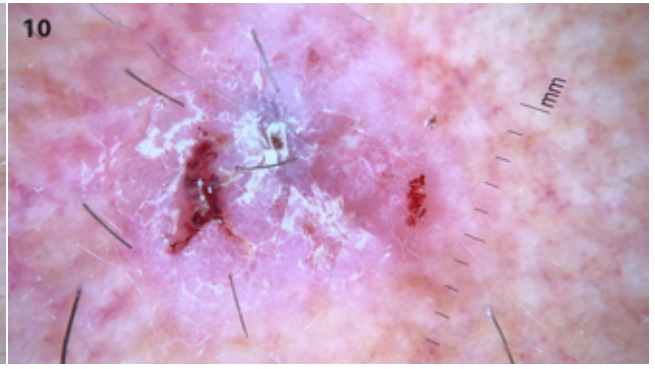



Figure S1 continues



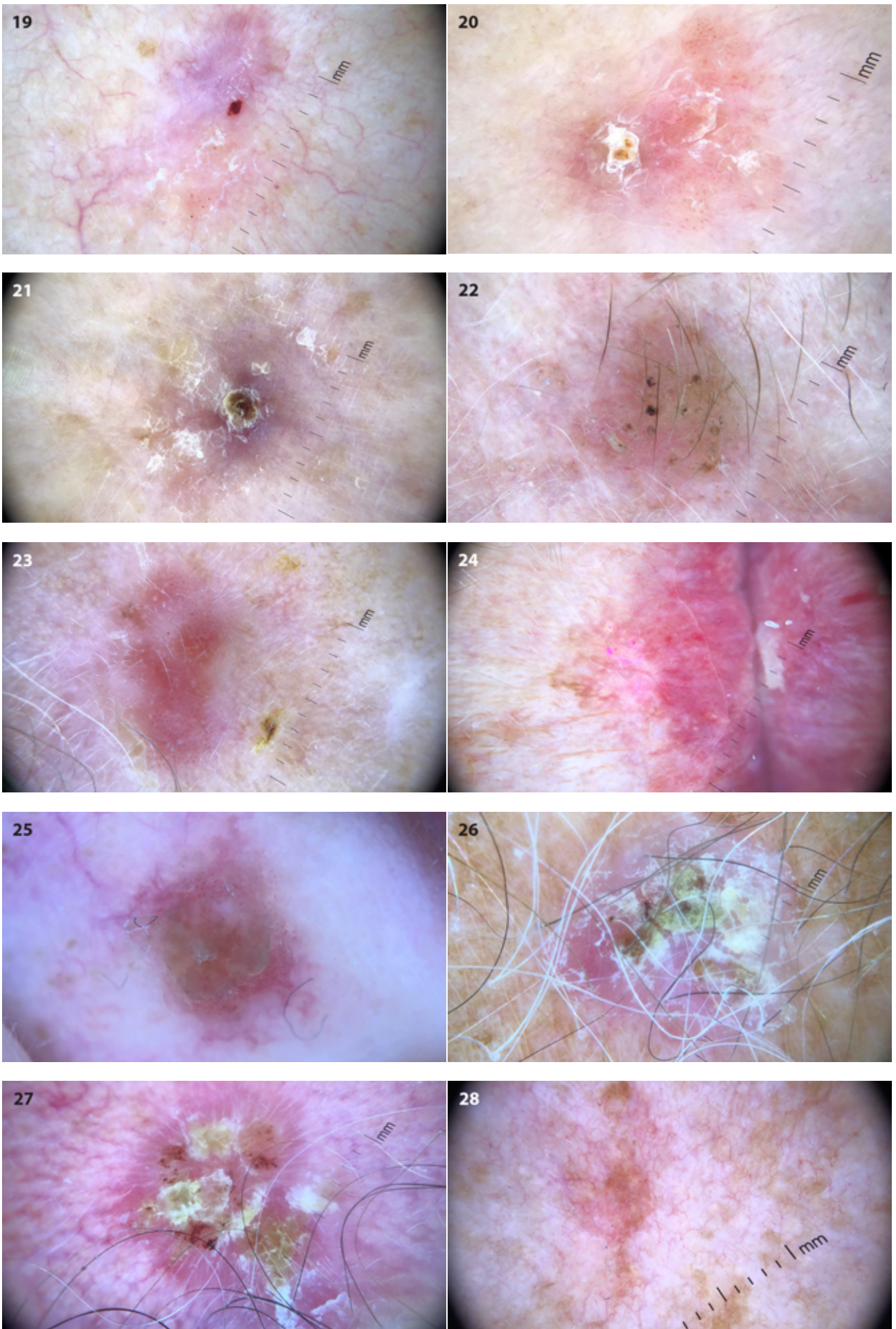
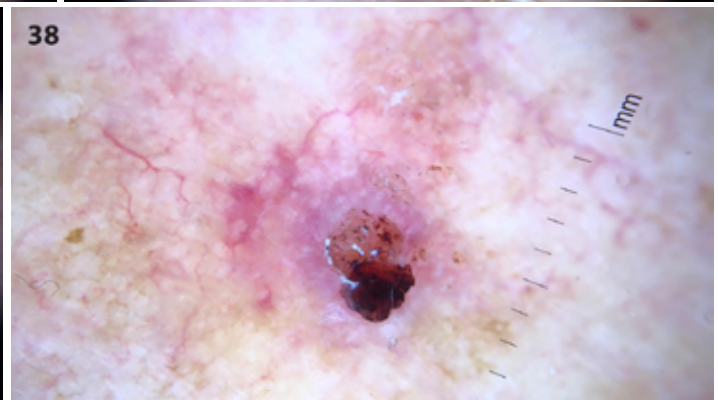
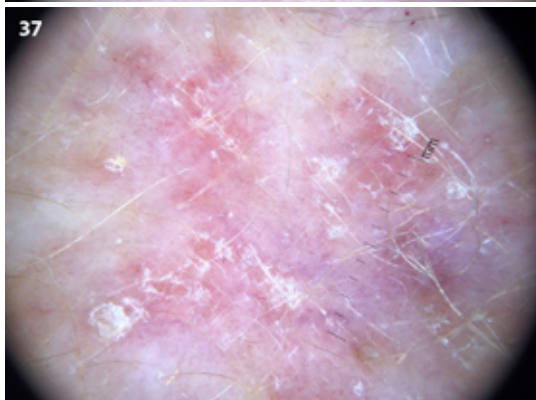
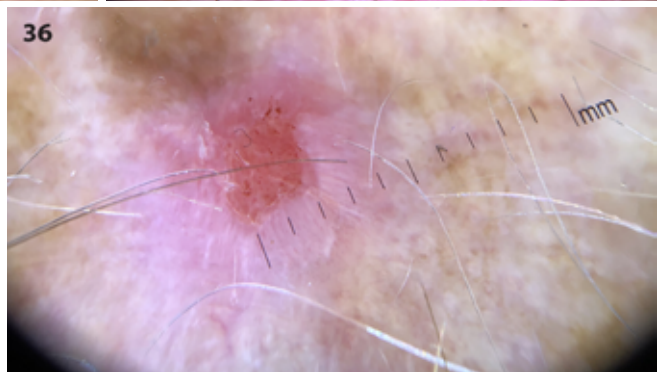
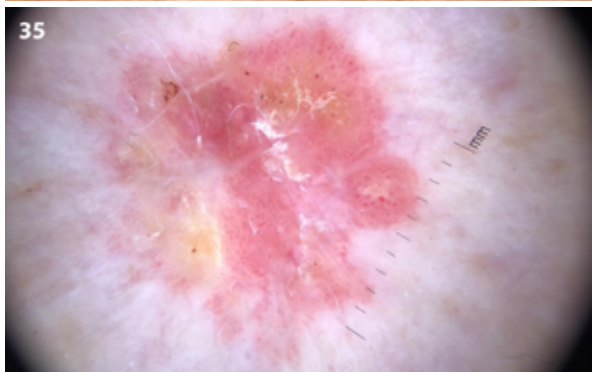
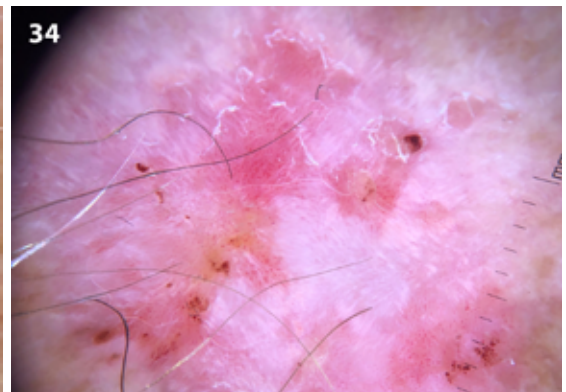
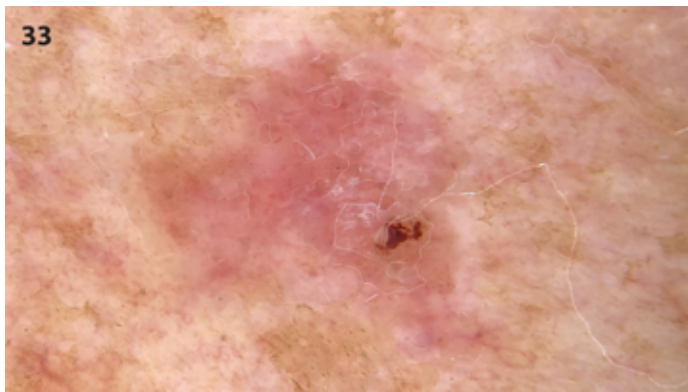
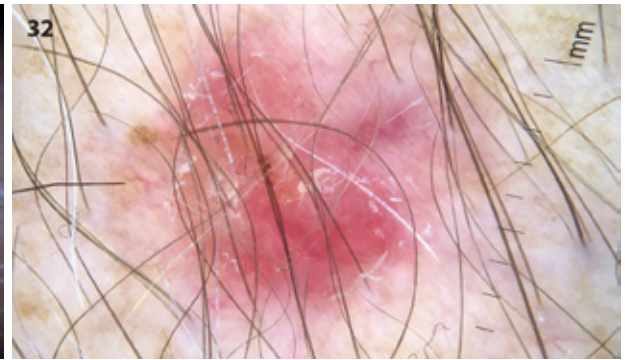
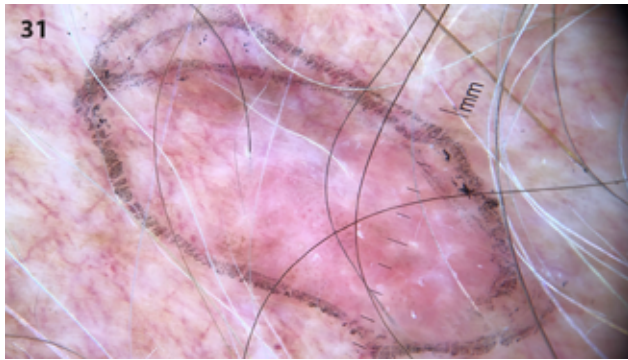
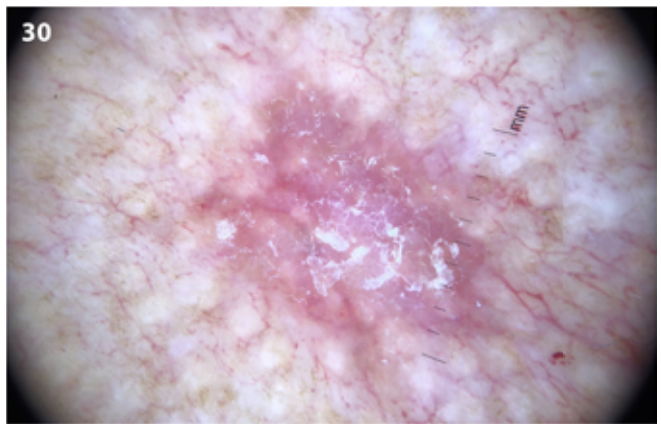
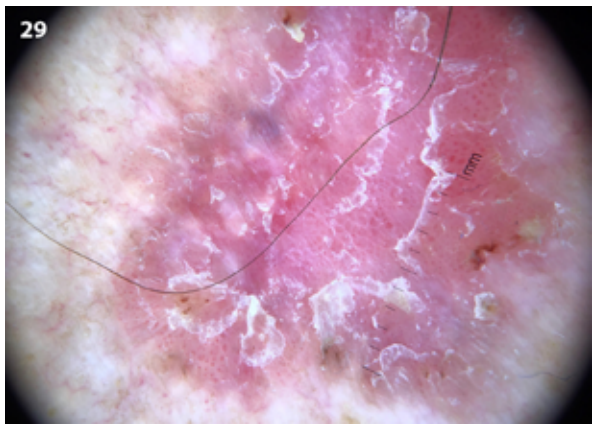


Figure S1 continues



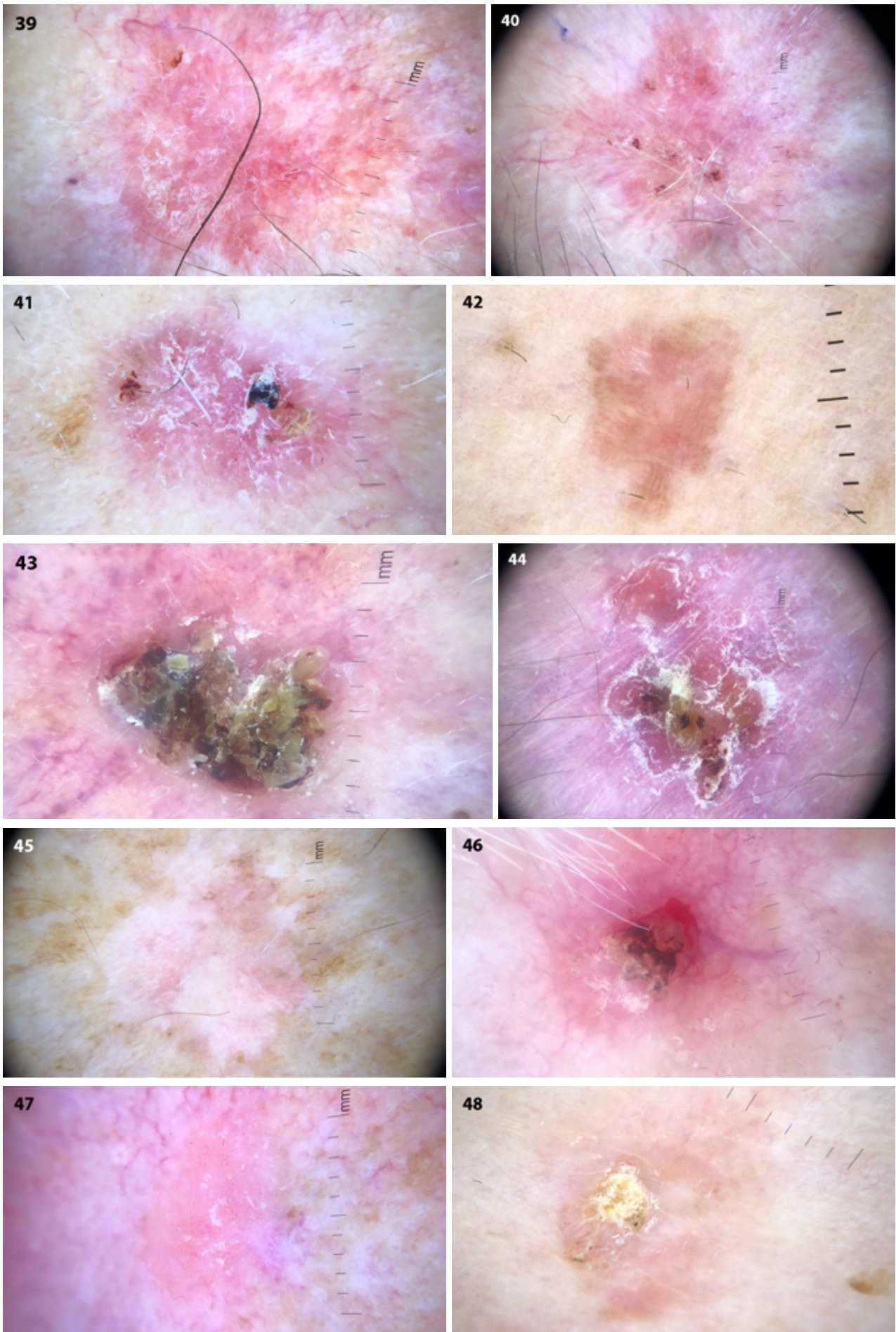
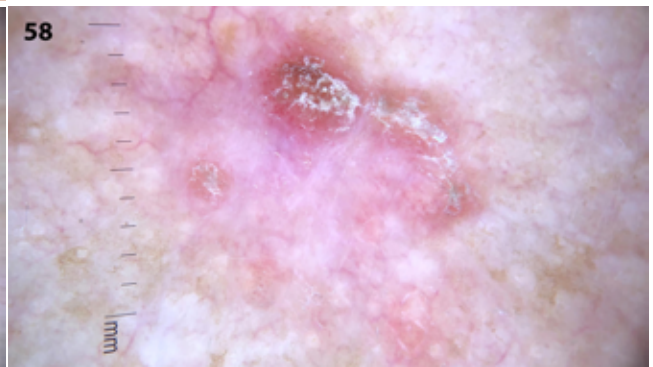
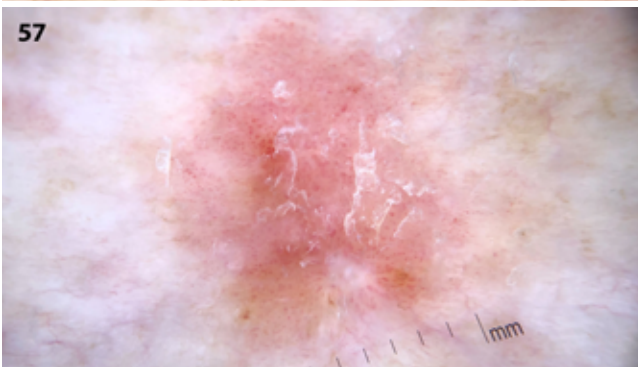
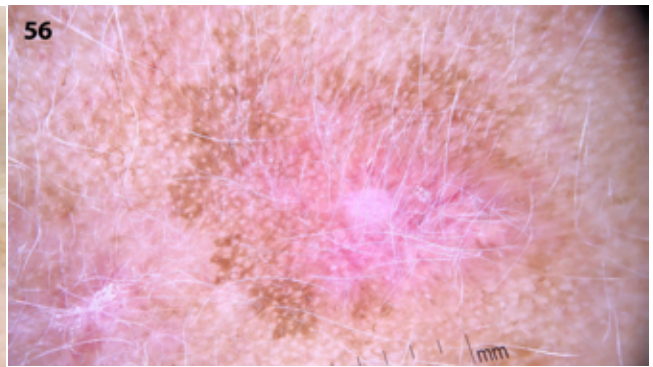
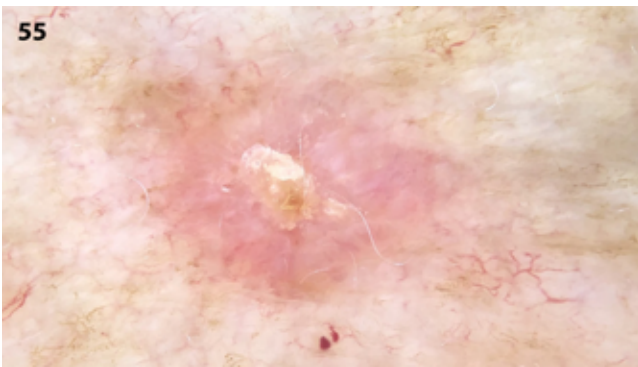
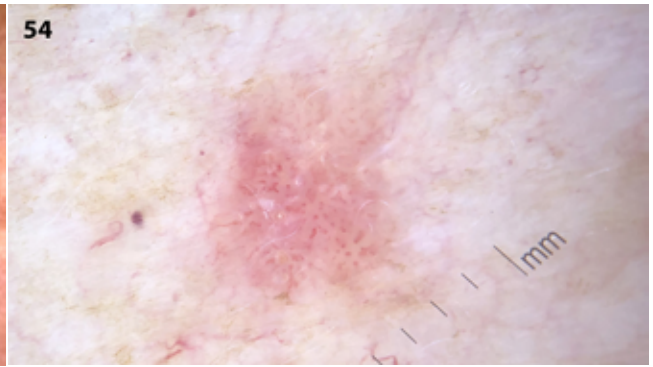
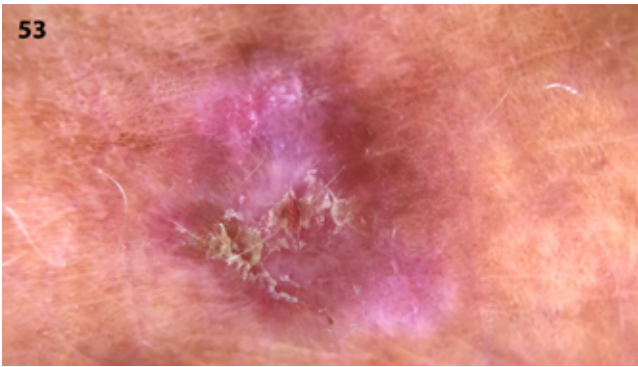
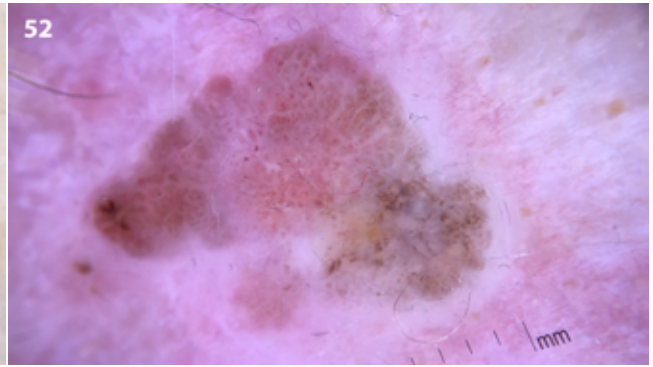
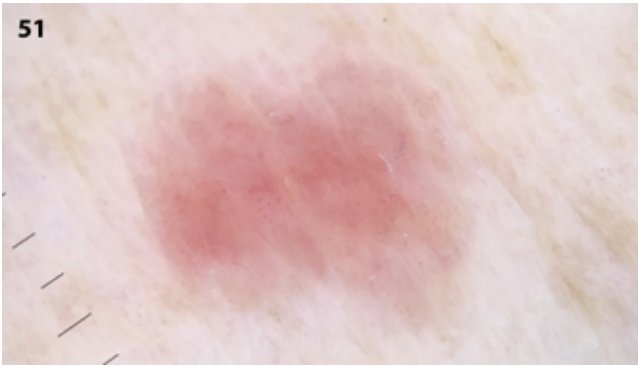
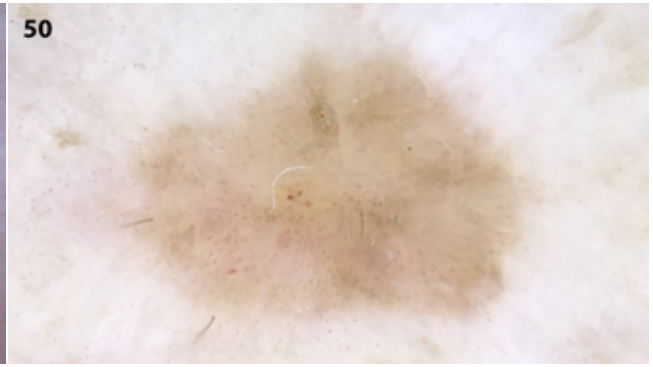
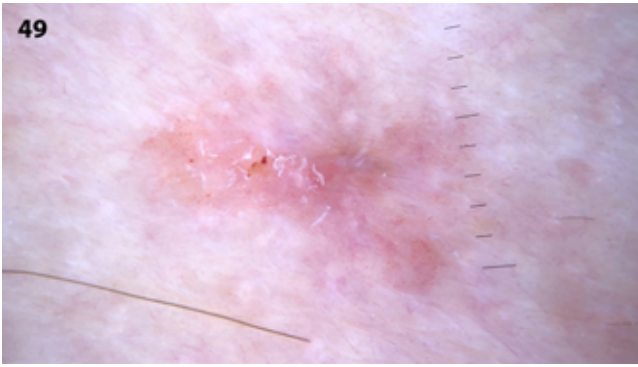


Figure S1 continues



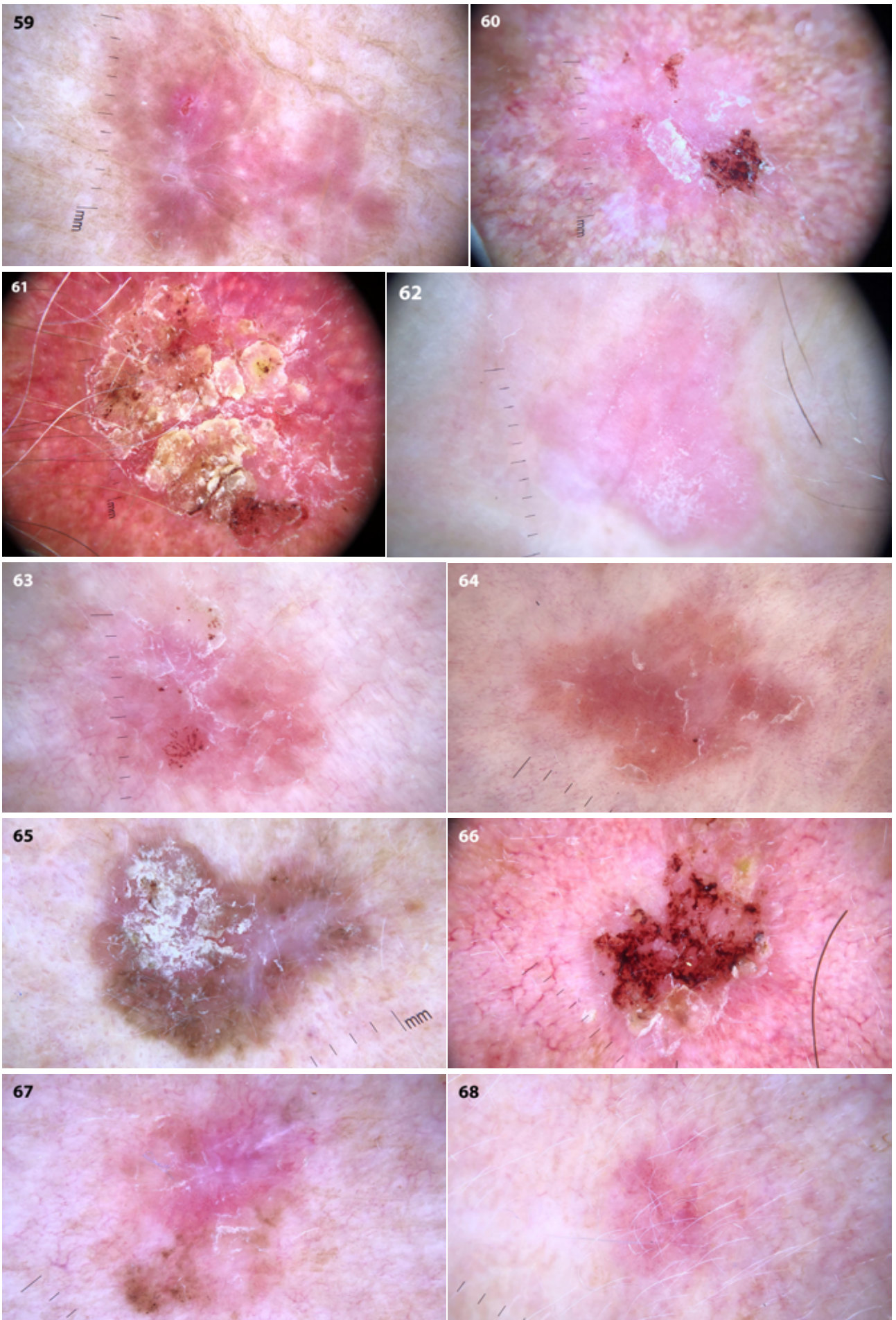
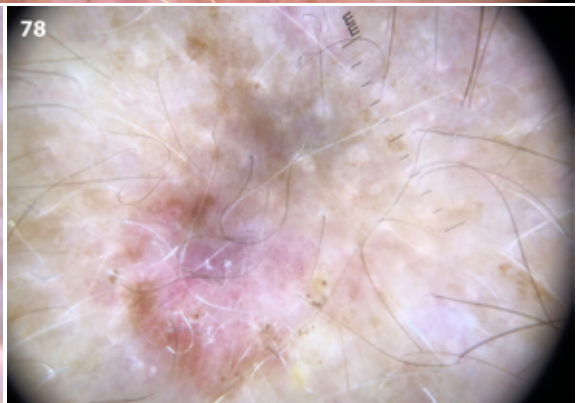
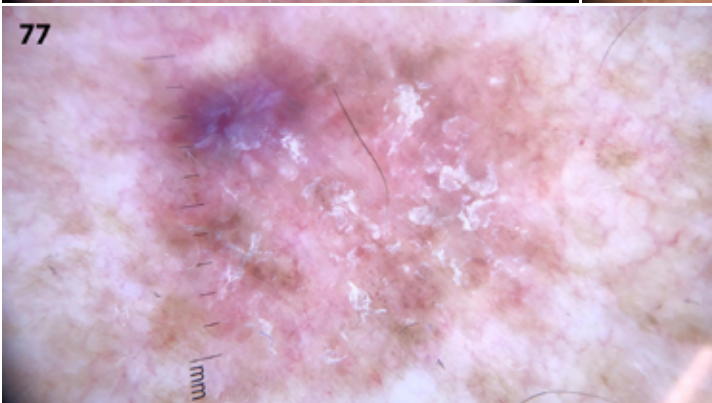
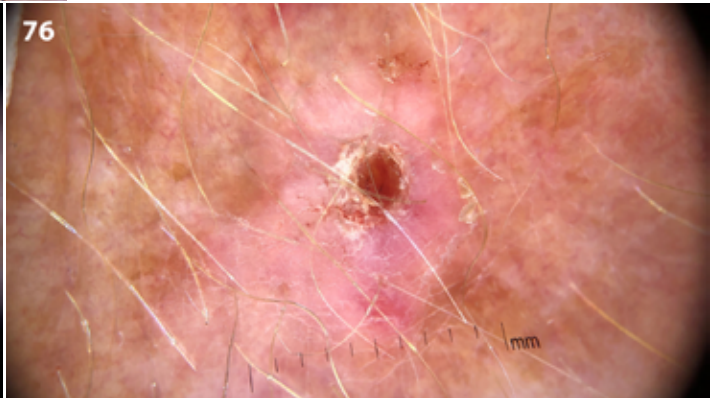
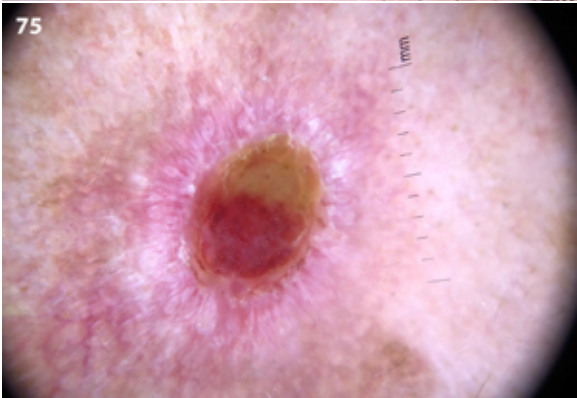
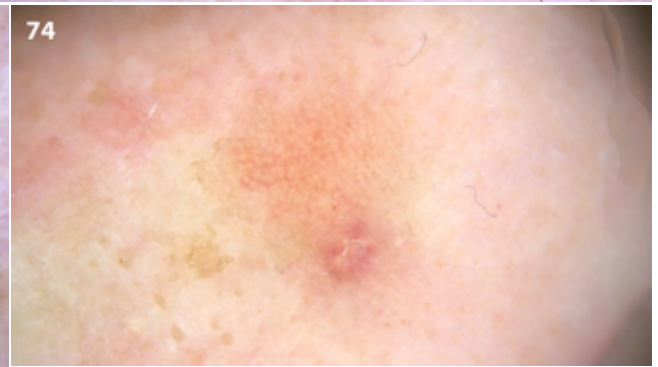
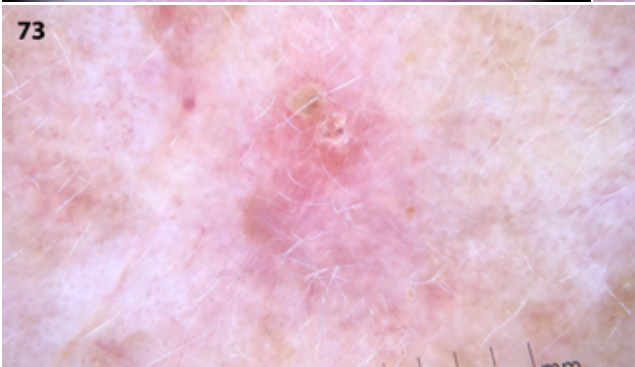
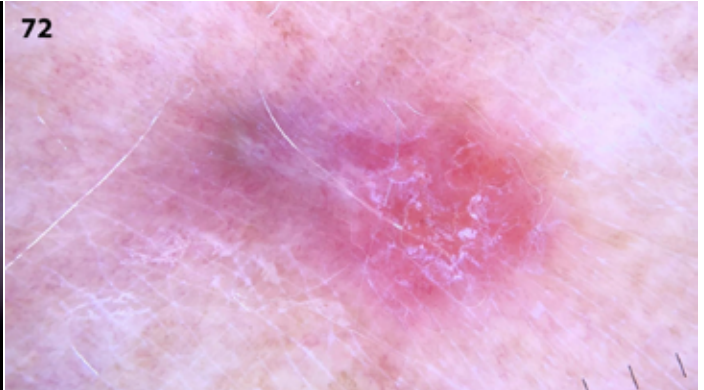
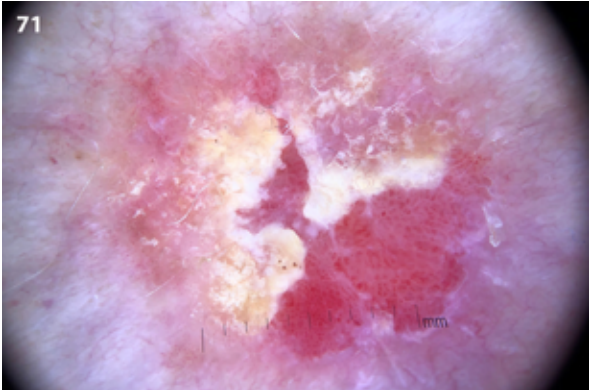
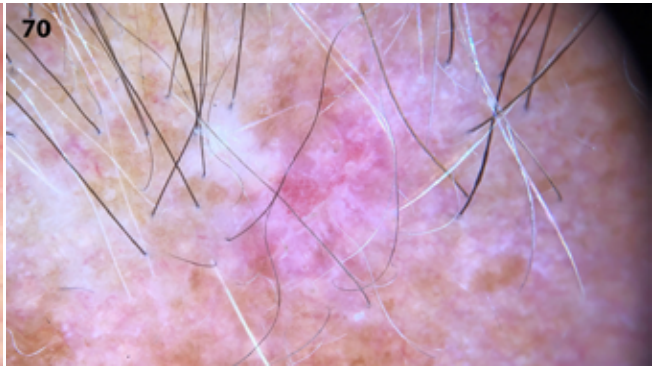
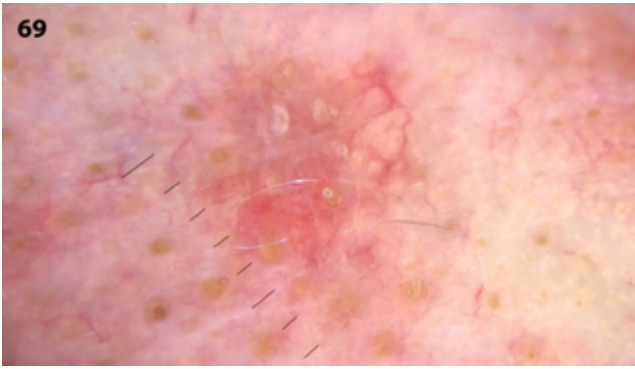


Figure S1 continues



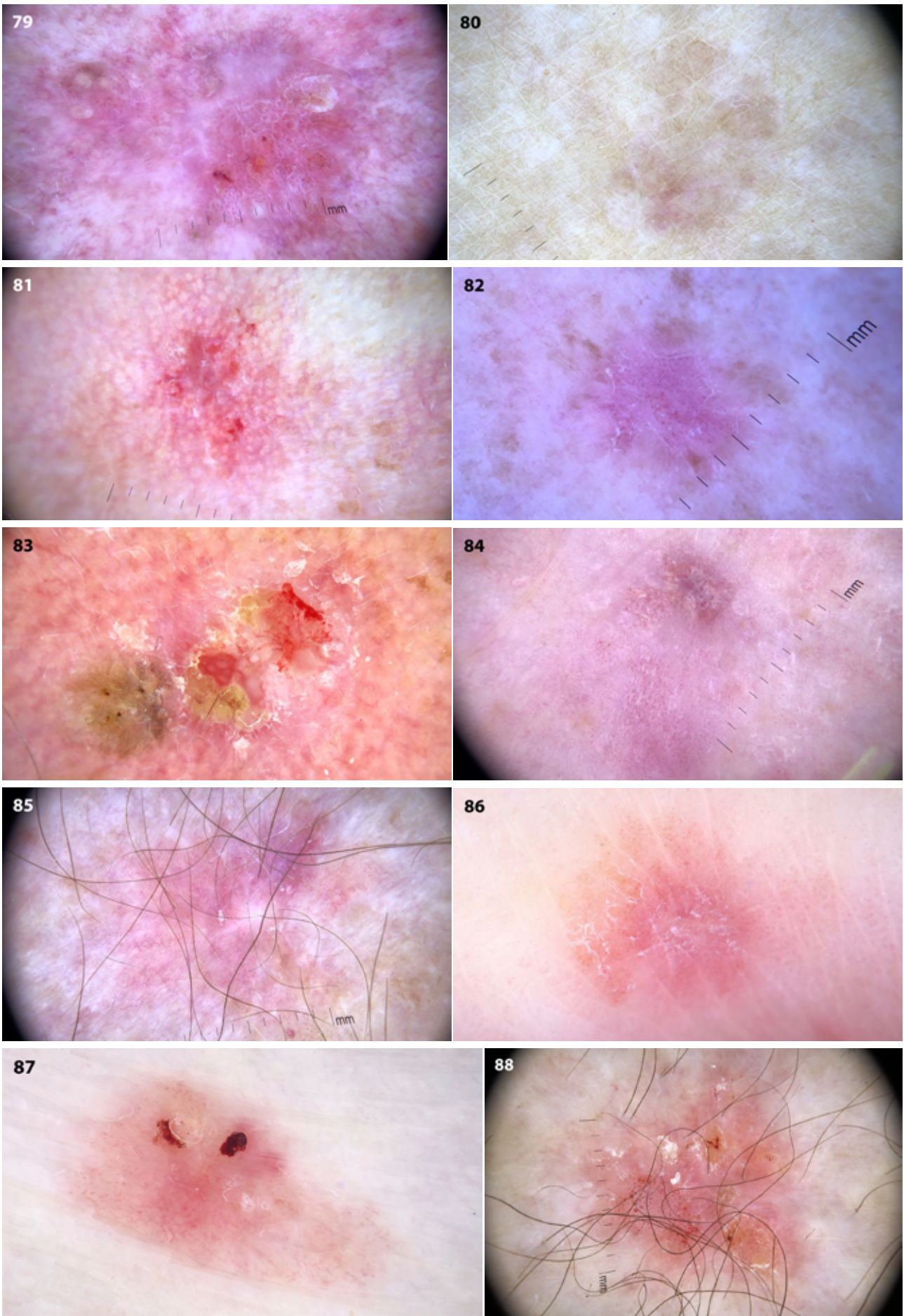
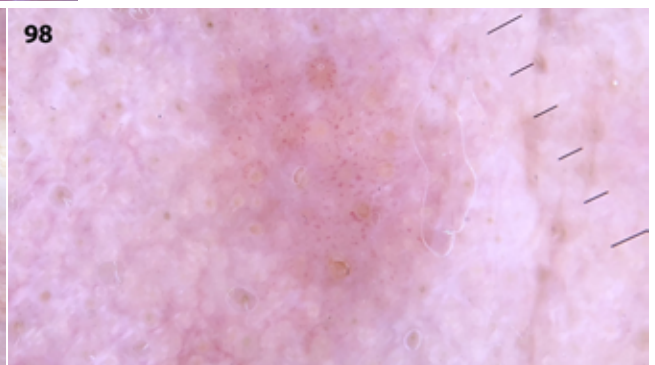
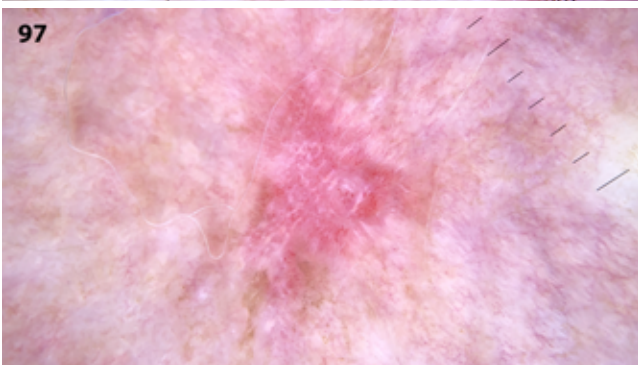
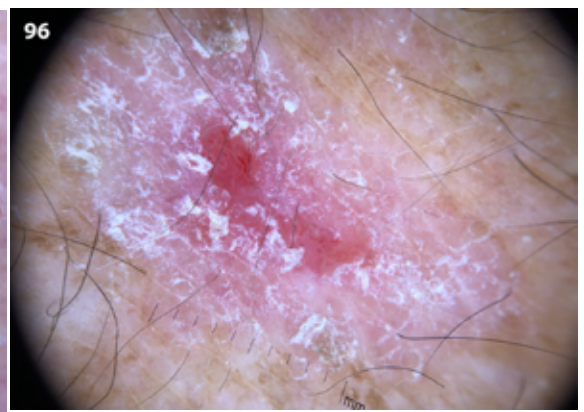
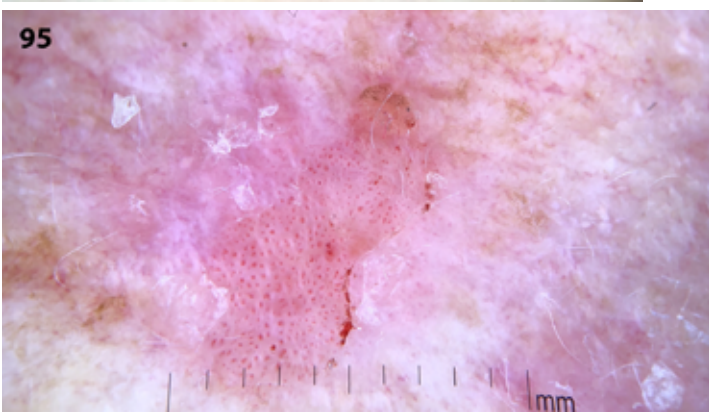
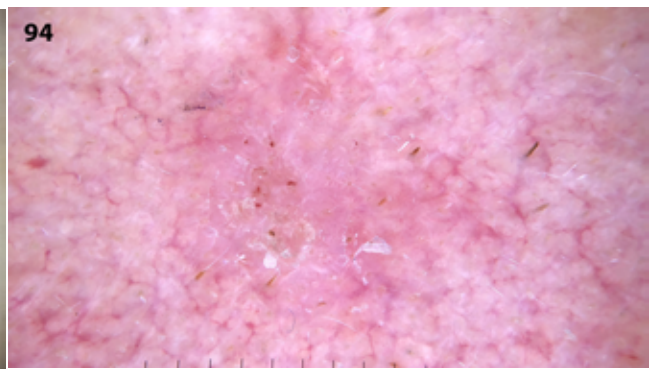
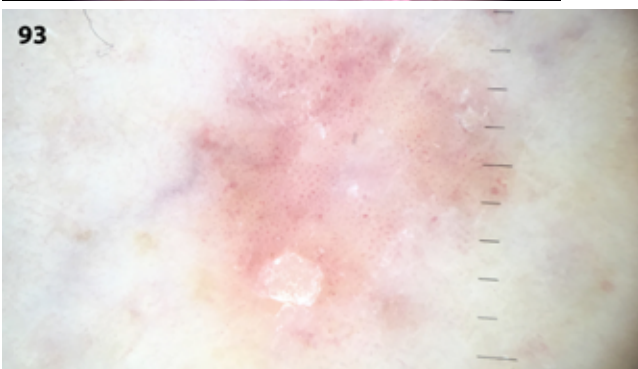
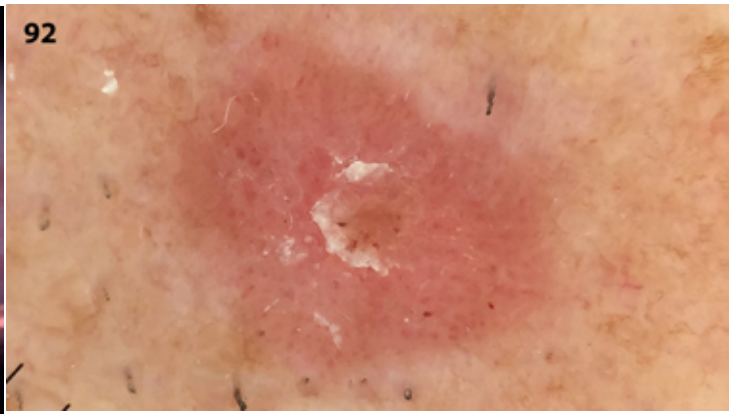
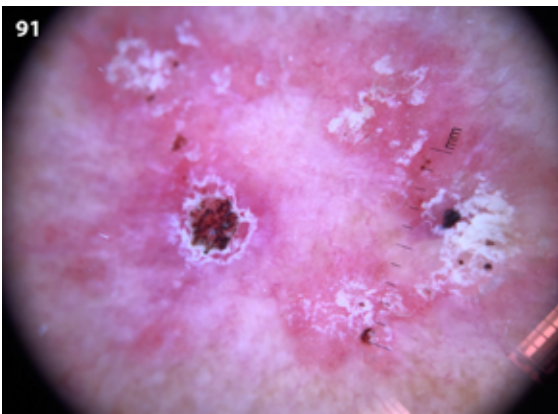
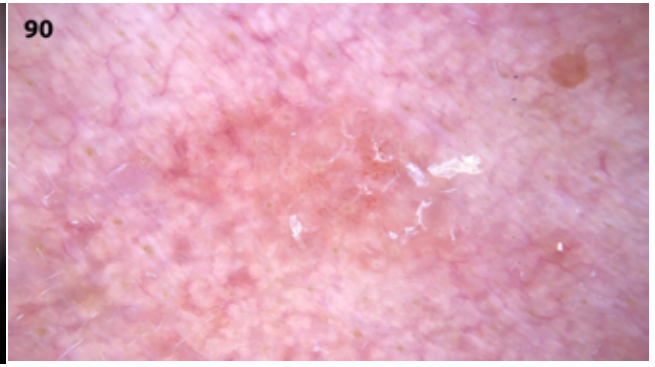
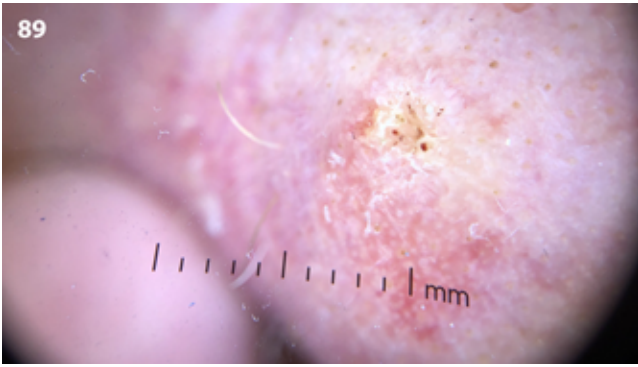
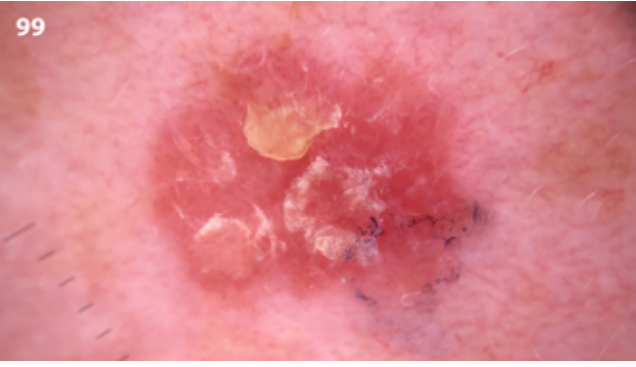


Figure S1 continues



99



100

