

Brownish-Yellow Dots as a Dermoscopic Sign of Follicular Mucinosis

Javier de la Iglesia Martin¹, Jaime Piquero-Casals²,
Angels Quera³, Daniel Morgado-Carrasco^{1,3}

1 Dermatology Department, Hospital Clínic de Barcelona, Universitat de Barcelona, Barcelona, Spain

2 Dermik, Clínica Dermatológica Multidisciplinar, Barcelona, Spain

3 Dermatology Department, Hospital de Figueres, Fundació Salut Empordà, Girona, Spain

Citation: de la Iglesia Martin J, Piquero-Casals J, Quera A, Morgado-Carrasco D. Brownish-Yellow Dots as a Dermoscopic Sign of Follicular Mucinosis *Dermatol Pract Concept*. 2023;13(3):e2023150.
DOI: <https://doi.org/10.5826/dpc.1303a150>

Accepted: January 14, 2023; **Published:** July 2023

Copyright: ©2023 de la Iglesia Martin et al. This is an open-access article distributed under the terms of the Creative Commons Attribution-NonCommercial License (BY-NC-4.0), <https://creativecommons.org/licenses/by-nc/4.0/>, which permits unrestricted noncommercial use, distribution, and reproduction in any medium, provided the original authors and source are credited.

Funding: None.

Competing interests: None.

Authorship: All authors have contributed significantly to this publication.

Corresponding author: Daniel Morgado-Carrasco, Hospital clínic de Barcelona, Villarroel 170, Barcelona (08036), Tel. (+34) 935 464 710 Fax (+34) 935 464 729 Email: morgadodaniel8@gmail.com

Case Presentation

A 40-year-old man presented with a 2-year history of well defined, erythematous and alopecic plaques, together with alopecic patches on both shins. Dermoscopy showed medium-size brownish-yellow dots, arboriform vessels and patchy homogenous ivory-white areas (Figure 1). Laboratory tests including blood count, antinuclear antibodies, Ro/La antibodies, thyroid function and serum protein electrophoresis, together with serologies for syphilis, Lyme disease, hepatitis B and C virus, and HIV, and chest X-ray were normal or negative. A punch biopsy revealed a follicular and perifollicular lymphocytic infiltrate with no cellular atypia, and deposition of an amorphous substance around follicles in the dermis. Alcian blue at pH 2.5 confirmed the presence of mucin (Figure 2). Based on clinicopathological characteristics a diagnosis of follicular mucinosis was made. Topical

corticosteroids and hydroxychloroquine 400 mg/day were started, and long-term follow-up was recommended.

Teaching Point

Follicular mucinosis is a rare inflammatory dermatosis characterized by abnormal deposition of mucin on hair follicles [1]. There are two subtypes: idiopathic and associated with cutaneous lymphomas or hematological malignancies.

The diagnosis of follicular mucinosis can be challenging. Dermoscopic features of follicular mucinosis have scarcely been described. Dermoscopy may reveal white homogenous patches surrounded by a yellow border, interfollicular red dots and the tooth paste sign¹ (white gelatinous material along hair shafts). Yamagishi et al Haga clic o pulse aquí para escribir texto. reported perifollicular medium-size brownish-yellow dots, which were also seen in

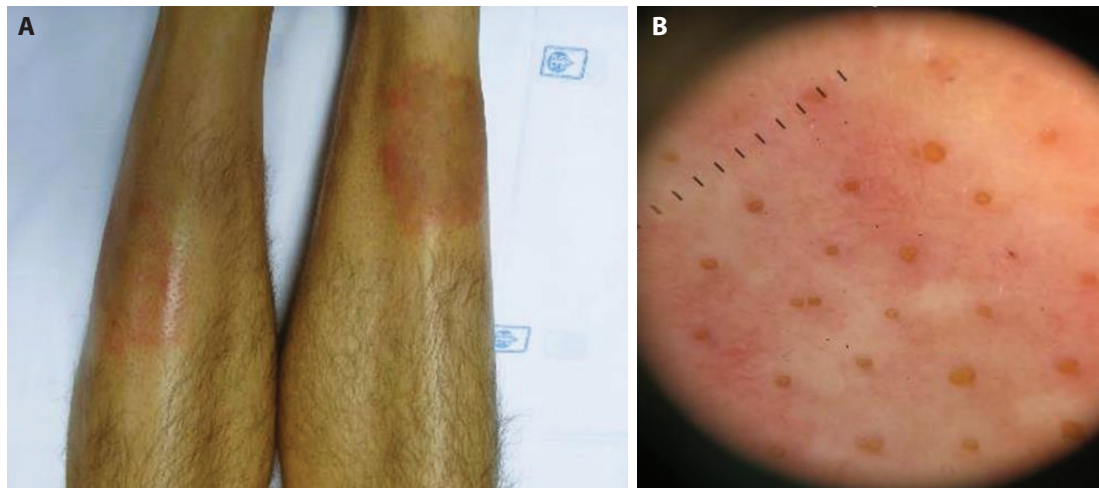


Figure 1. (A) Follicular mucinosis. Well-defined, erythematous alopecic plaques, and alopecic patches on both shins. (B) Dermoscopy reveals multiple medium-size brownish-yellow dots, and arboriform vessels. Scattered homogenous white areas can also be seen.

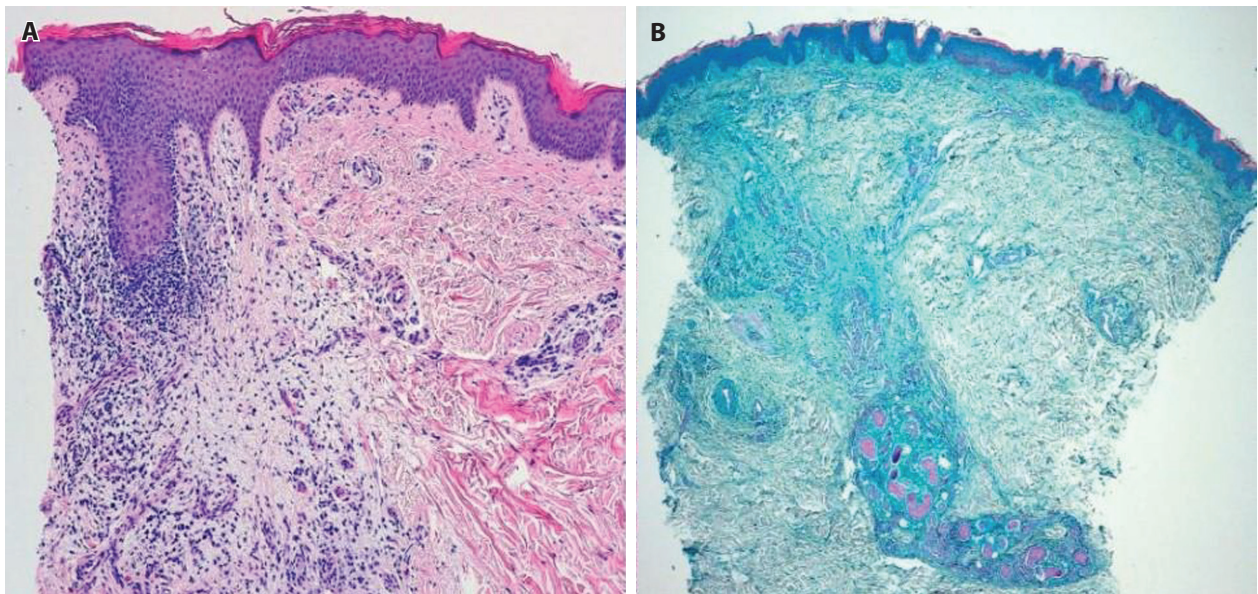


Figure 2. (A) Histopathologic picture. Lymphocytic infiltrate and amorphous substance around hair follicles. No cellular atypia was seen. (B) Alcian blue at pH 2.5 confirmed the presence of mucin.

our patient [2]. These structures can also be observed in discoid lupus erythematosus, among other dermatoses.

Dermoscopy may be helpful in the diagnosis of follicular mucinosis, and medium-size brownish-yellow dots can be a novel dermoscopic sign.

References

1. Mumford BP, Ryan A, Chong AH, Lasocki A. Follicular mucinosis with novel dermoscopic finding: the toothpaste sign. *Clin Exp Dermatol.* 2022;47(5):969-970. DOI: 10.1111/ced.15083. PMID: 34978345.
2. Yamagishi H, Ota M, Nobeyama Y, Asahina A. Case of follicular mucinosis showing brownish yellow and red dots via dermoscopy. *Clin Case Rep.* 2022;10(5). DOI: 10.1002/ccr3.5815. PMID: 35600022. PMCID: PMC9109645.