

## Dermatoscopy of Bednar Tumor: New Case and Review of Literature

Vincenzo Maione<sup>1</sup>, Giuseppe La Rosa<sup>1,2</sup>, Laura Miccio<sup>1,2</sup>, Claudia Zambelli<sup>3</sup>, Piergiacomo Calzavara-Pinton<sup>1,2</sup>

1 Division of Dermatology, ASST Spedali Civili di Brescia, Brescia, Italy

2 Division of Dermatology, Department of Clinical and Experimental Sciences, University of Brescia, Brescia, Italy

3 Division of Pathology, ASST Spedali Civili di Brescia, Brescia, Italy

**Key words:** Bednar tumor, dermoscopy, dermatofibrosarcoma, pigmented dermatofibrosarcoma

**Citation:** Maione V, La Rosa G, Miccio L, Zambelli C, Calzavara-Pinton P. Dermatoscopy of Bednar Tumor: New Case and Review of Literature. *Dermatol Pract Concept.* 2023;13(2):e2023117. DOI: <https://doi.org/10.5826/dpc.1302a117>

**Accepted:** November 23, 2023; **Published:** April 2023

**Copyright:** ©2023 Maione et al. This is an open-access article distributed under the terms of the Creative Commons Attribution-NonCommercial License (BY-NC-4.0), <https://creativecommons.org/licenses/by-nc/4.0/>, which permits unrestricted noncommercial use, distribution, and reproduction in any medium, provided the original authors and source are credited.

**Funding:** None.

**Competing Interests:** None.

**Authorship:** All authors have contributed significantly to this publication.

**Corresponding Author:** Dr. Vincenzo Maione, Division of Dermatology, Spedali Civili, Piazzale Spedali Civili 1, Brescia, Italy. Phone +39 0303995300, Fax +39 0303995015 E-mail: [maionevincenzo@gmail.com](mailto:maionevincenzo@gmail.com)

### Introduction

Bednar tumor is a rare variant of dermatofibrosarcoma. We report a new case with its dermoscopic features, comparing them with findings of literature.

### Case Presentation

A 14-year-old female patient presented because of the onset of a bluish plaque on the right forearm five months before (Figure 1A). Dermoscopy displayed blue-whitish areas with white streaks. A pigmented network was evident at the periphery of the lesion and in some areas appeared linearly stretched. Blurry branching vessels were distributed on the entire lesion (Figure 2).

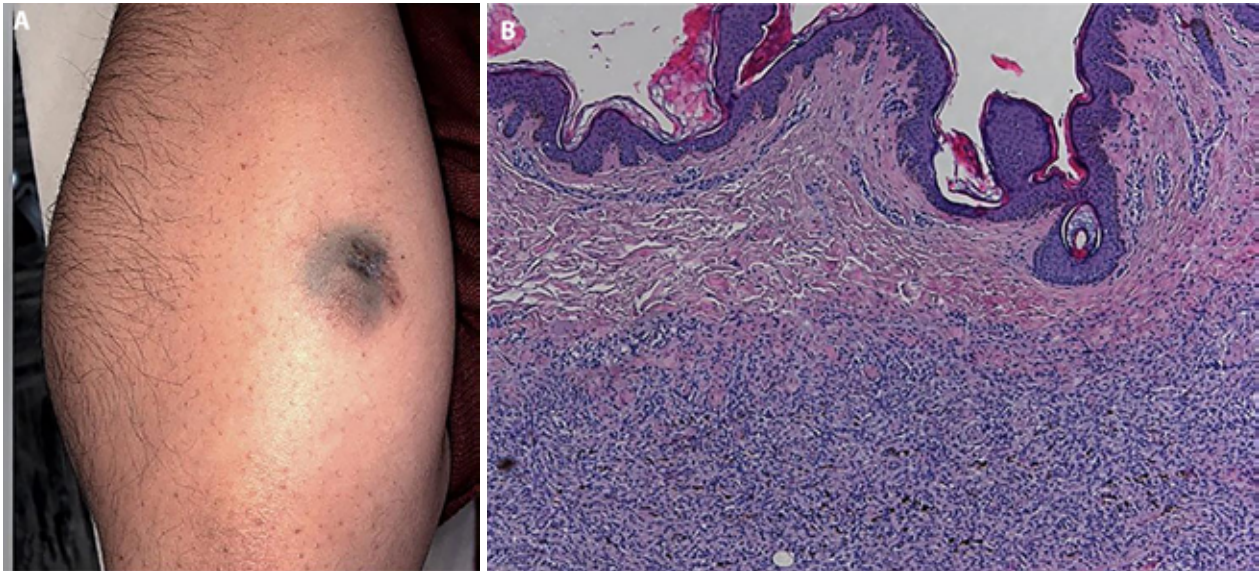
Histological exam showed a mesenchymal neoplastic proliferation of pigmented spindle cells, with a storiform pattern, interposed with scattered thin-walled vessels (Figure 1B). Immunohistochemistry was positive for CD34+ and fluorescence

in situ hybridization displayed a rearrangement of COL1A1/PDGFB genes, confirming the diagnosis of pigmented dermatofibrosarcoma protuberans. The patient underwent surgical resection with wide margins and removal of the fascia. No recurrence was detected so far.

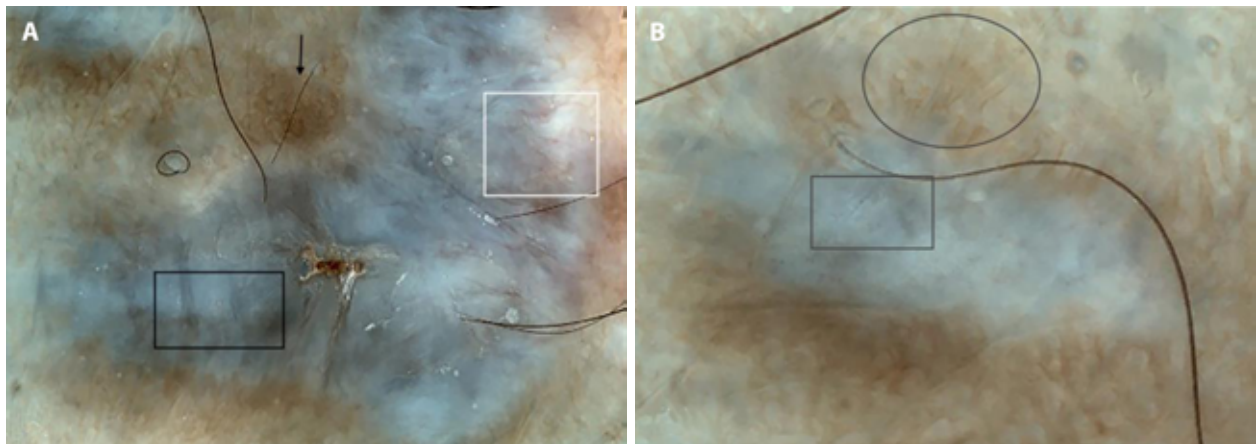
### Conclusions

Pigmented dermatofibrosarcoma protuberans (also called Bednar Tumor), accounts for less than 5% of all dermatofibrosarcoma protuberans (DFSP), and it is characterized by the presence of melanin-containing dendritic cells within the tumor [1]. Diagnosis is insidious, as it may be easily mistaken for other skin tumors, and for these reasons, dermoscopy can assist in the diagnosis.

Classic dermatofibrosarcoma displays 6 dermoscopic patterns: thin regular pigmented network, reticular vessels, structureless light-brown areas, white streaks, pink background coloration, and structureless hypopigmented



**Figure 1.** (A) Presence of bluish indurated plaque of right arm. (B) Diffuse proliferation of spindle cells in a storiform pattern. Some cells contain abundant melanin. (H&E x4).



**Figure 2.** (A,B) Diffuse white-bluish pigmentation associated to white streaks (black square). Arborizing vessels are present over the entire lesion and are not focused (white square). At periphery, a pigmented network is evident (black arrow). In some part of the lesion this network appears linearly stretched (black circle).

areas [2]. Only a few reports described the dermatoscopic features of its pigmented counterpart.

In a study of Bernard et al among 15 patients with DFSP, only one had a histological confirmed diagnosis of Bednar tumor and displayed all six dermatoscopic patterns described above [2]. Meada et al reported a case of Bednar tumor in which dermoscopy displayed only blue whitish veil [3]. The same feature was present in a case of pigmented dermatofibrosarcoma described by Ehara et al [4]. Lastly, Almeida et al described another case of Bednar tumor which showed pigmented network, whitish-blue veil, blurry branching vessels and white streaks as principal dermatoscopic patterns [5]. The pathologic features of pigmented dermatofibrosarcoma easily correlate to these aforementioned dermatoscopic findings: blue-whitish veil is due to pigmented spindle cells while white streaks are caused by altered collagen fibers. Arborizing

vessels, generally unfocused, may correlate with the depth of the tumor and its major need for vascularization.

Moreover, peripheral pigmented network may correspond to pigmented basal keratinocytes, as in dermatofibroma. In different areas this network appeared linearly stretched and this feature could be determined by changes in the rete-ridges induced by exuberant tumor growth. Besides the potential value of each single dermatoscopic criterion, the presence of all these described features could help in differentiating Bednar tumor from the other simulators as basal cell carcinoma, melanoma or hematoma. The diagnosis results more challenging in presence of bluish veil as unique dermatoscopic pattern.

We present a case of Bednar tumor and report the presence of a new dermatoscopic finding in addition to those previously reported. To confirm these assumptions further evidence is needed.

## References

1. Ishida M, Okabe H. Fibrosarcomatous pigmented dermatofibrosarcoma protuberans: A case report with review of the literature. *Oncol Lett.* 2012;4(3):390-392. DOI: 10.3892/ol.2012.765. Epub 2012 Jun 19. PMID: 23741240. PMCID: PMC3673649.
2. Bernard J, Poulalhon N, Argenziano G, Debarbieux S, Dalle S, Thomas L. Dermoscopy of dermatofibrosarcoma protuberans: a study of 15 cases. *Br J Dermatol.* 2013;169(1):85-90. DOI: 10.1111/bjd.12318. PMID: 23496114.
3. Maeda T, Watabe Y, Yanagi T, et al. Dermoscopic features of Bednar tumor: Report of a case. *J Dermatol.* 2018;45(7):e179-e180. DOI: 10.1111/1346-8138.14232. PMID: 29341231.
4. Ehara Y, Yoshida Y, Shiomi T, Yamamoto O. Pigmented Dermatofibrosarcoma Protuberans and Blue Naevi with Similar Dermoscopy: A Case Report. *Acta Derm Venereol.* 2016;96(2):272-273. DOI: 10.2340/00015555-2204. PMID: 26258458.
5. Almeida FT, Carvalho SD, Pereira T, Brito C. When a bruise gets important: Bednar tumour. *BMJ Case Rep.* 2019;12(2):e228446. DOI: 10.1136/bcr-2018-228446. PMID: 30755432. PMCID: PMC6381944.