

An Enigmatic Case of Focal Sweating: Naevus Sudoriferous

Deepak Vashisht¹, Preema Sinha¹, Parul Kamboj¹, Manoj G Madakshira²,
Kumar Alok¹, Juhi sharma¹

1 Department of Dermatology, Central Command Hospital, Lucknow, India

2 Department of Pathology, Central Command Hospital, Lucknow, India

Key words: eccrine, sudoriferous, dermoscopy, vaporimeter, histopathology

Citation: Vashisht D, Sinha P, Kamboj P, Madakshira MG, Alok K, Sharma J. An Enigmatic Case of Focal Sweating: Naevus Sudoriferous. *Dermatol Pract Concept.* 2023;13(2):e2023070. DOI: <https://doi.org/10.5826/dpc.1302a70>

Accepted: June 20, 2022; **Published:** April 2023

Copyright: ©2023 Vashisht et al. This is an open-access article distributed under the terms of the Creative Commons Attribution-NonCommercial License (BY-NC-4.0), <https://creativecommons.org/licenses/by-nc/4.0/>, which permits unrestricted noncommercial use, distribution, and reproduction in any medium, provided the original authors and source are credited.

Funding: None.

Competing Interests: None.

Authorship: All authors have contributed significantly to this publication.

Corresponding Author: Juhi Sharma, Department of Dermatology, Command Hospital, Lucknow, India 226002, Email: drjuhisharma.sharma17@gmail.com

Introduction

Nevus sudoriferous is a rare entity with only a few reports in literature [1]. These nevi usually present during childhood or adolescence as excessive sweating in a well-defined area on forehead, trunk or extremities. It is of two types ie pure eccrine nevus and eccrine angiomatous hamartoma. We report a rare case of pure eccrine nevus and discuss its histopathology, immunohistochemistry, vaporimeter, and dermoscopic findings.

Case Presentation

A 12-year-old girl presented with excessive focal sweating on distal forearm (right) of one month duration (Figure 1A). She experienced more than three episodes of hyperhidrosis per week. Sweating was not associated with rise of environmental temperature, emotional stress, or exercise. There was no history of trauma.

Examination revealed focal hyperhidrosis in a well-defined area measuring 10 × 0.5 cm on the anterolateral aspect of the distal forearm (right), it lacked hypertrichosis, comedones, nodules, plaque, or papules. Axillary, palmoplantar and forehead sweating was normal. General, physical and neurological examination was normal. Thyroid function test and vertebral column radiograph were also normal. Objective assessment of hyperhidrosis by vaporimeter (Delfin technologies Ltd) in standard room conditions at a temperature of 26°C showed sweat loss at the rate of 44 g/m²h. Dermoscopy revealed larger and clearly visible sweat pores compared to normal adjacent skin (Figure 1B). Skin biopsy showed lobular pattern of hyperplastic eccrine sweat glands (Figure 2A), immunohistochemistry with epithelial membrane antigen stain, highlighted the outer cells of the eccrine duct and luminal surface of the sweat glands suggesting naevus sudoriferous (Figure 1B). The patient was treated with intralesional injections of botulinum, which significantly improved her symptoms.

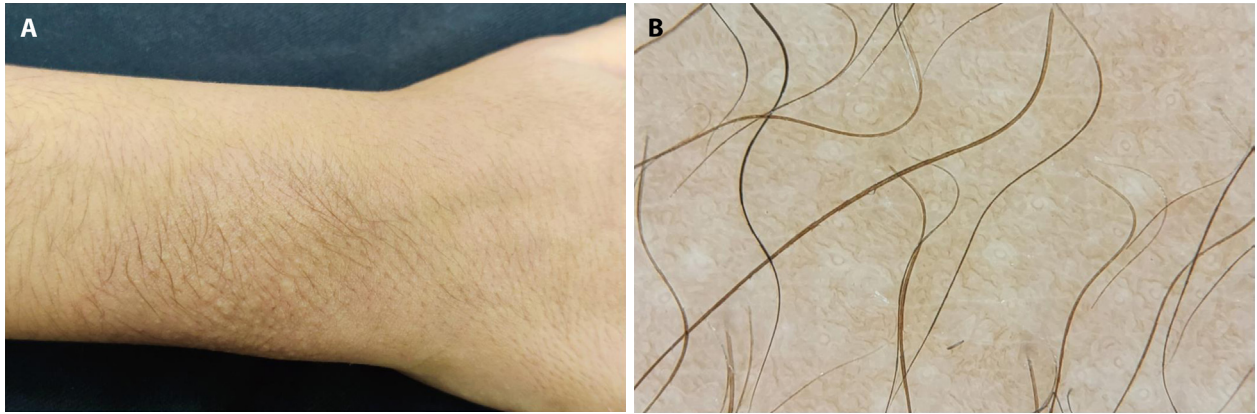


Figure 1. (A) Area over anterolateral aspect of right forearm shows excessive sweating. (B) Larger and clearly visible sweat pores (black arrows) on dermoscopy.

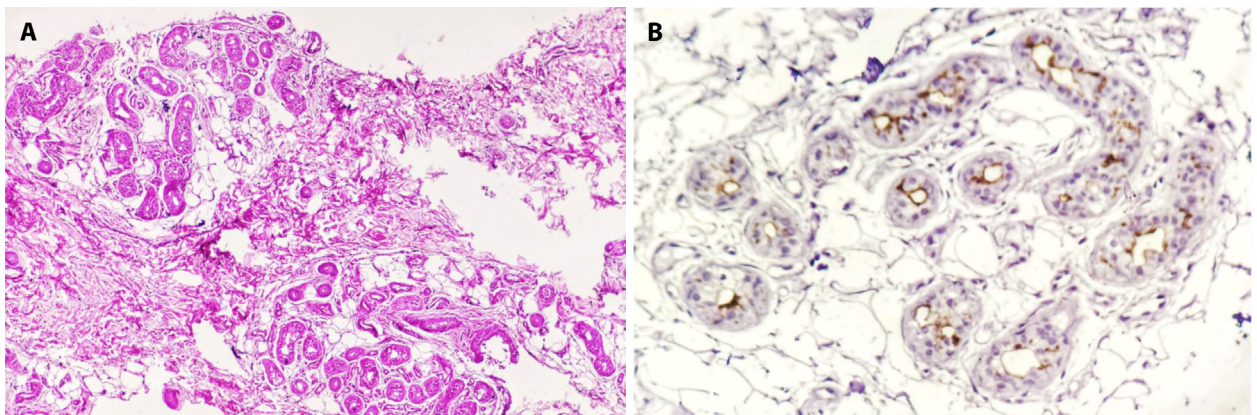


Figure 2. (A) H&E stain 100x magnification. The glands show increased number of coils indicating hyperplasia. (B) Immunohistochemistry 400x magnification with EMA highlights the luminal cells of the glands by the membranous staining pattern in the luminal aspect.

Conclusions

Hyperhidrosis is characterized by excessive sweating, and it not only adversely affects patient quality of life but also has a tremendous emotional and psychological bearing. It can either be generalized or focal. Diagnostic criteria of primary focal hyperhidrosis include either of the two: age less than 25 years, positive family history, cessation of sweating during sleep, frequency of at least one episode per week, impairment of daily activities, bilateral and relatively symmetrical sweating [2].

The vapometer is an effective non-invasive device which assist in measuring trans-epidermal water loss [3], similarly dermoscopy is also assists in assessing hyperhidrosis by ascertaining the number and activity of sweat glands.

Assessment of eccrine gland density variability not only aids in the diagnosis of sweat gland abnormality but also helps in therapeutic evaluation and monitoring [4]. Nevus sudoriferous has increased eccrine secretory and ductal elements and lacks enlargement of vascular channels seen in eccrine angiomatous hamartoma [5].

Depending on the severity, nevus sudoriferous can be managed with topical application of aluminum chloride, iontophoresis, or intralesional injections of botulinum toxin. However, the definitive treatment is surgical excision.

This case is being reported for the rarity of pure eccrine naevus, as only a few cases have been reported till date. It also highlights the role of different investigation modalities such as histopathology, immunohistochemistry, vaporimeter and dermoscopy in arriving at the correct diagnosis.

References

1. Vázquez MR, Gómez de la Fuente E, Fernández JG, Martín FJ, Estebananz JL, Moraleda FP. Eccrine naevus: case report and literature review. *Acta Derm Venereol.* 2002;82(2):154-156. DOI: 10.1080/00015550252948310. PMID: 12125955.
2. Hornberger J, Grimes K, Naumann M, et al. Recognition, diagnosis, and treatment of primary focal hyperhidrosis. *J Am Acad Dermatol.* 2004;51(2):274-286. DOI: 10.1016/j.jaad.2003.12.029. PMID: 15280848.
3. De Paepe K, Houben E, Adam R, Wiesemann F, Rogiers V. Validation of the VapoMeter, a closed unventilated chamber system to assess transepidermal water loss vs. the open chamber Tewameter. *Skin Res Technol.* 2005;11(1):61-69. DOI: 10.1111/j.1600-0846.2005.00101.x. PMID: 15691261.
4. Sonthalia S, Errichetti E, Sehgal VN. “Hidroscopy”-Suggesting Dermoscopy for expendable indications. *Skin Res Technol.* 2019;25(6):909-911. DOI: 10.1111/srt.12724. PMID: 31120561.
5. Kawaoka JC, Gray J, Schappell D, Robinson-Bostom L. Eccrine nevus. *J Am Acad Dermatol.* 2004;51(2):301-304. DOI: 10.1016/j.jaad.2003.12.030. PMID: 15280853.