

## Preliminary Dermoscopic Features of Discoid Lupus Cheilitis in Eight Patients of Skin of Color

Biswanath Behera<sup>1</sup>, Rashmi Kumari<sup>2</sup>, BH Srinivas<sup>3</sup>, Pampa Ch Toi<sup>3</sup>,  
Debasis Gochhait<sup>3</sup>, Pavithra Ayyanar<sup>4</sup>

1 Department of Dermatology, and Venereology, AIIMS, Bhubaneswar, India

2 Department of Dermatology, Venereology and Leprology, JIPMER, Puducherry, India

3 Department of Pathology, JIPMER, Puducherry, India

4 Department of Pathology, AIIMS, Bhubaneswar, India

**Key words:** cheilitis, dermoscopy, lupus, pigmentation

**Citation:** Behera B, Kumari R, Srinivas BH, Ch Toi P, Gochhait D, Ayyanar P. Preliminary Dermoscopic Features Of Discoid Lupus Cheilitis In Eight Patients Of Skin Of Color. *Dermatol Pract Concept*. 2023;13(1):e2023045. DOI: <https://doi.org/10.5826/dpc.1301a45>

**Accepted:** September 14, 2022; **Published:** January 2023

**Copyright:** ©2023 Behera et al. This is an open-access article distributed under the terms of the Creative Commons Attribution-NonCommercial License (BY-NC-4.0), <https://creativecommons.org/licenses/by-nc/4.0/>, which permits unrestricted noncommercial use, distribution, and reproduction in any medium, provided the original authors and source are credited.

**Funding:** None.

**Competing Interests:** None.

**Authorship:** All authors have contributed significantly to this publication.

**Corresponding Author:** Rashmi Kumari, M.D., Associate Professor, Dept. of Dermatology, Venereology and Leprology, JIPMER, Puducherry, Pin-605006. Phone no- 09489692199, E-mail: [rashmi.sreerag@gmail.com](mailto:rashmi.sreerag@gmail.com)

### Introduction

Discoid lupus cheilitis (DLC) is a spectrum of discoid lupus erythematosus (DLE) presentation that can occur in association with cutaneous lesions. Dermoscopic features of DLC are sparsely reported [1,2].

### Case Presentation

All eight patients in our series were female. They belonged to Fitzpatrick skin phototypes IV and V. The clinical and dermoscopic details of all the patients are mentioned in Table 1. One case tested positive for antinuclear antibody by immunofluorescence method (2+). The pathological features in all the cases were consistent with DLC. Direct immunofluorescence (single case from the lip and four patients from skin lesion) showed linear deposition of IgG, IgM, IgA, and, or C3 along the basement membrane zone.

Cheilitis results from a vast group of disorders ranging from simple lip licking to malignant neoplasms, such as squamous cell carcinoma (SCC). Morphologically DLC can be small papules, discoid plaques, or can diffusely involve either of the lips. Different morphological variations like dyspigmentation, erosion, keratotic, atrophic, and rare hypertrophic subtypes have been described. Early diagnosis is essential as it can cause significant lip disfigurement and can rarely progress to SCC [3]. The diagnosis can be challenging in the absence of other mucocutaneous lesions of DLE.

The dermoscopic features, homogenous purplish-white, ivory-white to reddish-white areas, brown to blue-gray dots, globules, and peppering, and polymorphous vascular pattern, observed by us are the direct reflection of the underlying pathology of discoid lupus (Figures 1 and 2). The white color corresponds to the hyperkeratosis with or without acanthosis, the red color to the increased vascularity, the brown to brown-gray dots and globules to melanin in the

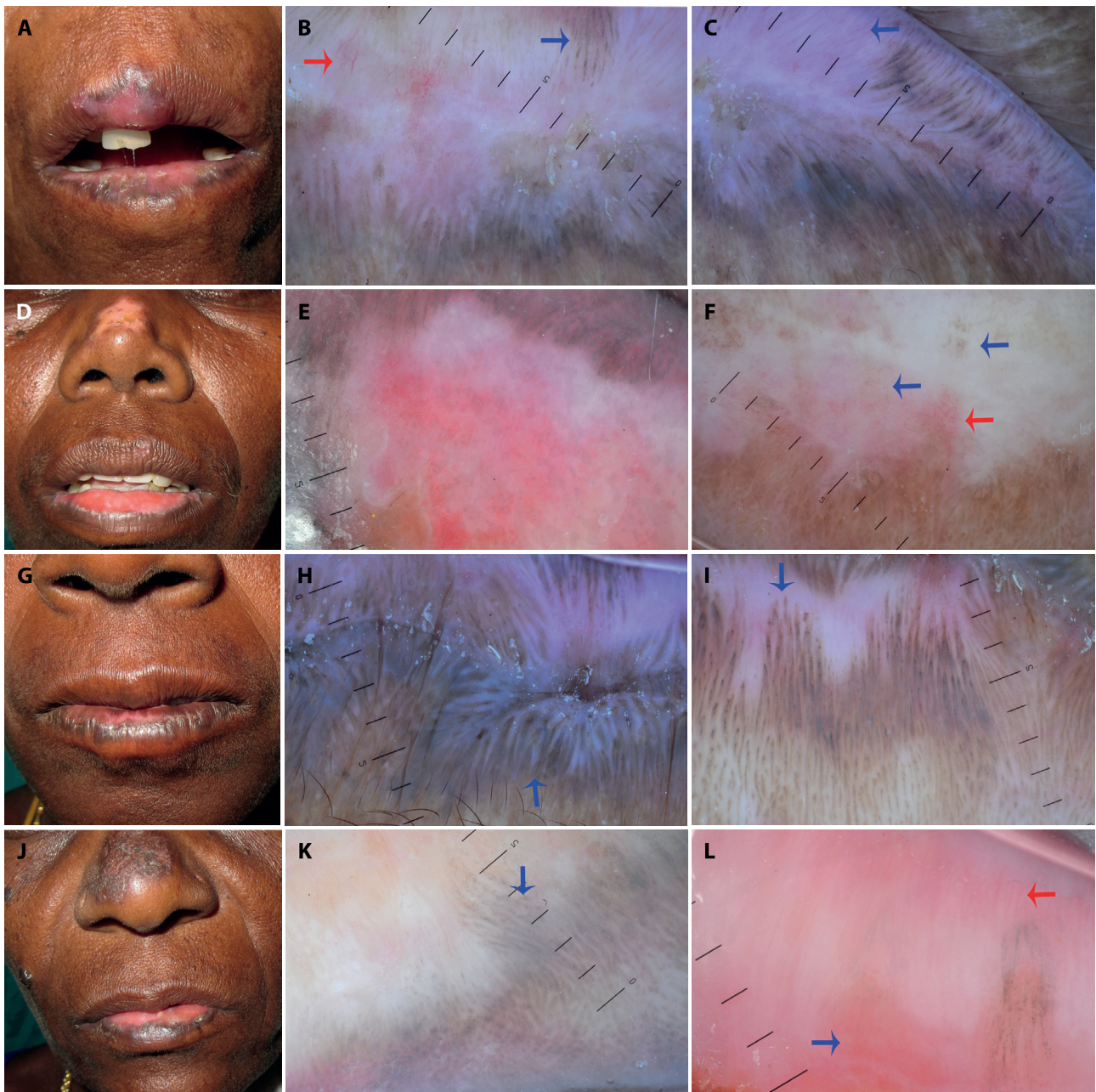
**Table 1. Clinico-demographic and dermoscopic features of eight cases of discoid lupus cheilitis.**

Parameters	Demographic, clinical and dermoscopic features (number)
Demographic characteristics	<ol style="list-style-type: none"> <li>1. Age: 29-56 years</li> <li>2. Gender: Female (8)</li> </ol>
Clinical characteristics	<ol style="list-style-type: none"> <li>1. Location of cheilitis               <ol style="list-style-type: none"> <li>i. Lower lip (7)</li> <li>ii. Both the lips (1)</li> </ol> </li> <li>2. Morphology of cheilitis               <ol style="list-style-type: none"> <li>i. Eroded plaque surrounded by brown, gray, or violaceous pigmentation with/without crusting (4)</li> <li>ii. Erythematous to violaceous scaly plaques surrounded by violaceous to brown pigmentation (2)</li> <li>iii. Atrophic plaque surrounded by gray-brown pigmentation (2)</li> </ol> </li> <li>3. Associations               <ol style="list-style-type: none"> <li>i. Cutaneous DLE (3) Verrucous DLE (1)</li> <li>ii. Eyelid DLE (1)</li> </ol> </li> </ol>
Dermoscopic characteristics	<ol style="list-style-type: none"> <li>1. Scales (7)               <ol style="list-style-type: none"> <li>i. Color                   <ul style="list-style-type: none"> <li>• White (7)</li> <li>• Yellow (1)</li> </ul> </li> <li>ii. Distribution (could not be evaluated due to the use of immersion fluid)</li> </ol> </li> <li>3. Vessels (8)               <ol style="list-style-type: none"> <li>i. Morphology                   <ul style="list-style-type: none"> <li>• Linear (8)</li> <li>• Linear curved (hairpin) (7)</li> <li>• Linear vessels with branches (2)</li> <li>• Dotted (0)</li> </ul> </li> <li>ii. Distribution                   <ul style="list-style-type: none"> <li>• Uniform (2)</li> <li>• Clustered (2)</li> <li>• Peripheral (4)</li> <li>• Reticular (0)</li> <li>• Unspecific (1)</li> </ul> </li> </ol> </li> <li>3. Follicular or eccrine findings:               Follicular plugging at the mucocutaneous junction (1)               <ol style="list-style-type: none"> <li>a. Other structures: Homogenous area                   <ol style="list-style-type: none"> <li>i. Ivory-white homogenous area (6)</li> <li>ii. Reddish-white homogenous area (5)</li> <li>iii. Purplish-white homogenous area (4)</li> <li>iv. Peripheral irregular brown-gray to blue-gray structureless area (7)</li> </ol> </li> <li>b. Dots, globules, fine and coarse peppering (8)                   <ol style="list-style-type: none"> <li>i. Color: Brown, brown-gray to blue-gray</li> <li>ii. Arrangement                       <ul style="list-style-type: none"> <li>• Clustered (6)</li> <li>• Diffuse (3)</li> </ul> </li> </ol> </li> <li>c. Lines                   <ol style="list-style-type: none"> <li>i. Brown to blue-gray radial lines (7)</li> <li>ii. Peripheral purplish-white radial striations (6)</li> </ol> </li> <li>d. Erosion (4)</li> <li>e. Crust (5)</li> <li>f. Blood spot (2)</li> </ol> </li> </ol>

DLE = discoid lupus erythematosus.

stratum corneum and/or epidermis, blue-gray dots and globules to the dermal melanin incontinence and melanophages, and the vascular structures to the dilated dermal vessels. Other features noted were erosion, scales, and crust. The

brown to blue-gray dots, globules, and peppering were distributed diffusely or in clusters. The polymorphous vascular pattern included linear, linear curved, and linear vessels with branches. The observed vessels tortuosity and the absence



**Figure 1.** (A) Erythematous scaly plaque on the lips surrounded by a violaceous rim. (B) Dermoscopy shows purplish-white to ivory-white homogenous area, blue-gray radial lines (blue arrow), and linear (red arrow) vessels. (C) Linear vessels (blue arrow). (D) Ulcerated plaque is surrounded by violaceous pigmentation. A small atrophic papule on the upper lip. (E) Dermoscopy shows reddish-white homogenous area. (F) Clustered brown dots (blue arrows) and tortuous vessels (red arrow). (G) Linear atrophic scaly plaque with peripheral violaceous pigmentation. (H) Dermoscopy shows white scales and purplish-white radial striations (blue arrow). (I) Linear brown-gray radial lines (blue arrow). (J) Ulcerate and crusted plaque. (K) Dermoscopy shows peripheral brown-gray radial lines (blue arrow). (L) Reddish-white homogenous area (blue arrow) and linear vessels (red arrow).

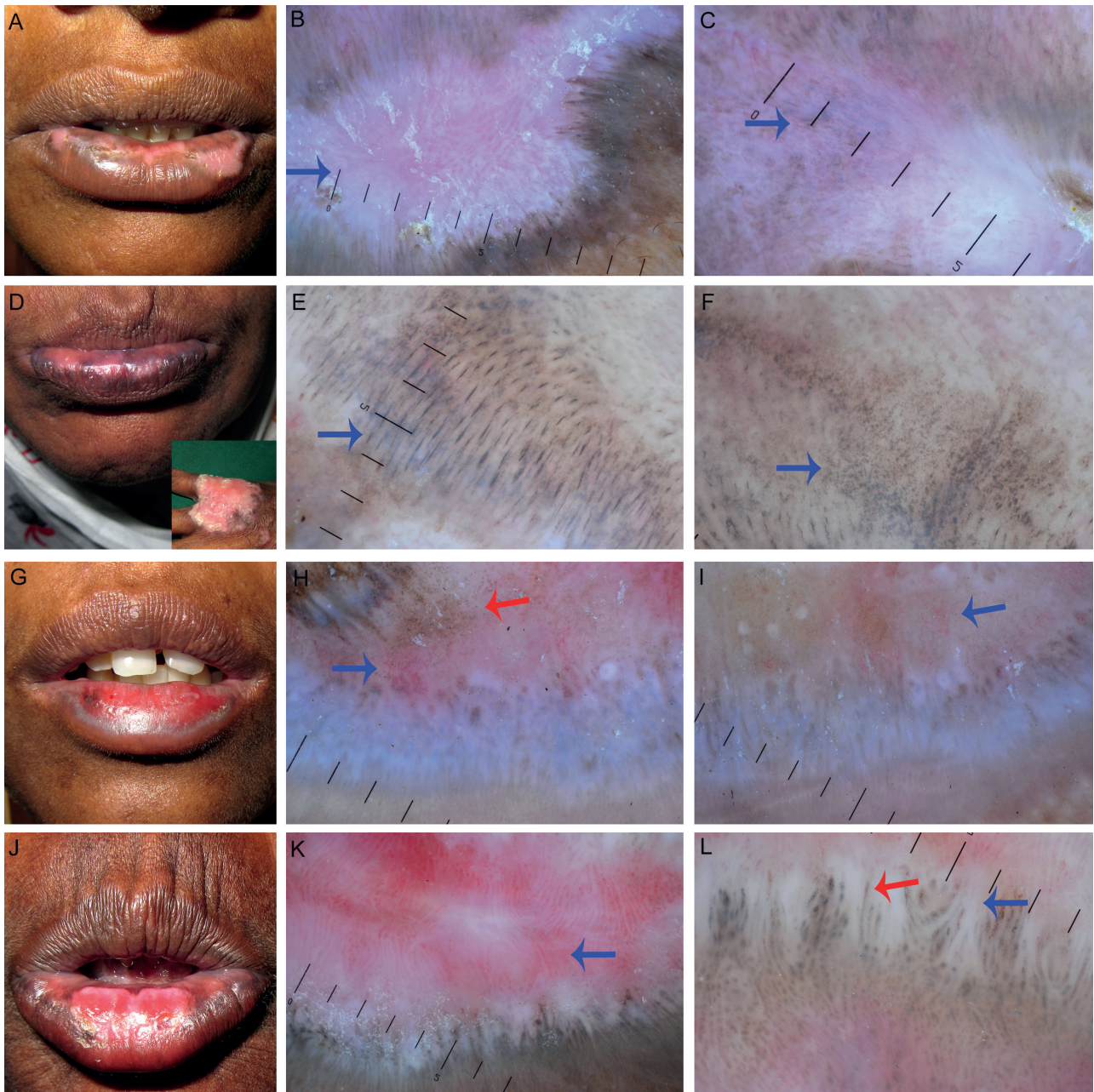
of dotted vessels were other notable features. There was no difference in dermoscopic features relating to the duration of the lesions.

Also, we observed two new dermoscopic features in DLC, brown to blue-gray radial lines and peripheral purplish-white radial striations. A case of actinic cheilitis reported having peripheral, white-colored projections. The role of dermoscopy in diagnosing DLC needs to be evaluated in larger studies [4]. In one case, we observed follicular

plugging at the mucocutaneous junction. This particular feature may favor DLC diagnosis as it is commonly observed in cutaneous DLE.

Dermoscopic features described for labial DLE are white structureless areas, scales, erosion, brown pigment spots, telangiectasia, and bleeding spots [1]. An isolated case from India had a pink background, whitish to yellowish scales, white structureless areas, blood spots, telangiectasia, irregular vessels, and peripheral grayish-black dots [2]. The dermoscopic





**Figure 2.** (A) Atrophic crusted plaque. (B) Dermoscopy shows purplish-white homogenous area (blue arrow), white scale, crust, and linear and linear curved vessels. (C) Blue-gray peppering (arrow). (D) Erythematous to violaceous plaque. Inset showing discoid lupus erythematosus plaque on the hand. (E) Dermoscopy shows blue-gray radial lines (blue arrow) over an ivory-white homogenous area. (F) Clustered to diffuse blue-gray dots and peppering over the ivory-white homogenous area. (G) Eroded plaque surrounded by a violaceous rim. (H) Dermoscopy shows purplish-white homogenous area, brown dots (red arrow) and peppering, and linear vessels (blue arrow). (I) Note the tortuous vessels (blue arrow). (J) Eroded plaque over the lower lip. (K) Dermoscopy shows reddish-white homogenous area (arrow). (L) Ivory-white (blue arrow) to reddish-white homogenous area with blue-gray radial lines (red arrow).

features described for lip lichen planus, a closest differential of DLC, are Wickham striae, ulcer, brown to blue-gray dots, globules, and peppering, scales, linear, hairpin and dotted vessels [5].

## Conclusions

In conclusion, we describe the preliminary dermoscopic features of DLC in eight patients with skin of color. The common dermoscopic features were homogenous purplish-white, ivory-white to reddish-white areas, brown to blue-gray dots, globules, and peering along with a polymorphous vascular pattern.

## References

1. Salah E. Clinical and dermoscopic spectrum of discoid lupus erythematosus: novel observations from lips and oral mucosa. *Int J Dermatol*. 2018 ; 57(7):830-836. doi: 10.1111/ijd.14015. Epub 2018 Apr 27. PMID: 29700807.
2. Chandela M, Misri R, Jakhar D. Mucoscopy of discoid lupus erythematosus on lower lip. *Indian Dermatol Online J*. 2020;11(2):296-297. DOI: 10.4103/idoj.IDOJ\_348\_18. PMID: 32478010. PMCID: PMC7247652.
3. Nico MM, Bologna SB, Lourenço SV. The lip in lupus erythematosus. *Clin Exp Dermatol*. 2014;39(5):563-569. DOI: 10.1111/ced.12368. PMID: 24934909.
4. Ito T, Natsuga K, Tanimura S, Aoyagi S, Shimizu H. Dermoscopic features of plasma cell cheilitis and actinic cheilitis. *Acta Derm Venereol*. 2014; 94(5):593-594. DOI: 10.2340/00015555-1795. PMID: 24474043.
5. Neema S, Sandhu S, Kashif AW, Sinha P, Kothari R, Radhakrishnan S. Dermoscopy of lip lichen planus-a descriptive study. *Dermatol Pract Concept*. 2020;10(4):e2020076. DOI: 10.5826/dpc.1004a76. PMID: 33150022. PMCID: PMC7588155.