

Lichen Striatus Post-COVID-19 Infection: Clinical and Dermoscopic Presentations

Filippo Chersi¹, Claudio Conforti¹, Iris Zalaudek¹, Nicola di Meo¹

¹ Dermatology Clinic of Trieste, Maggiore Hospital, University of Trieste, Trieste, Italy

Key words: Lichen striatus, COVID-19, infection, rash

Citation: Chersi F, Conforti C, Zalaudek I, di Meo N. Lichen Striatus Post-COVID-19 Infection: Clinical and Dermoscopic Presentations. *Dermatol Pract Concept.* 2023;13(1):e2023006. DOI: <https://doi.org/10.5826/dpc.1301a6>

Accepted: April 23, 2022; **Published:** January 2023

Copyright: ©2023 Chersi et al. This is an open-access article distributed under the terms of the Creative Commons Attribution-NonCommercial License (BY-NC-4.0), <https://creativecommons.org/licenses/by-nc/4.0/>, which permits unrestricted noncommercial use, distribution, and reproduction in any medium, provided the original authors and source are credited.

Funding: None.

Competing Interests: None.

Authorship: All authors have contributed significantly to this publication.

Corresponding Author: Claudio Conforti, MD, Dermatology Clinic of Trieste, Maggiore Hospital, University of Trieste, Trieste, Italy. Phone: +390403992056 E-mail: claudioconforti@yahoo.com

Case Presentation

A 24-year-old female with classic symptoms for COVID-19 underwent a rhino-pharyngeal swab test in October 2020 that confirmed the infection. She had been previously vaccinated with two Pfizer vaccine doses in July. Nine days after the positive rhino-pharyngeal swab test, the patient came in consultation with small, 1-2 mm elevated pinkish papules that joined together in a slightly scaly, irregular, linear band of about 20 cm following Blaschko lines on the medial portion of the left leg (Figure 1, A and B). The patient reported that the rash had appeared 2 days after COVID-19 symptoms started and that it caused her moderate pruritus. Dermoscopy showed a slight erythematous pinkish background and confluent areas of telangiectatic vessels, ruling out other diseases (eg ILVEN, linear psoriasis or linear Darier disease) (Figure 1, C and D). A 4-mm punch confirmed the clinical suspicion of LS. LS has a self-limiting nature, with an expected complete

recovery. However, because this patient sought treatment, a short course of topical steroids together with antihistamines were prescribed to treat the itch and dryness of the skin. After 6 weeks the patient had no more signs of active disease, and no post-inflammatory hypopigmentation was observed. Usually relapses of this condition are uncommon.

Teaching Point

Few papers have reported LS after COVID-19 vaccination [1], but this case shows that also COVID-19 infection could be a trigger, although pathophysiological mechanisms and causes underlying this condition are still not completely understood.

Being a benign self-limiting condition, usually no treatment is required, although low doses of systemic corticosteroids or topical corticosteroids can contribute to provide some benefits in symptomatic patients [2].

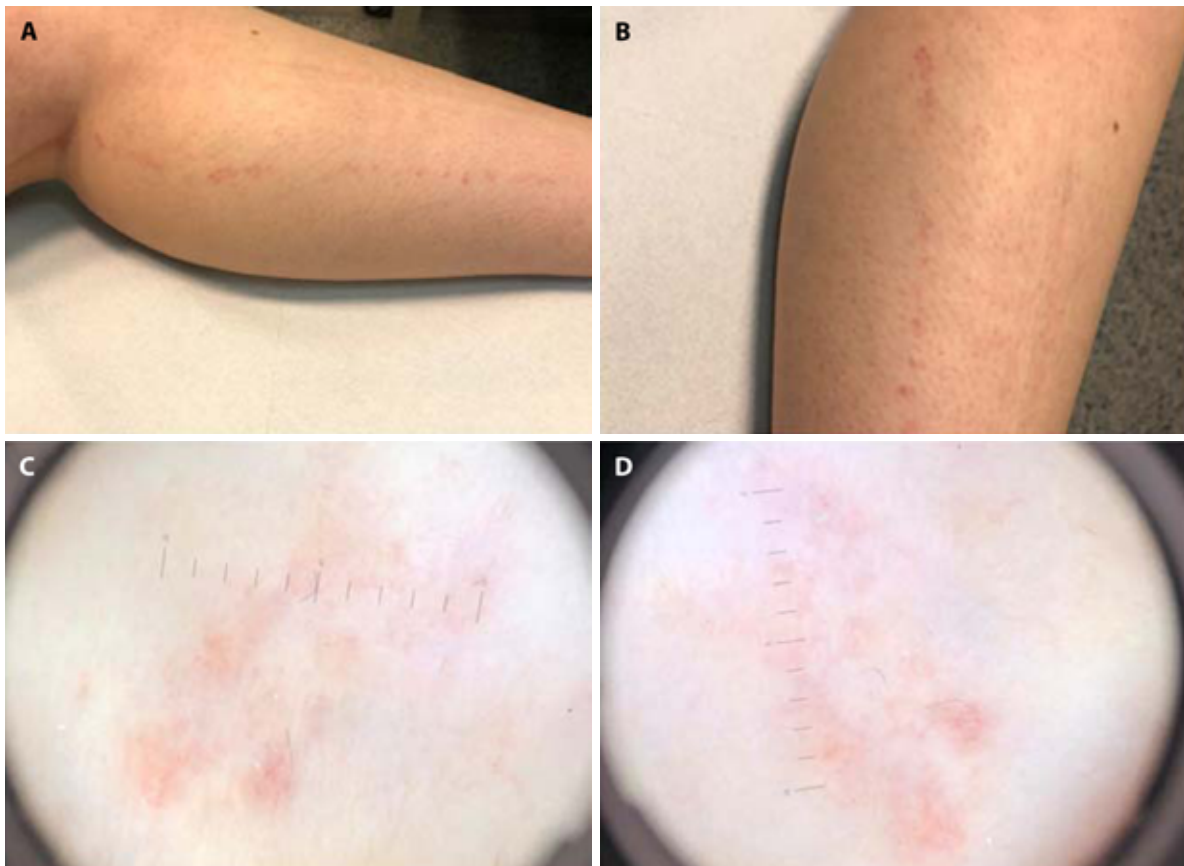


Figure 1. (A,B) Clinical presentation of lichen striatus post-COVID-19 infection: elevated pinkish papules of 1-2 mm joining together in a slightly scaly, irregular, linear band that follows the Blaschko lines on the medial portion of the left leg. (C,D) Dermoscopy shows a slight erythematous pinkish background with confluent areas of telangiectatic vessels.

References

1. Conforti C, Dianzani C, Agozzino M, et al. Cutaneous Manifestations in Confirmed COVID-19 Patients: A Systematic Review. *Biology (Basel)*. 2020;9(12):449. DOI:10.3390/biology9120449. PMID: 33291502. PMCID: PMC7762103.
2. Charifa A, Jamil RT, Ramphul K. Lichen Striatus. In: *StatPearls*. Treasure Island (FL): StatPearls Publishing; October 12, 2021.