

## Iridescent Changes Observed During Dynamic Cross-polarized Dermoscopy

John Paoli<sup>1,2</sup>, Lykke Barck<sup>1,2</sup>, Eva Johansson Backman<sup>1,2</sup>, Ashfaq Marghoob<sup>3</sup>, Sam Polesie<sup>1,2</sup>

1 Department of Dermatology and Venereology, Institute of Clinical Sciences, Sahlgrenska Academy, University of Gothenburg, Gothenburg, Sweden

2 Region Västra Götaland, Sahlgrenska University Hospital, Department of Dermatology and Venereology, Gothenburg, Sweden

3 Department of Dermatology, Memorial Sloan Kettering Cancer Center, New York, NY, USA

**Citation:** Paoli J, Barck L, Backman EJ, Marghoob A, Polesie S. Iridescent changes observed during dynamic cross-polarized dermoscopy. *Dermatol Pract Concept*. 2022;12(3):e2022119. DOI: <https://doi.org/10.5826/dpc.1203a119>

**Accepted:** November 24, 2021; **Published:** July 2022

**Copyright:** ©2022 Paoli et al. This is an open-access article distributed under the terms of the Creative Commons Attribution-NonCommercial License (BY-NC-4.0), <https://creativecommons.org/licenses/by-nc/4.0/>, which permits unrestricted noncommercial use, distribution, and reproduction in any medium, provided the original authors and source are credited.

**Funding:** None.

**Competing interests:** None.

**Authorship:** All authors have contributed significantly to this publication

**Corresponding author:** John Paoli, M.D., Ph.D, Department of Dermatology and Venereology, Sahlgrenska University Hospital, Institute of Clinical Sciences, Sahlgrenska Academy, University of Gothenburg, Gröna Stråket 16, 413 45, Gothenburg, Sweden Tel: +46(0) 730 40 40 44, E-mail: [john.paoli@gu.se](mailto:john.paoli@gu.se)

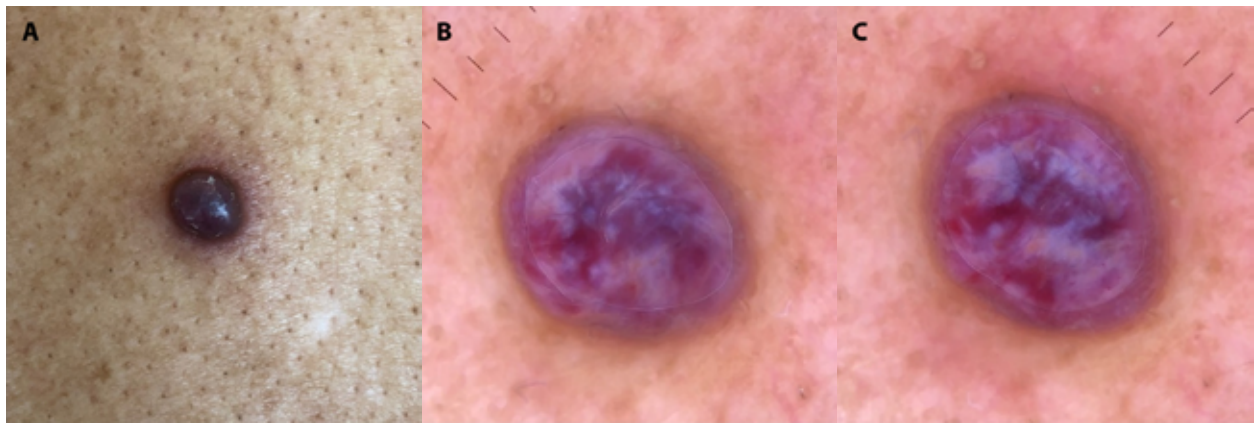
### Case Presentation

A 60-year-old male with skin phototype IV from Africa and a history of Kaposi sarcoma on his foot presented with a rapidly growing, 6.5-mm, bluish-purple nodule on his back. Cross-polarized dermoscopy using a DermLite DL4 (3Gen) coupled with an iPhone XS Max (Apple) revealed a ‘rainbow pattern’ on a structureless red background. By rotating the dermoscope without moving the smartphone during imaging, also known as dynamic cross-polarized dermoscopy, the color distribution within the rainbow pattern changed substantially (Figure 1, Supplementary Video 1). The lesion was excised and histopathologically confirmed as Kaposi sarcoma.

### Teaching point

The metaphoric term ‘rainbow pattern’ is used to describe polychromatic structureless areas only seen with polarized

dermoscopy. It has been described in several different skin tumors (eg Kaposi sarcoma, hemosiderotic dermatofibroma, angiokeratoma, aneurysmal atypical fibroxanthoma, melanoma and basal cell carcinoma) and other skin conditions (eg stasis dermatitis, lichen planus and scars) [1]. It is surmised that polarized light passing through slits created by parallelly aligned collagen bundles or vessels may cause the light to separate into different wavelengths [2]. Although the exact structures that actually cause the optical interference are unknown, the observed phenomenon is called iridescence. By applying dynamic cross-polarized dermoscopy, we demonstrate that the iridescence changes with the angle of polarization. This angular dependence of cross-polarized light has also been demonstrated previously by Marghoob et al on shiny white lines, which are only visible with the dermoscope positioned at specific angles.



**Figure 1.** (A) Clinical presentation of a case of Kaposi sarcoma. (B) Iridescence or ‘rainbow pattern’ observed during cross-polarized dermoscopy at a specific angle. (C) Modified iridescence shown after rotating the dermoscope 90°.

## References

1. Elmas OF, Mayisoglu H, Celik M, Kilitci A, Akdeniz N. Dermoscopic rainbow pattern: A strong clue to malignancy or just a light show? *North Clin Istanbul*. 2020;7(5):494–498. DOI: 10.14744/nci.2020.32656. PMID: 33163886. PMCID: PMC7603844.
2. Draghici C, Vajaitu C, Solomon I, Voiculescu VM, Popa MI, Lupu M. The Dermoscopic Rainbow Pattern - A Review of the Literature. *Acta Dermatovenerol Croat*. 2019;27(2):111–115. PMID: 31351506.

## Supplementary Video Legend

**Supplementary Video 1.** The iridescence or ‘rainbow pattern’ changes substantially while rotating the dermoscope relative to the smartphone camera (dynamic cross-polarized dermoscopy), thus demonstrating the angular dependence of polarization.