

Subungual Eccrine Angiomatous Hamartoma: Description of a Novel Dermoscopic Feature

Takahiro Mizuta¹, Nobuo Isono², Miyuki Kato¹

¹ Department of Dermatology, Tokyo Metropolitan Tama Medical Center, Fuchu-shi, Tokyo, Japan

² Department of Plastic and Surgery, Tokyo Metropolitan Tama Medical Center, Fuchu-shi, Tokyo, Japan

Citation: Mizuta T, Isono N, Kato M. Subungual Eccrine Angiomatous Hamartoma: Description of a Novel Dermoscopic Feature. *Dermatol Pract Concept.* 2022;12(4):e2022161. DOI: <https://doi.org/10.5826/dpc.1204a161>

Accepted: January 31, 2022; **Published:** October 2022

Copyright: ©2022 Mizuta al. This is an open-access article distributed under the terms of the Creative Commons Attribution-NonCommercial License (BY-NC-4.0), <https://creativecommons.org/licenses/by-nc/4.0/>, which permits unrestricted noncommercial use, distribution, and reproduction in any medium, provided the original authors and source are credited.

Funding: None.

Competing interests: None.

Authorship: All authors have contributed significantly to this publication.

Corresponding author: Takahiro Mizuta, MD, Tokyo Metropolitan Tama Medical Center, 2-8-29 Musashidai, Fuchu-shi, Tokyo 183-8524, Japan. Phone: +81-42-323-5111, Fax: +81-42-312-9156 E-mail: t.miz.cof.lif2120@gmail.com

Case presentation

A 45-year-old woman presented with a 2-month history of progressive tenderness at the tip of the left first toenail. Clinical examination showed no gross abnormalities within and beneath the nail plate. Nail plate dermoscopy revealed longitudinal yellowish-brown to yellowish-red areas with no remarkable changes in the nail plate, lunula, or proximal nail fold (Figure 1A). Histologic examination showed increased number of eccrine glands with irregular, dilated blood vessels

(Figures 1, B and C), consistent with the diagnosis of eccrine angiomatous hamartoma (EAH).

Teaching Point

EAH is a rare, benign combined eccrine and vascular malformation located mainly on the limbs, rarely in sub-ungual areas. To our knowledge, this is the first report on nail plate dermoscopic descriptions of EAH. The presence of yellowish-brown to yellowish-red areas may reflect the

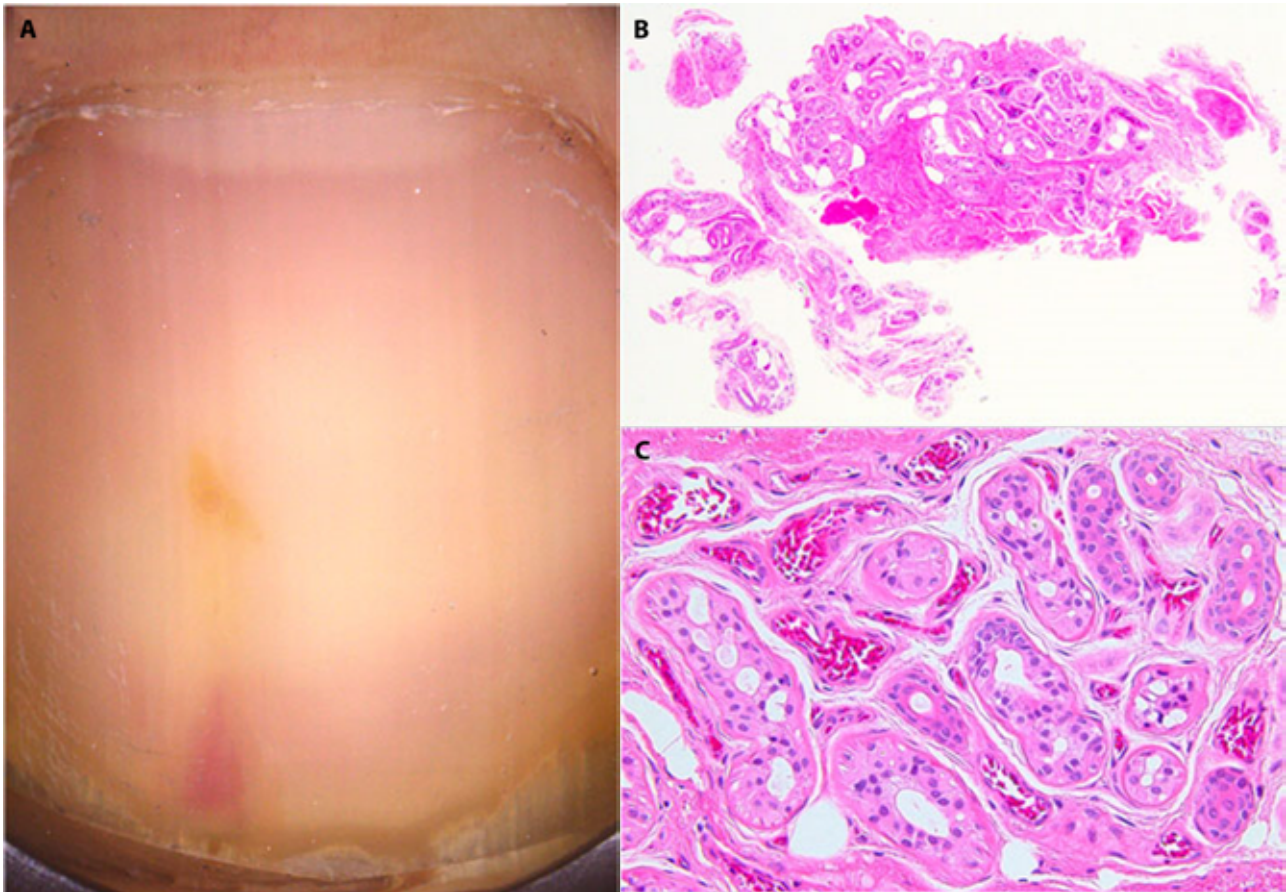


Figure 1. (A) Nail plate dermoscopy revealed yellowish-brown to yellowish-red areas, which are arrayed longitudinally under the nail plate. (B, C) Histopathology showed the hamartomatous presentation of the lobules of the eccrine glands accompanied by abnormally dilated vessels. (H&E stain; original magnification: B, $\times 4$; C, $\times 20$.)

numerous dilated eccrine glands and clusters of dilated capillaries among and around the eccrine glands, which could be helpful in its diagnosis [1,2].

Acknowledgments: We thank Editage (www.editage.com) for English language editing.

References

1. García García SC, Saeb Lima M, Villarreal Martínez A, et al. Dermoscopy of eccrine angiomatous hamartoma: The popcorn pattern. *JAAD Case Rep.* 2018;4(2):165–167. DOI: 10.1016/J.JDCR.2017.08.014. PMID: 29387774.
2. Kelati A, Chiaverini C, Giacchero D, Ilie M, Lacour JP, Bahadoran P. Dermoscopy of eccrine angiomatous hamartoma: The spitzoid pattern. *JAAD Case Rep.* 2018;4(8):835–836. DOI: 10.1016/J.JDCR.2018.06.026. PMID: 30238051.