

# IgA pemphigus showing IgA antibodies to desmoglein 1 and 3

Salama Hegazy<sup>1</sup>, Sana Bouchouicha<sup>1</sup>, Aida Khaled<sup>1</sup>, Lilia Laadher<sup>2</sup>, Maryem Kallel Sellami<sup>2</sup>,  
Faten Zeglaoui<sup>1</sup>

<sup>1</sup> Department of Dermatology, Charles Nicolle Hospital, Tunis, Tunisia

<sup>2</sup> Department of Immunology, Rabta Hospital, Tunis, Tunisia

**Key words:** pemphigus, IgA pemphigus, desmoglein

**Citation:** Hegazy S, Bouchouicha S, Khaled A, Laadher L, Kallel Sellami M, Zeglaoui F. IgA pemphigus showing IgA antibodies to desmoglein 1 and 3. *Dermatol Pract Concept* 2016;6(4):7. doi: 10.5826/dpc.0604a07

**Received:** August 20, 2016; **Accepted:** August 24, 2016; **Published:** October 31, 2016

**Copyright:** ©2016 Hegazy et al. This is an open-access article distributed under the terms of the Creative Commons Attribution License, which permits unrestricted use, distribution, and reproduction in any medium, provided the original author and source are credited.

**Funding:** None.

**Competing interests:** The authors have no conflicts of interest to disclose.

All authors have contributed significantly to this publication.

**Corresponding author:** Salama Hegazy, MD. Email: dr\_salama\_86@hotmail.com

**ABSTRACT** **Background:** IgA pemphigus is a rare autoimmune vesiculo-pustular skin disease. Only approximately 70 cases have been reported to date. We report a case of IgA pemphigus with IgA antibodies to desmoglein 1 (Dsg1) and desmoglein 3 (Dsg3).

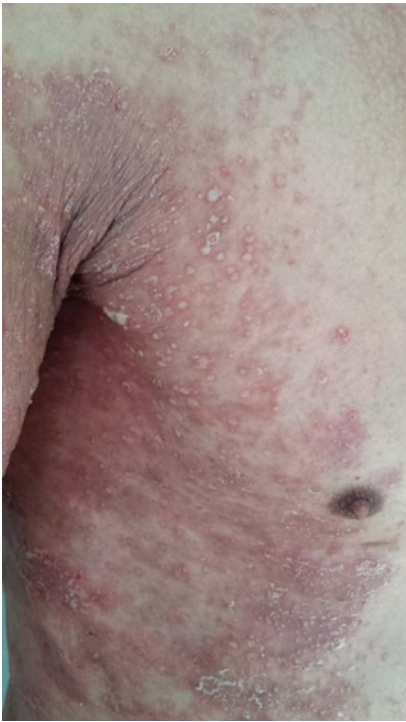**Case report:** We report the case of an 60-year-old man with intraepidermal neutrophilic IgA pemphigus with IgA antibodies to Dsg1 and Dsg3. Histologic examination revealed subcorneal neutrophilic pustules with few acantholytic cells. The disease was not effectively controlled by conventional therapeutic regimens (colchicine, dapsone). Systemic treatment with isotretinoin 25 mg/d and prednisone 20 mg/d achieved only a slight effect after six months.

**Conclusions:** Our case confirmed the recalcitrant nature of IgA pemphigus in response to distinct therapies, indicating that further research focusing on therapeutic approaches for this type of pemphigus is needed. Physicians should keep IgA pemphigus in mind when approaching patients with bullous eruption.

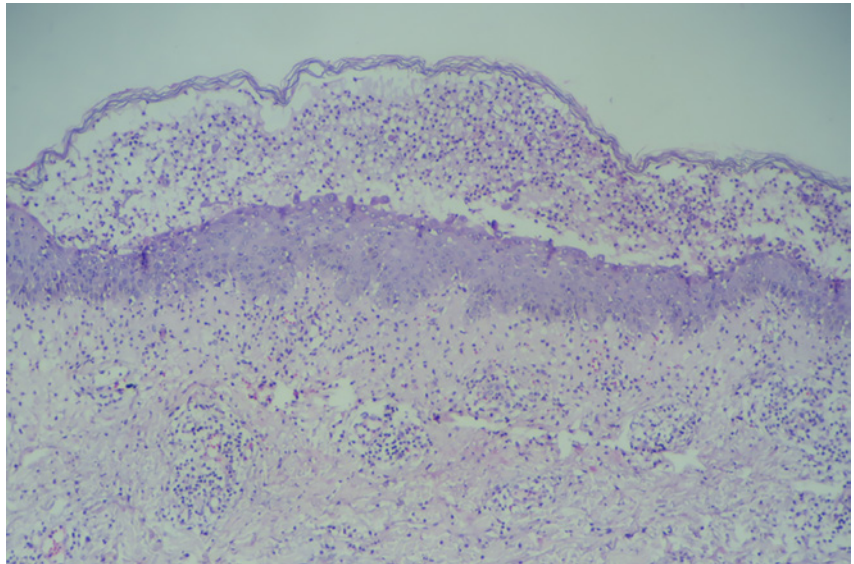
## Case report

An otherwise healthy 60-year-old man was referred to our department with a one-year history of recurrent pruritic vesiculo-pustular lesions on both axillae and groin. The lesions improved after topical application of steroids but reappeared and gradually spread to trunk and extremities. The patient was not receiving any medications. Examination revealed a symmetric eruption on the proximal extremities and trunk

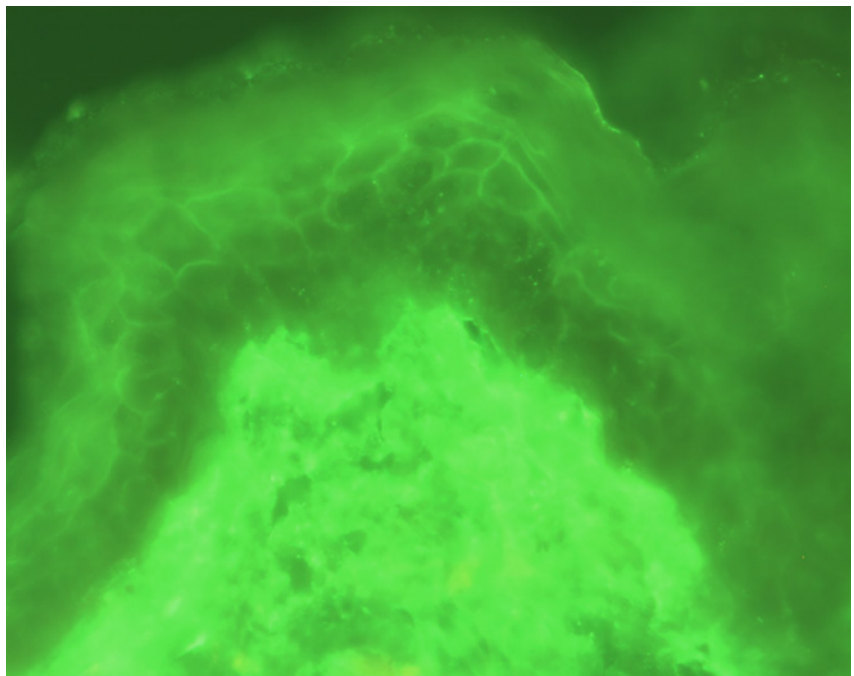
with prominent involvement of the axillae and groin. It was composed of grouped vesiculo-pustular lesions mostly on well-circumscribed erythematous patches (Figure 1). Mucous membranes were not involved. Nikolsky's sign was negative. Bacterial cultures from representative pustules were all negative. Histological examination of a biopsy specimen revealed subcorneal neutrophilic pustules with few acantholytic cells. There were also numerous neutrophils infiltrating the epidermis (Figure 2). Direct immunofluorescence micros-



**Figure 1.** Vesiculo-pustular lesions mostly on well-circumscribed erythematous patches on the axillae. [Copyright: ©2016 Hegazy et al.]



**Figure 2.** Histopathological findings: subcorneal neutrophilic pustules, few acantholytic cells and numerous neutrophils infiltrating the epidermis. [Copyright: ©2016 Hegazy et al.]



**Figure 3.** DIF of perilesional skin: intercellular deposits of IgA throughout the epidermis. [Copyright: ©2016 Hegazy et al.]

copy (DIF) of perilesional skin detected intercellular deposits of IgA throughout the epidermis (Figure 3). IgG-ELISA for desmogleins (Dsg) showed no IgG antibodies to either Dsg1 or Dsg3. IgA-ELISA for Dsgs was then performed and the results indicated that the patient's serum was positive for IgA anti-Dsg1 and anti-Dsg3 antibodies. There was no monoclonal IgA gammopathy on immunoelectrophoresis. Based on immunopathological data, intraepidermal neutrophilic dermatosis type IgA pemphigus was diagnosed. Colchicine, 0.5 mg 3 times daily was begun, but this had no effect after one month so it was substituted by dapsone 100 mg/d, which also failed to produce any improvement and his disease remained active. Subsequently, isotretinoin 25 mg/d and prednisone 20 mg/d were initiated achieving only a slight effect after six months.

## Conclusions

Based on pathology and DIF findings, IgA pemphigus can be further divided

into two subtypes, namely, subcorneal pustular dermatosis (SPD) and intraepidermal neutrophilic dermatosis (IEN) types [1,2]. Clinically, as seen in our patient, both subtypes of IgA pemphigus present with small blisters and pustules overlaying well-circumscribed erythemas [2]. A herpetiform appearance has also been reported [2]. The whole body can be involved, with a predilection for flexures, such as axilla, groin and sub-mammary area [1]. Mucosa is usually

free of lesions [2]. While SPD-type IgA pemphigus shows subcorneal pustules, the IEN type is characterized by pustule formation throughout the entire epidermis [1,2,3]. In DIF, SPD-type IgA pemphigus involves cell surface IgA binding only in the upper epidermis, whereas IEN-type IgA pemphigus shows binding throughout the epidermis [1].

Although the histological features of our case are consistent with those of the SPD type of IgA pemphigus, IEN-

type IgA pemphigus was diagnosed in the present patient because of IgA deposits throughout the epidermis. Desmocollin 1 has recently been identified as the target antigen of the SPD type [3]. In contrast, in the IEN type no reactivity of auto antibodies with desmocollin 1, 2, and 3 has been found [3], whereas desmoglein 1 and 3 were suggested as putative target antigens of IEN type in single case reports [2,3]. The result of immunoelectron microscopic study revealed that the antigen of IEN type may not be a desmosomal component [1]. In our patient, IgA-ELISA for Dsgs showed reactivity with Dsg1 and Dsg3, suggesting that his pemphigus most likely belongs to the IEN type. IEP should be performed because IgA pemphigus has been reported to be associated with monoclonal IgA gammopathy [2]. Treatments of IgA pemphigus are performed based on the disease pathomechanism and on anecdotal reports. Dapsone is commonly the drug of choice due to its effect in suppressing neutrophilic infiltration [2]. Acitretin or isotretinoin are alternatives when dapsone cannot be used [1,2,4]. Furthermore, both types of IgA pemphigus have been described as responding to colchicines [5]. Recently, adalimumab and mycophenolate

mofetil, have also been reported to be useful in treating IgA pemphigus [2]. Our case confirmed the recalcitrant nature of IgA pemphigus in response to distinct therapies, indicating that further research focusing on therapeutic approaches for this type of pemphigus is needed.

## References

1. Hashimoto T. Immunopathology of IgA pemphigus. *Clin Dermatol* 2001; 19:683-9. PMID: 11705676.
2. Tsuruta D, Ishii N, Hamada T, et al. IgA pemphigus. *Clin Dermatol* 2011;29:437-42. PMID: 21679872. DOI: 10.1016/j.clindermatol.2011.01.014.
3. Tajima M, Mitsuhashi Y, Irisawa R, et al. IgA pemphigus reacting exclusively to desmoglein 3. *Eur J Dermatol* 2010; 20(5):626-9. PMID: 20605770. DOI: 10.1684/ejd.2010.1021.
4. Moreno AC, Santi GG, Gabbi TV, et al. IgA pemphigus: case series with emphasis on therapeutic response. *J Am Acad of Dermatol* 2014; 70(1):200-1. PMID: 24355273. DOI: 10.1016/j.jaad.2013.09.037.
5. Hodak E, Lapidot M, David M. Effect of colchicine in the subcorneal pustular dermatosis type of IgA pemphigus. *J Am Acad Dermatol* 1999;40:91-4. PMID: 9922018.