

Dermscopic View of Papular Acantholytic Dyskeratosis of the Genitocrural Region

Dua Cebeci¹, İlkay Can², İbrahim Kobat³

1 Famagusta State Hospital Dermatology And Venerology Department, Famagusta, Cyprus

2 Balıkesir State Hospital Dermatology And Venerology Department, Balıkesir, Turkey

3 Famagusta State Hospital Pathology Department, Famagusta, Cyprus

Key words: acantholytic dyskeratosis, genital region, domed papules

Citation: Cebeci D, Can İ, Kobat İ. Dermscopic view of papular Acantholytic Dyskeratosis (PAD) of the genitocrural region. *Dermatol Pract Concept.* 2022;12(3):e2022084. DOI: <https://doi.org/10.5826/dpc.1203a84>

Accepted: October 21, 2021; **Published:** July 2022

Copyright: ©2022 Cebeci et al. This is an open-access article distributed under the terms of the Creative Commons Attribution License (BY-NC-4.0), <https://creativecommons.org/licenses/by-nc/4.0/> which permits unrestricted noncommercial use, distribution, and reproduction in any medium, provided the original authors and source are credited.

Funding: None.

Competing interests: None.

Authorship: All authors have contributed significantly to this publication.

Corresponding author: Dua Cebeci, Famagusta Stat Hospital, Famagusta, Cyprus, Telephone number : 05488586367
E-mail : perolidua@gmail.com

Introduction

Papular acantholytic dyskeratosis (PAD), also known as acantholytic dermatosis of the vulvocruural (or anogenital) region is a rare skin disorder reported more common in women than men. Recent studies have revealed that mutations in the ATP2C1 gene, typically seen in Hailey-Hailey disease, are also detected in papular acantholytic dermatosis of the anogenital region [1]. We report a case of a 49-year-old female with pruritic papular eruptions over the vulvocruural area. Histology of lesions revealed focal acantholysis with presence of dyskeratotic cells resembling corps ronds and grains.

Case Presentation

A 49-year-old female patient presented with persistent pruritic papular rash in both inguinal regions for 6 months. The patient applied to the obstetrics clinic with similar complaints and was referred to the dermatology clinic considering as

condyloma. She had no history or family history of any skin disorder. Physical examination revealed multiple whitish pruritic papules with underlying erythematous patches in both inguinal regions (Figure 1A). No lesions were found at other locations and her nails were normal. KOH test was negative. Skin biopsy showed numerous typical acantholytic dyskeratotic cells in the stratum corneum and spinosum. There was also hyperkeratosis and irregular acanthosis in the epidermis and lymphocytic infiltration in the underlying dermis and no evidence of viral infection, dysplasia or malignancy (Figure 2). Dermscopic examination (×10 magnification in polarized mode) showed an irregular star-shaped (circled) brown pigmentation and globular domed brown papules (Figure 1B). Direct immunofluorescence or genetic studies were not performed. Clinical and histopathological PAD was present. 0.1% topical mometasone furoate and topical tacrolin 0.1 cream were started on the patient. The patient showed a minimal improvement and is still being following up. Constant form was obtained from the patient.

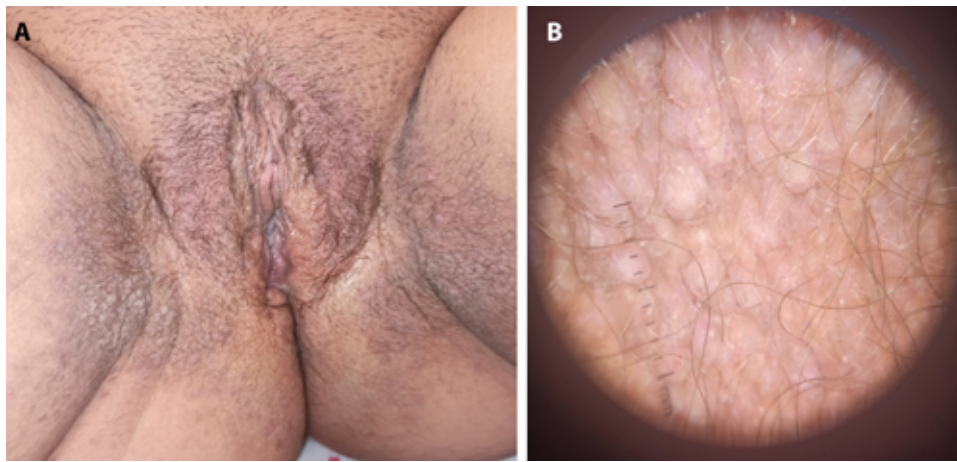

Figure 1. (a) Multiple shiny whitish papules 2 mm to 3 mm in diameter in a cobblestone pattern on the medial aspect of the thigh, on the perineum, and in the perianal region. (b) Dermoscopic image showing brown pigmentation and globular domed brown papules.

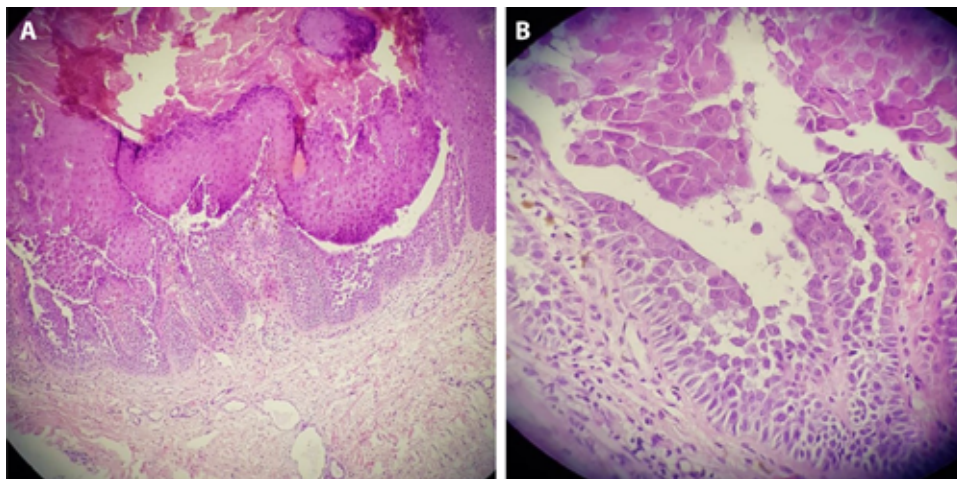


Figure 2. (a) Low-power view of a papule showing suprabasal cleft, dyskeratosis, and acantholytic cells (H&E, $\times 10$). (b) High-power view of dyskeratotic acantholytic cells (corps ronds, H&E, $\times 40$).

Conclusions

Localized PAD to the genitocrural area is a rare and distinct clinical entity that was first described by Bernard Ackerman in 1972 as focal acantholytic dyskeratosis.

The dermoscopic features of Hailey-Hailey and Darier disease been described before in several studies but the dermoscopic features of the reported cases of PAD have not been experienced. In Hailey-Hailey disease, the combination of pink and white areas was more prominent. Minor erosions and ulcerations may also accompany it. In contrast, polygonal, star-like, roundish-oval, whitish, yellowish areas with peripheral halos have been described in Darier's disease [2].

In this report, brown to gray hyperpigmented domed papules with a central hypopigmented core were the main

dermoscopic findings. By reporting the dermoscopy of this case PAD, we would like to point out the usefulness of such dermoscopy in assisting the recognition of this entity.

References

1. Al-Murieh M, Abdul-Fattah B, Wang X, Zhao M, Chen S, Huang C. Papular acantholytic dyskeratosis of the anogenital and genitocrural area: case series and review of the literature. *J Cutan Pathol.* 2016;43(9):749-758. DOI: 10.1111/cup.12736. PMID: 27161553.
2. Kadiri S, Bay Bay H, Chaoui R, Douhi Z, Elloudi S, Mernissi FZ. Dermoscopy of Hailey - Hailey disease: Is it useful? *Our Dermatol Online.* 2020;11(e):e50.1-e50.2. DOI: 10.7241/ourd.2020e.50.