

Do PD-1/PDL-1 Inhibitors Play a Triggering or Causative Role in the Development of Paraneoplastic Dermatomyositis?

Michela Starace¹, Francesca Pampaloni², Miriam Anna Carpanese¹,
Andrea Sechi¹, Francesca Bruni¹, Aurora Alessandrini¹

¹ Dermatology -IRCCS Policlinico di Sant'Orsola - Department of Experimental, Diagnostic and Specialty Medicine (DIMES)
Alma Mater Studiorum University of Bologna, Italy

² Dermatology Unit, Department of Medicine, University of Padova, Italy

Key words: PD-1 inhibitors, dermatomyositis, paraneoplastic, breast cancer, immune-related adverse events

Citation: Starace M, Pampaloni F, Carpanese MA, et al. Do PD-1/PDL-1 Inhibitors Play a Triggering or Causative Role in the Development of Paraneoplastic Dermatomyositis? *Dermatol Pract Concept*. 2022;12(3):e2022105. DOI: <https://doi.org/10.5826/dpc.1203a105>

Accepted: October 25, 2021; **Published:** July 2022

Copyright: ©2022 Starace et al. This is an open-access article distributed under the terms of the Creative Commons Attribution License (BY-NC-4.0), <https://creativecommons.org/licenses/by-nc/4.0/> which permits unrestricted noncommercial use, distribution, and reproduction in any medium, provided the original authors and source are credited.

Funding: None.

Competing interests: None.

Authorship: All authors have contributed significantly to this publication.

Corresponding author: Carpanese Miriam Anna, MD, Dermatology -IRCCS Policlinico di Sant'Orsola - Department of Experimental, Diagnostic and Specialty Medicine (DIMES) Alma Mater Studiorum University of Bologna, Via Massarenti, 1, 40138 Bologna, Italy, phone: +390512143677 fax: +390512144867 E-mail: miriam.carpanese@gmail.com

Introduction

The use of immune checkpoint inhibitors therapy in cancers is widely diffuse but the dermatologic immune-related adverse events (irAEs) are not completely characterized. We present the first case of paraneoplastic dermatomyositis triggered by atezolizumab.

Case presentation

A 53-year-old woman affected by ductal infiltrative breast cancer underwent mastectomy and lymphadenectomy, followed adjuvant chemotherapy. Later she started paclitaxel weekly and atezolizumab after 2 months. At the fifth infusion of atezolizumab she developed a skin rash attributed

to drug. Dermatologic examination revealed marked butterfly-facial edema with periocular swelling, erythematous-violaceous plaques of the face, upper chest and back. (Figure 1A). Erythematous papules coalescing into plaques of the metacarpophalangeal and proximal interphalangeal joints were detected (Figure 1B). Hemorrhagic onycholysis and periungual erythema were detected by capillaroscopy that revealed capillary loss, tortuosity, ramified, enlarged capillaries, and microhemorrhages (Figure 1, C and D). A skin biopsy from a papule of the back of the hand showed an interface dermatitis and focal mucin deposition in the dermis. Laboratory testing revealed positive ANA (1:320), normal CPK (212 U/l), mild increased serum aldolase (15.5 U/l), normal transaminases. Given the clinical presentation, capillaroscopy, histopathology and ANA positivity

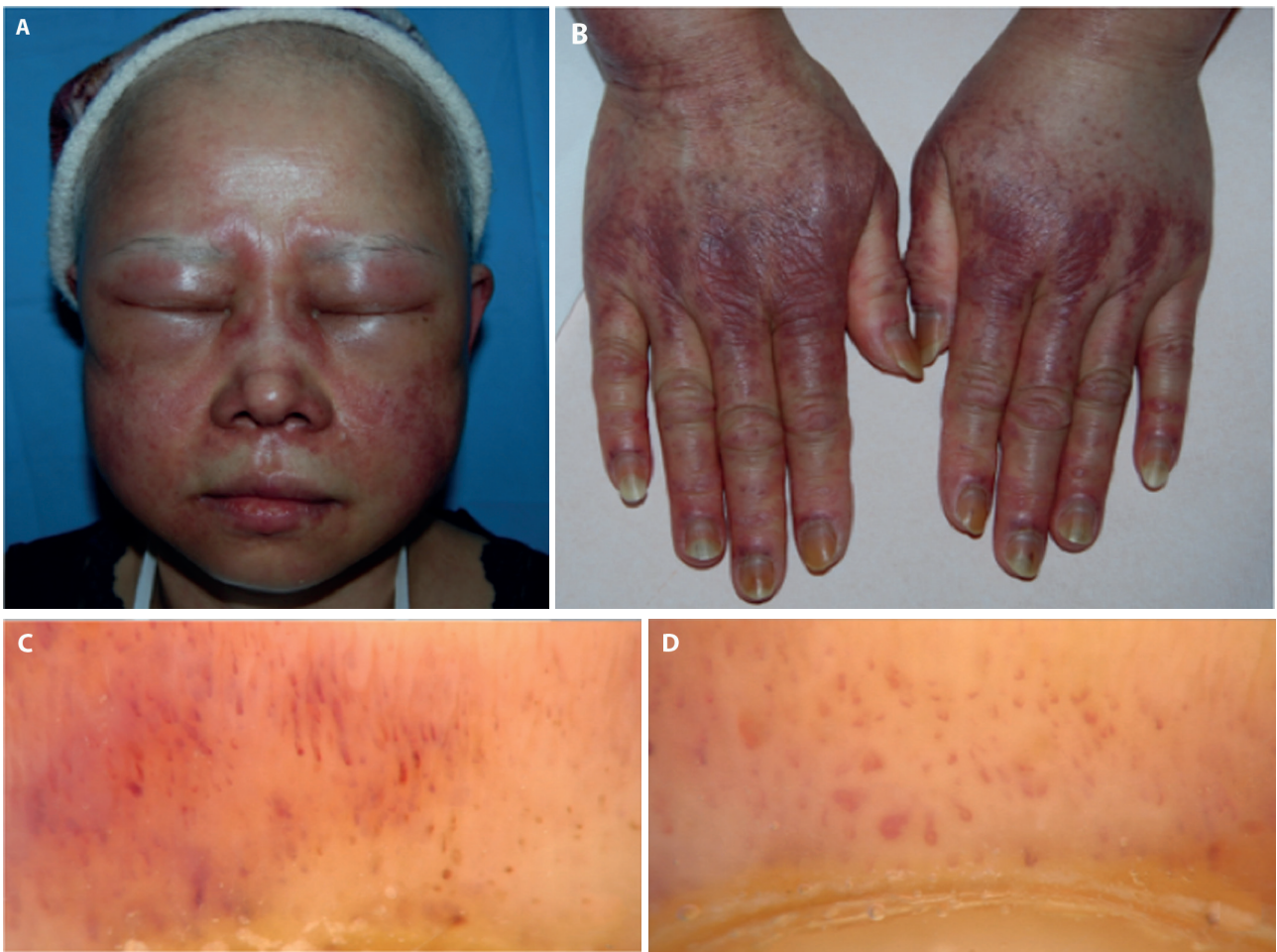

Figure 1. (A) Facial butterfly-edema, with periocular swelling, erythematous-to-slightly-violaceous plaques sparing the frontal region and the submental area. (B) Erythematous discrete papules coalescing into plaques of the metacarpophalangeal and proximal interphalangeal joints. (C) Capillaroscopic examination: capillary loss, tortuosity, ramified, enlarged and giant capillaries, and microhemorrhages 50X magnification. (D) 70X magnification

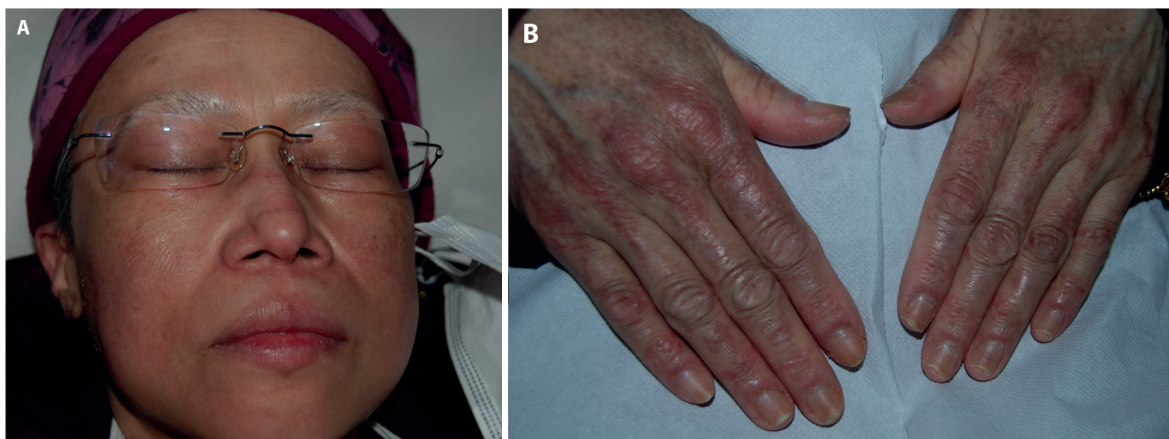


Figure 2. The same patient after the therapy with intravenous immunoglobulin: evident improvement on face (A) and hands (B).

we made the diagnosis of dermatomyositis. Between myositis-specific antibodies requested anti-TIF γ antibodies were significantly positive (negative anti-Ro and anti-JO). Systemic prednisone 50 mg daily and intravenous immunoglobulins were prescribed with improvement of the clinical signs (Figure 2).

Conclusions

PD-1/PDL-1 inhibitor immunotherapy represents a successful treatment for advanced malignancies; it can be associated with lots of irAEs, among which dermatomyositis. Guidelines recommend temporary or permanent drug

interruption according to the severity of the skin reaction [1]. Besides being drug-induced, dermatomyositis is a well described paraneoplastic disease in ovarian and breast cancer. The patient described in our report had the exposure to atezolizumab and breast cancer, which are both risk factors for the development of dermatomyositis.

At the beginning we believed that dermatomyositis could be drug induced, due to the latency between the drug infusion and the onset of the reaction, and the strong association between anti- PD-1/PDL-1 therapy and dermatomyositis. Nevertheless, the worsening after drug discontinuation suggested that the anti- PD-1/PDL-1 was only a triggering factor for a classical paraneoplastic dermatomyositis. Paraneoplastic origin was supported by the presence of all the criteria proposed for the diagnosis of paraneoplastic dermatoses. The disease was near the beginning of the cancer and following the same course, moreover dermatomyositis is rare in the general population but strictly associated to tumors, as cancer occur in 14.8% of dermatomyositis patients [2]. The detection of anti-TIF γ antibodies, that are positive in 42%-100% of paraneoplastic dermatomyositis, confirmed our diagnosis [1].

This case adds new findings to the literature regarding dermatomyositis associated with PD-1/PDL-1 inhibitors. PD-1/PDL-1 inhibitors could have a triggering role rather than a causative role in the development of dermatomyositis. Clinicians should be aware that facing a patient affected by metastatic cancer treated with PD-1/PDL-1 inhibitors, cutaneous adverse events such dermatomyositis may be not related to the treatment but also to the underlying disease, preventing the interruption of safety treatments.

References

1. Messer A, Drozd B, Glitza IC, Lu H, Patel AB. Dermatomyositis associated with nivolumab therapy for melanoma: a case report and review of the literature. *Dermatol Online J.* 2020;26(8):13030/qt4c21b068. PMID: 32941716.
2. Didona D, Fania L, Didona B, Eming R, Hertl M, Di Zenzo G. Paraneoplastic Dermatoses: A Brief General Review and an Extensive Analysis of Paraneoplastic Pemphigus and Paraneoplastic Dermatomyositis. *Int J Mol Sci.* 2020;21(6):2178. DOI: 10.3390/ijms21062178. PMID: 32245283; PMCID: PMC7139382.