

Dermoscopy for Acral Melanocytic Lesions: Revision of the 3-step Algorithm and Refined Definition of the Regular and Irregular Fibrillar Pattern

Toshiaki Saida¹, Hiroshi Koga¹, Hisashi Uhara²

1 Department of Dermatology, Shinshu University School of Medicine, Matsumoto, Japan

2 Department of Dermatology, Sapporo Medical University School of Medicine, Sapporo, Japan

Citation: Saida T, Koga H, Uhara H. Dermoscopy for acral melanocytic lesions: Revision of the 3-step algorithm and refined definition of the regular and irregular fibrillar pattern. *Dermatol Pract Concept.* 2022;12(03):e2022123. DOI: <https://doi.org/10.5826/dpc.1203a123>

Accepted: October 26, 2021; **Published:** July 2022

Copyright: ©2022 Saida et al. This is an open-access article distributed under the terms of the Creative Commons Attribution License (BY-NC-4.0), <https://creativecommons.org/licenses/by-nc/4.0/>, which permits unrestricted noncommercial use, distribution, and reproduction in any medium, provided the original authors and source are credited.

Funding: None.

Competing interests: None.

Authorship: All authors have contributed significantly to this publication.

Corresponding author: Toshiaki Saida, MD, PhD, Shinshu University, Matsumoto; Kamiochiai 7-7-40-220, Chuo-ku, Saitama 338-0001, Japan. E-mail: tosaida@xb4.so-net.ne.jp

Acral melanoma (AM) is the most prevalent subtype of malignant melanoma in non-white populations. It is often detected in advanced stages, resulting in poor prognosis. However, the prognosis is favorable if detected in the early stages; almost all the patients with AM in situ are cured only by surgical excision with a narrow margin. Thus, early detection is essential in the management of AM. Although clinical differentiation between early AM and acral nevus is sometimes very difficult, dermoscopy is highly helpful in the differentiation [1]. A commonly detected, specific dermoscopic pattern of early AM is the parallel ridge pattern (PRP), exhibiting band-like pigmentation on the surface ridges of the skin markings (dermatoglyphics) [2]. In contrast, the main dermoscopic pattern of acral nevus is the parallel furrow pattern (PFP) showing linear pigmentation along the sulci of the skin markings. Other dermoscopic patterns frequently observed in acral nevus are the lattice-like pattern and the fibrillar pattern (FP), both being modifications of the PFP [3].

The 3-step Algorithm and its Re-revision

Based on these characteristic dermoscopic findings, in 2007 our group proposed a dermoscopic 3-step algorithm for the management of acral melanocytic lesions [3] and then, revised it in 2011 [4]. Recently, several studies were reported which examined utility of the 3-step algorithm [5-7]. In these studies, the 3-step algorithm generally worked well, however, in one study, the algorithm missed one lesion of AM, 0.5 mm in Breslow thickness. The lesion, 6 mm in diameter, did not show the PRP but exhibited a multicomponent pattern. Considering rather lower sensitivity of the PRP in AM of their case series, Lallas et al proposed the BRAAFF checklist for the effective detection of AM, which included irregular blotch and asymmetry of structures and colors as positive features [8]. These findings along with our further experience prompted us to re-revise the 3-step algorithm as shown in Figure 1. This version includes a multicomponent

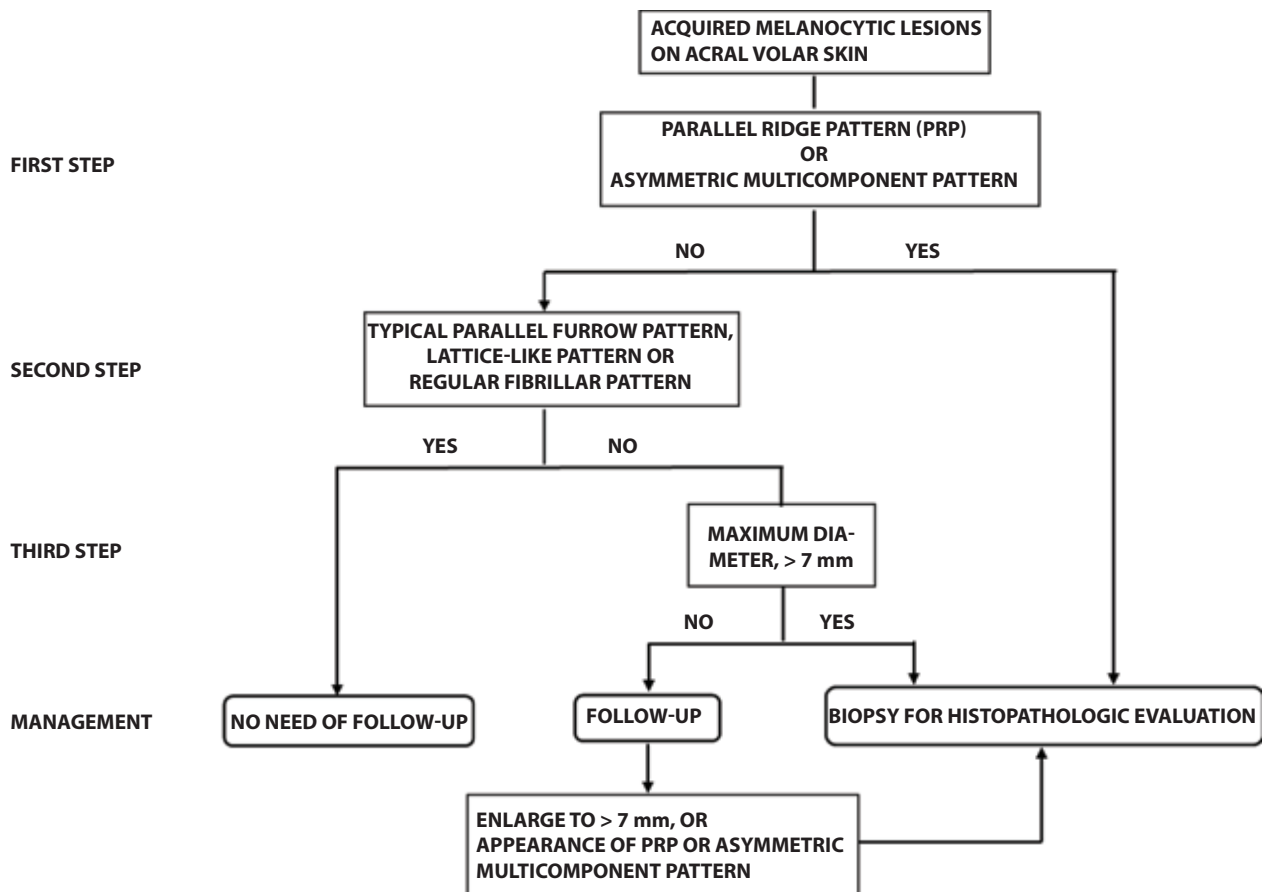


Figure 1. The re-revised 3-step algorithm for the management of melanocytic lesions on acral volar skin. The main targets of this algorithm are macular/patch lesions seen in adults. Apparently congenital lesions and nodular lesions are excluded from the evaluation.

pattern in the first step as well as a follow-up strategy after the third step.

One possible problem in using the 3-step algorithm is judgment of whether the FP is regular or irregular. According to Costello et al, physicians often did not recognize the regular FP as a benign pattern [6]. The FP is characterized by densely packed brownish fibrillar lines arranged in a parallel fashion and crossing the skin markings. Each fibril of the pattern corresponds to a melanin column in the thick cornified layer which is obliquely arranged due to the mechanical pressure from the body weight. This is the reason for the predilection of nevi of this pattern for the pressured areas of the sole [9]. Thus, the FP is regarded as an artifactual expression of the PFP [1, 3]. Noteworthy is that the FP is occasionally found focally within a lesion of AM [1]. This is not strange because, as mentioned above, the FP is detected in the pressured areas of the sole, which are the most prevalent subsite of AM. Moreover, the FP can occupy an almost entire lesion of AM in situ, particularly in its early evolving stages [10,11]. This could lead us to misdiagnosis of AM in situ as acral nevus. Hence, it is very important for us to correctly differentiate the FP of early AM in situ from that of acral nevus.

Criteria for Regular and Irregular Fibrillar Pattern and Clues to the Management

Herein, based on our experience, we refine the definitions of the “regular” and “irregular” FP, and then write down several clues which help us in the management of acral lesions showing the FP. The oblique dermoscopy [12] and the furrow ink test [13, 14] are very helpful in the evaluation of the FP.

Regular FP of acral nevus

The fibrils constituting the regular FP are evenly distributed throughout the lesion and mostly same in color and thickness (Figure 2A). The endpoints (deeper color ends) of the fibrils tend to line up on the sulci of the skin markings. In addition, not infrequently, the FP is combined with the PFP and/or changes to the PFP at the periphery. In most cases, the oblique dermoscopy demonstrates that the FP is originally the PFP (Figure 2B).

Irregular FP of acral melanoma

The fibrils constituting the irregular FP are unevenly distributed and variable in color and thickness (Figure 3). In most cases, the endpoints of the fibrils are arranged randomly.

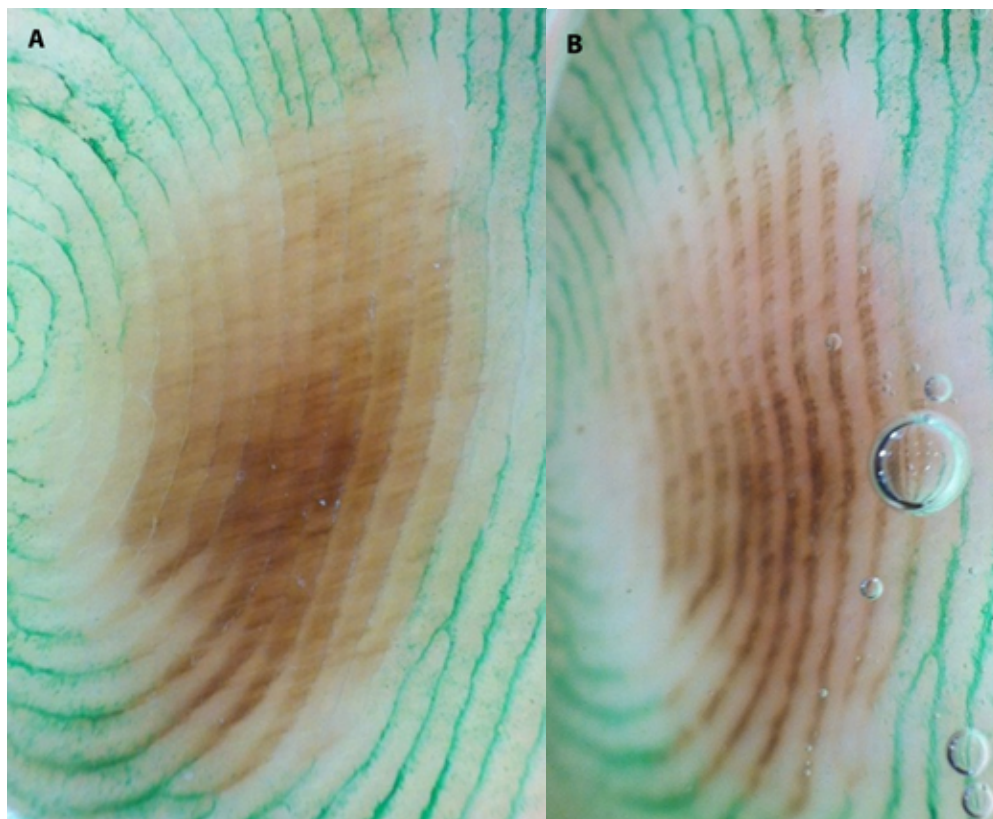


Figure 2. Regular fibrillar pattern of acral nevus (dermoscopy with the furrow ink test). (A) The fibrils constituting the pattern are regular in color, thickness and distribution. All the endpoints of the fibrils line up on the sulci of the skin markings. The pattern changes to the parallel furrow pattern in the lower portion. (B) The oblique dermoscopy reveals that this is originally the parallel furrow pattern.

In some lesions, however, they are located within the width of the ridges of the skin markings. Moreover, the PRP is not infrequently detected at least focally within a lesion. By the oblique dermoscopy, the irregular FP does not change to the PFP but, though rarely, to the PRP [10].

In addition to the aforementioned criteria, there are several findings which are helpful when we manage acral lesions showing the FP. They are summarized as follows.

1. If, in a lesion of the FP, non-site specific dermoscopic findings of melanoma (eg irregular streaks, irregular dots/globules, irregular blotches, blue-white veils, and/or regression structures) are detected, the lesion should be treated as AM.
2. Acral lesions exhibiting the negative fibrillar pattern should be biopsied for histopathologic evaluation (Figure 3). This pattern consists of whitish rods arranged in a parallel fashion on the dark structureless or fibrillar background [15]. The whitish rods represent intracorneal eccrine ducts. In our recent study of acral nevi (41 lesions) and AM in situ (10 lesions), the sensitivity and specificity of this finding for AM in situ were 40% and 90%, respectively [16].
3. A very early lesion of AM in situ could show the FP entirely composed of densely packed very thin fibrils

crossing the surface ridges but uninvolving the sulci (Figure 4). This finding may be misinterpreted as the “regular” FP. But it does not change to the PFP on oblique dermoscopy. Such a lesion should be biopsied or carefully followed, particularly when seen in elderly persons. In our case series, this “regular” FP was observed in 2 out of 10 lesions of AM in situ showing the FP [16].

4. If the fibrils composing the FP is thick and regular in color, the lesion is certainly diagnosed as acral nevus, particularly when the lesion is small, ie, less than 5 mm in diameter (Figure 5).
5. When we cannot determine whether the FP is regular or irregular, periodic follow-up of the lesion is recommended, with a frequency of once or twice a year.

It is widely accepted that dermoscopy is quite helpful in the evaluation of pigmented lesions on acral volar skin. We believe the re-revised 3-step algorithm and refined criteria for the regular and irregular FP described in this commentary will further assist clinicians in managing acral melanocytic lesions appropriately, though their validity must be evaluated in larger case series.

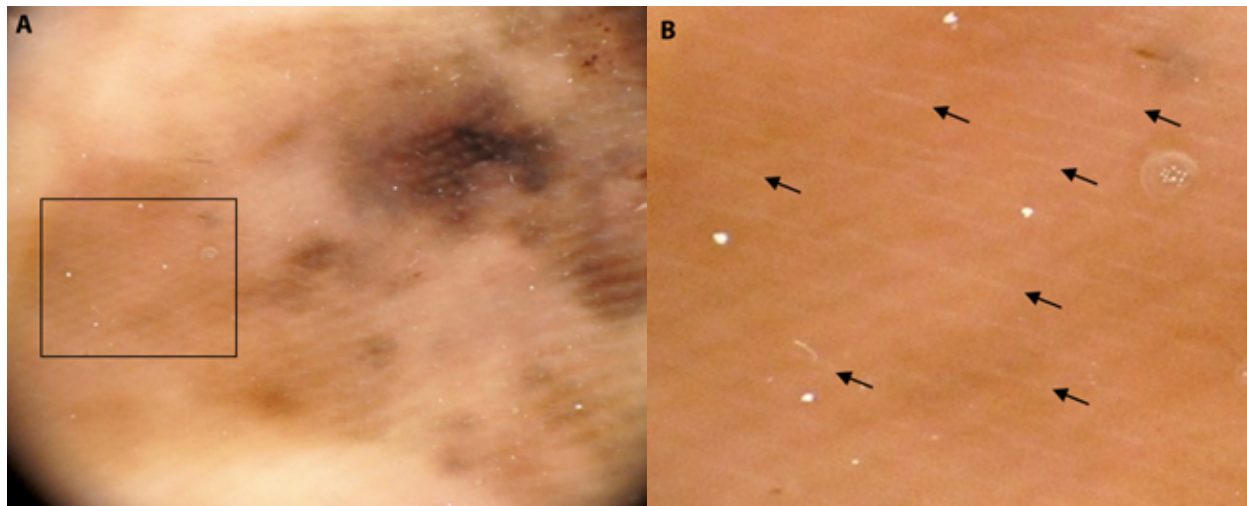


Figure 3. Irregular fibrillar pattern of acral melanoma in situ. This lesion of the multicomponent pattern is mostly composed of fibrils and can be regarded as the irregular FP by our definition, ie, the fibrils constituting the pattern are irregular in color, thickness and distribution, and their endpoints do not line up on the sulci of the skin markings. (A) Transition to the parallel ridge pattern is detected in the right lower portion. The negative fibrillar pattern (whitish rods arranged in a parallel fashion) are detected in the left area, which is well recognized in (B), an image of higher magnification corresponding to the square area in (A). (B) Arrows indicate some of the whitish rods.

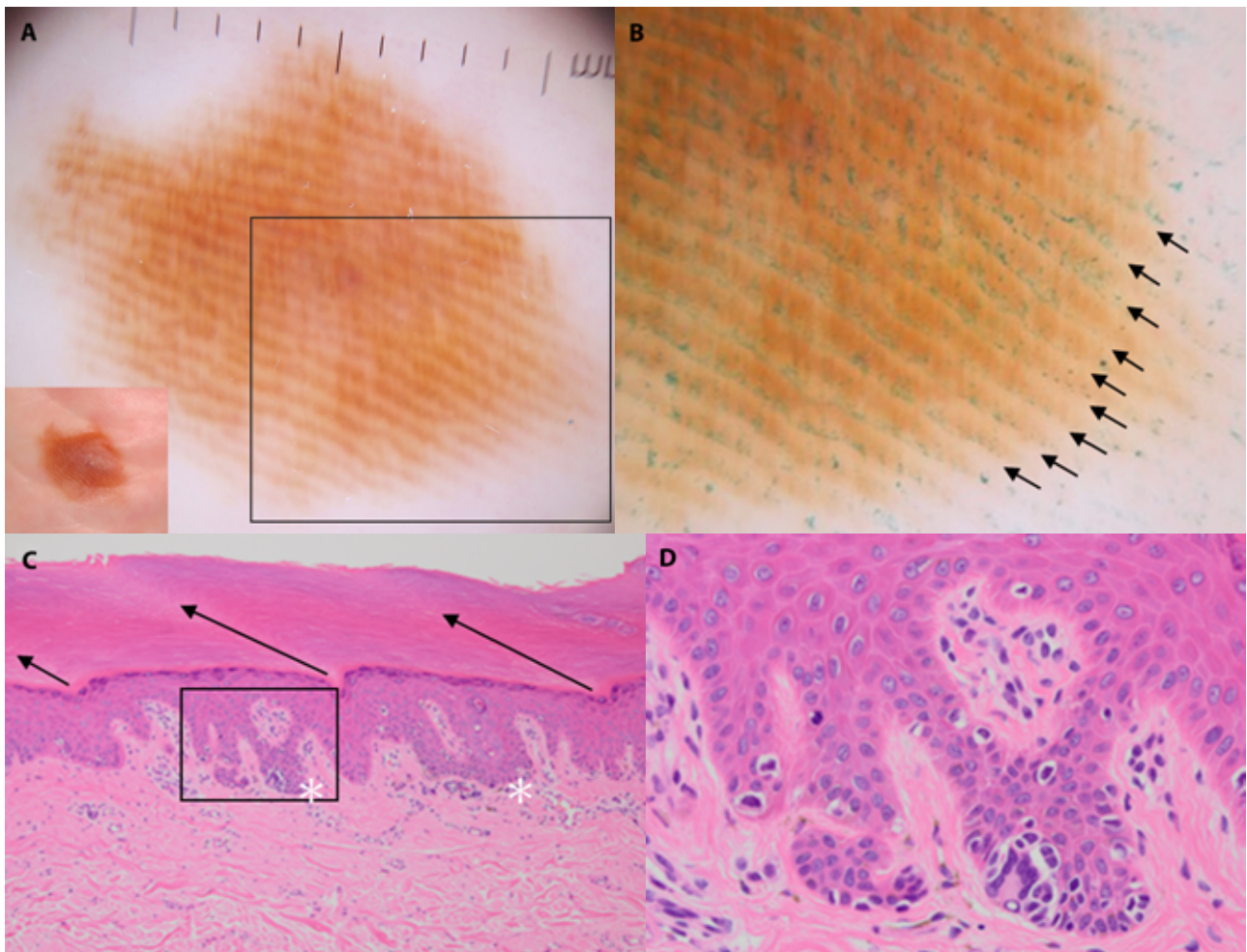


Figure 4. “Regular” fibrillar pattern seen in acral melanoma in situ (A, inset: clinical features: a brown patch, 13.5 × 10.5 mm in size, seen on the sole of a 78-year-old woman). (A) The very thin fibrils constituting this fibrillar pattern are evenly arranged and regular in color and thickness. (B) the square area in (A). The furrow ink test reveals that the sulci of the skin markings, indicated with arrows, are spared from the fibrillar pigmentation. (C, D) Histopathological features. (D) corresponds to the square area in (C). The thick cornified layer is obliquely arranged, as indicated with arrows in (C). The increased number of melanocytes are mainly detected in the crista profunda intermedia indicated with asterisks in (C) and their nuclei are large and hyperchromatic as seen in (D), confirming this is acral melanoma *in situ*. (Note: FISH analysis of this lesion revealed amplification of cyclin D1.)



Figure 5. Regular fibrillar pattern composed of thick fibrils. A small brown macule, 4 mm in diameter, seen on the sole of a 38-year-old woman. This fibrillar pattern is composed of regularly arranged thick fibrils, of which endpoints line up on the sulci of the skin markings. Although the color density of the fibrils is somewhat different within the lesion, the color distribution is mostly symmetric, indicating this is the regular FP. From these findings, we can certainly diagnose this lesion as acral nevus. Note: These thick fibrils indicate that melanocytes in the epidermis are not distributed as solitary units but arranged mostly in larger nests, which is an important histopathologic clue to benign nevus of a small size such as this one (4mm).

References

- Saida T, Koga H, Uhara H. Key points in dermoscopic differentiation between early acral melanoma and acral nevus. *J Dermatol.* 2011;38(1):25-34. DOI:10.1111/j.1346-8138.2010.01174.x. PMID: 21175752.
- Saida T, Miyazaki A, Oguchi S, et al. Significance of dermoscopic patterns in detecting malignant melanoma on acral volar skin: Results of a multicenter study in Japan. *Arch Dermatol.* 2004;140(10):1233-1238. DOI:10.1001/archderm.140.10.1233. PMID: 15492186.
- Saida T, Koga H. Dermoscopic patterns of acral melanocytic nevi: Their variations, changes, and significance. *Arch Dermatol.* 2007;143(11):1423-1426. DOI:10.1001/archderm/143.143.11.1423. PMID: 18025367.
- Koga H, Saida T. Revised 3-step dermoscopic algorithm for the management of acral melanocytic lesions. *Arch Dermatol.* 2011;147(6):741-743. DOI:10.1001/archdermatol.2011.136. PMID: 21690544.
- Madankumar R, Gumaste PV, Martires K, et al. Acral melanocytic lesions in the United States: Prevalence, awareness, and dermoscopic patterns in skin-of-color and non-Hispanic white patients. *J Am Acad Dermatol.* 2016;74(4):724-730. DOI:10.1016/j.jaad.2015.11.035. PMID: 26803347.
- Costello CM, Ghanavatian S, Temkit M, et al. Educational and practice gaps in the management of volar melanocytic lesions. *J Eur Acad Dermatol Venereol.* 2018;32(9):1450-1455. DOI:10.1111/jdv.14712. PMID: 29178552.
- Han B, Hur K, Ohn J, Lim SS, Mun J-H. Acral lentiginous melanoma in situ: Dermoscopic features and management strategy. *Sci Rep.* 2020;10:20503. DOI: 10.1038/s41598-020-77425-z. PMID: 33239715.
- Lallas A, Kyrgidis A, Koga H, et al. The BRAAFF checklist: A new dermoscopic algorithm for diagnosing acral melanoma. *Br J Dermatol.* 2015;173(4):1041-1049. DOI:10.1111/bjd.14045. PMID: 26211689.
- Miyazaki A, Saida T, Koga H, Oguchi S, Suzuki T, Tsuchida T. Anatomical and histopathological correlates of the dermoscopic patterns seen in melanocytic nevi on the sole: A retrospective study. *J Am Acad Dermatol.* 2005;53(2):230-236. DOI: 10.1016/j.jaad.2005.04.045. PMID: 16021115.
- Kiyohara T, Satoh S, Yasuta M, Kumakiri M. Irregular fibrillar pattern is an artifactual expression of parallel ridge pattern

- on the pressure-loaded area of the sole: The efficacy of oblique view dermoscopy. *J Dermatol*. 2012;39(11):927-928. DOI: 10.1111/j.1346-8138.2011.01469.x. PMID: 22221139.
11. Togawa Y, Wakabayashi S, Suehiro K, Matsue H. Acral melanoma showing fibrillar pattern on dermoscopy. *Austin J Dermatol*. 2017;4(2):1076.
 12. Maumi Y, Kimoto M, Kobayashi K, Ito N, Saida T, Tanaka M. Oblique view dermoscopy changes regular fibrillar pattern into parallel furrow pattern. *Dermatology*. 2009;218(4):385-386. DOI: 10.1159/000202986. PMID: 19218789.
 13. Braun RP, Thomas L, Kolm I, French LE, Marghoob AA. The furrow ink test: A clue for the dermoscopic diagnosis of acral melanoma vs nevus. *Arch Dermatol*. 2008;144(12):1618-1620. DOI: 10.1001/archderm.144.12.1618. PMID: 19075144.
 14. Uhara H, Koga H, Takata M, Saida T. The whiteboard marker as a useful tool for the dermoscopic "furrow ink test". *Arch Dermatol*. 2009;145(11):1331-1332. DOI: 10.1001/archdermatol.2009.275. PMID: 19917971.
 15. Watanabe S, Sawada M, Ishizaki S, Kobayashi K, Tanaka M. Comparison of dermoscopic images of acral lentiginous melanoma and acral melanocytic nevus occurring on body weight-bearing areas. *Dermatol Pract Concept*. 2014;4(4):47-50. DOI:10.5826/dpc.0404a08. PMID: 25396085.
 16. Saida T. Dermoscopic diagnosis of acral pigmented lesions. *Rinsho Derma (Tokyo)*. 2021;63(8):1241-1248. (in Japanese).