

Dermoscopic findings in a patient with multiple piloleiomyomas

Francisco Macedo Paschoal, M.D., Ph.D.¹, Gisele Gargantini Rezze, M.D., Ph.D.²

¹ Dermatology Department, ABC Medical School, São Paulo, Brazil.

² Cutaneous Oncology Department, Hospital AC Camargo, São Paulo, Brazil.

Key words: piloleiomyoma, dermoscopy

Citation: Paschoal FM, Rezze GG. Dermoscopic findings in a patient with multiple piloleiomyomas. *Dermatol Pract Conc*. 2012;2(4):6. <http://dx.doi.org/10.5826/dpc.0204a06>.

Received: April 12, 2012; **Accepted:** August 7, 2012; **Published:** October 31, 2012

Copyright: ©2012 Paschoal et al. This is an open-access article distributed under the terms of the Creative Commons Attribution License, which permits unrestricted use, distribution, and reproduction in any medium, provided the original author and source are credited.

Funding: None.

Competing interests: The authors have no conflicts of interest to disclose.

All authors have contributed significantly to this publication.

Corresponding author: Francisco Macedo Paschoal, Rua Cardoso de Almeida, 788—cj. 103, São Paulo SP CEP 05013-001, Brasil. Tel.: +55.11.38733105; Fax. +55.11.38733437. E-mail: frpasch@uol.com.br.

ABSTRACT Piloleiomyoma can manifest itself as a pigmented lesion and part of the differential diagnosis with other pigmented skin lesions. However, we are not aware of previous descriptions in the literature of the dermoscopic features of piloleiomyoma. This article describes the dermoscopic findings observed in a patient with multiple piloleiomyomas. On dermoscopic evaluation, piloleiomyoma has characteristics similar to dermatofibroma with a thin peripheral pigmented network and central scar-like area. Some of the piloleiomyomas analyzed in this patient also presented with hyperpigmented circular and/or elongated structures within the central hypopigmented area.

Case report

A 43-year-old female patient presented with clusters of multiple firm, painful, brownish papules and nodules covering the entire lower left limb and extending up to the left flank in a zosteriform arrangement (Figure 1A, 1B). Dermoscopic examination was performed in five of the papules. One papule revealed a featureless central hypopigmented area with a delicate peripheral network (Figure 1C, 1E). In each of the remaining four lesions, we observed the presence of a circular and/or elongated hyperpigmented structure that lacked a well-defined dermoscopic pattern within the hypopigmented central area (Figure 1D, 1F). On hematoxylin and eosin histopathologic examination of two excised lesions (Figure 2A—

corresponding to Figures 1C, 1E; Figure 2B—corresponding to Figure 1D, 1F), a benign mesenchymal neoplasia was observed, consisting of interlacing bundles of smooth muscle cells intermingled with various amounts of collagen bundles in accordance with the diagnosis of cutaneous leiomyoma. Furthermore, in Figure 2B, the elongation of the rete ridges associated with focal compact hyperkeratosis was also noted.

Discussion

Cutaneous leiomyomas are rare benign tumors arising from smooth muscle cells [1]. Cutaneous leiomyomas comprise approximately 5% of all leiomyomas. According to their site of origin they can be classified into three types, those derived

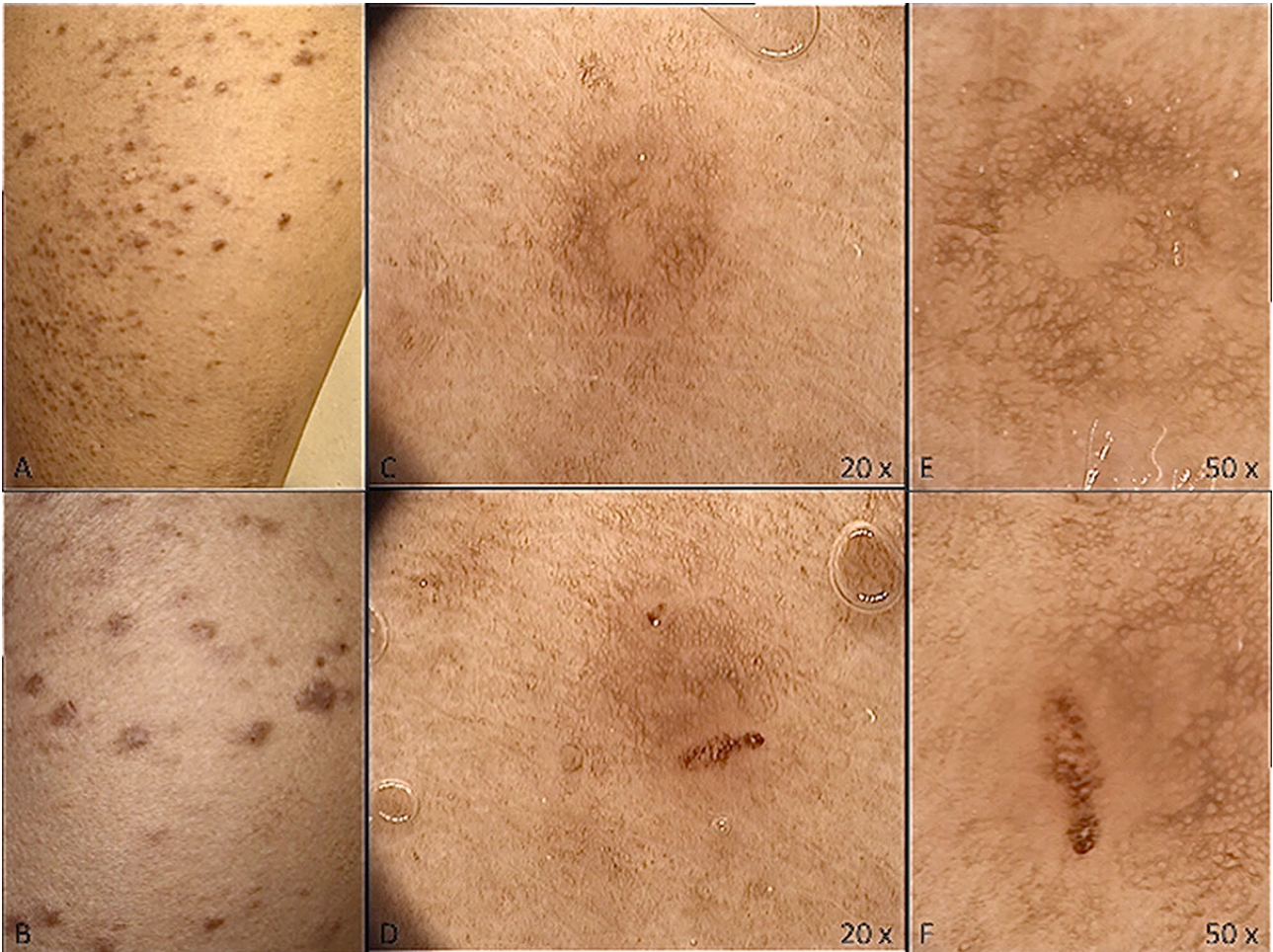

Figure 1. (A, B) Hyperpigmented papules located on the left lower limb with zosteriform distribution. (C, E) The dermoscopic pattern is similar to that described in dermatofibroma without featureless central hypopigmented area and thin peripheral pigmented network. (D, F) In addition, a hyperpigmented, elongated structure with an ill-defined dermoscopic pattern can also be seen in some of the cases. [Copyright: ©2012 Paschoal et al.]

from the erector pili muscle of hair follicles (piloileiomyomas); those originating from the vascular smooth muscle (angioleiomyomas); and those arising from the smooth muscle of genital skin (dartoic leiomyomas) [1,2].

Cutaneous leiomyomas typically present in the second to fourth decade of life as skin-colored or brown-reddish

grouped papules or nodules localized on the trunk and limbs [1]. These tumors are painful on exposure to cold and trauma; pain could result from local pressure by the tumor on cutaneous nerves [3]. The main differential diagnosis consists of other dermal nodular lesions like dermatofibroma, eruptive syringoma, angiolipoma, neurilemoma, endometri-

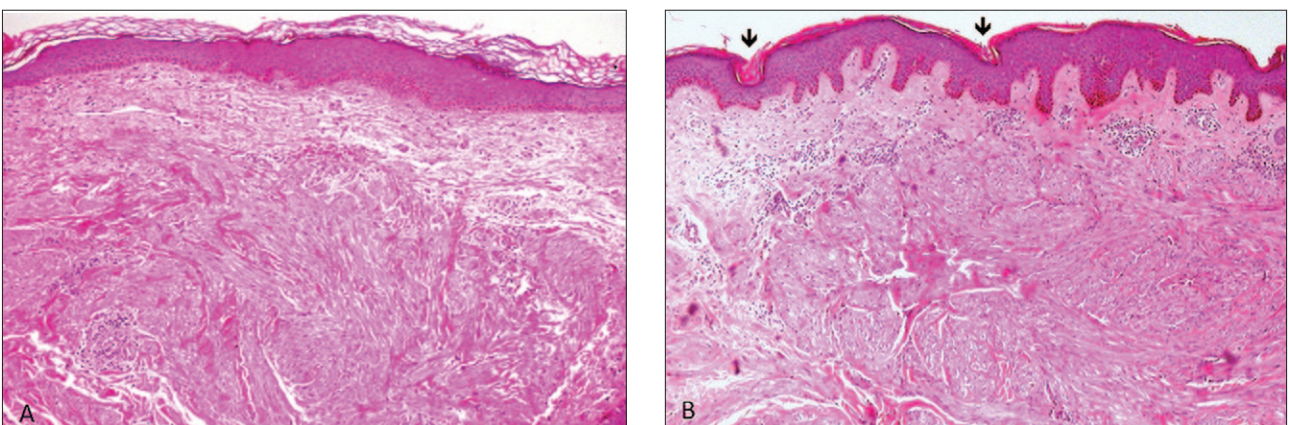


Figure 2. (A, B) Histopathology shows interlacing bundles of smooth muscle cells intermingled with various amounts of collagen bundles. (B) The black arrows emphasize elongation of the rete ridges associated with focal compact hyperkeratosis. [Copyright: ©2012 Paschoal et al.]

oma, leiomyosarcoma, glomus tumor, eccrine spiradenoma, lipoma and blue nevus [1,4]. Although piloleiomyoma is frequently pigmented, it does not frequently enter a clinician's differential diagnosis when evaluating cutaneous pigmented lesions. Moreover, we are not aware of previous dermoscopic descriptions of piloleiomyoma in the literature.

Dermoscopically, piloleiomyoma presents similar features of dermatofibroma with the central featureless hypopigmented area and a delicate peripheral network [5,6,7]. In addition, we observed the presence of oval and/or elongated hyperpigmented structures within the central area that, to the best of our knowledge, have not been previously described. We suggest that it may be explained by the presence of focal compact hyperkeratosis that generates a dermoscopic feature similar to the pseudofollicular openings and pseudostreaks seen in pigmented seborrheic keratosis [8,9]. Another reason for this feature could be erosions caused by scratching or picking. Further observations are necessary to determine if this feature is a characteristic finding in piloleiomyoma. In vivo confocal microscopy could help to elucidate its origin.

References

1. Suzuki HS, Cavalin LC, Werner B, Sato MS, Brenner FM. Caso para diagnóstico. *An Bras Dermatol* 2007;82:190-2.
2. Parreira LML, Sípoli JM, Mercante AMC, Orfali RL, Levites J. Caso para diagnóstico. *An Bras Dermatol*. 2009;84:197-9.
3. Kamoj S, Kumar Sharma RK, Kumar A, Chaudhary SS, Jain VK. Crusted piloleiomyoma with mental retardation: a rare association. *Indian J Dermatol*. 2009;54(1):75-6.
4. Pacheco AP, Ramos AMO, Rolim MLM, Oliveira FM, Lopes JG, Rocha KF. Piloleiomioma múltiplo: relato de caso com diagnóstico diferencial. *An Bras Dermatol*. 1995;70:43-6.
5. Arpaia N, Cassano N, Vena GA. Dermatofibroma: a case report and personal considerations. *Dermatol Surg*. 2004;30(3):421.
6. Puig S, Romero D, Zaballos P, Malveyh J. Dermoscopy of dermatofibroma. *Arch Dermatol*. 2005;141(1):122.
7. Arpaia N, Cassano N, Vena GA. Dermoscopic patterns of dermatofibroma. *Dermatol Surg*. 2005;31(10):1336-9.
8. de Giorgi V, Massi D, Stante P, Carli P. False "melanocytic" parameters shown by pigmented seborrheic keratoses: a finding which is not uncommon in dermoscopy. *Dermatol Surg*. 2002;28(8):776-9.
9. Yoradjian A, Cymbalista NC, Paschoal FM. Queratose seborreica simuladora de melanoma. *Surg Cosmet Dermatol*. 2011;3(2):169-71.