

HISTOLOGICAL STUDY OF LIZARD KIDNEY (*Uromastyx microlopis*).

Nidaa Hamdi Khalef *

Thekra Ata*

* Dept. of Biology - College Of Al_ Razi Education - University of Diyala .

ABSTRACT

The aim of the study was determine of histological structure of four of lizard kidney (*Uromastyx Microlepis*) from two sex. Histological study showed that the cortical and medullary layers have not distinguished limit between them ,also the kidney have few of nephron is loss of loop of henle ,each nephron consiste of glomerulae surrounded by Bowman's capsule , the other segment is the neek tubule , proximal segment,intermediate segmente,distal segment and collecting tubules .The epithelial lining of these segments (tubules) are simple cubiodal cells, low columner cells , cubiodal,,and low cubiodal cells respectively.

INTRODUCTION

The kidneys of reptiles are restricted to the posterior of the abdominal cavity and are usually confined to the pelvic region .They are generally small and compact , with alobulated surface(Jacobson, 2007). The posterior portion narrows down on each side , and in some Lizards the hind parts may even Fuse (Weichert and Presch, 1989)(Ahmed , 1998) . The color of kidney ranges from light to dark brown (Jacobson, 2007). Kidney of Lizards composed from urinary units with blood vessels and tubules , all of them surrounded by connective tissue (Ahmed, 1998).

As in other vertebrate groups, the structural and functional unit of the reptile kidney is the nephron (Bradshaw, 2002) . While the human kidney has approximately 2 Million nephrons in each kidneys , Reptiles kidney typically have only a few thousand nephrons . Renal corpuscul consist of a Bowman's capsule and glomerulas are present in the majority of reptiles (Jacobson, 2007; Davis et al. 1976) . Reptilian nephrons are small without a loop of Henley (Edward, 1998) . Although snakes and Lizared have many glomerular tubules , and glomerular have small diameter (40-70) nm and are few in number (Mcnab, 2002) .

Received for publication April 11 , 2010 .

Accepted for publication September 19 , 2010 .

The few and small renal corpuscles of Lizard are composed of tuft of three to four capillaries (glomerulus), Bowman's capsule and mesangium (Gabri and Butler, 1984 ; Jin *et al.* 1995) also Bowman's capsule consist of outer capsular epithelium (parietal) and an inner glomerular epithelium (visceral) (Jacobson, 2007 ; Gabri and Butler, 1984) . Several Segments of reptiles nephron can be histologically distinguished .Beginning with Bowman's capsule the non secretory neck segment composed of cuboidal cell (many having cilia) continues with the next segment of the renal nephron (Jacobson, 2007 ; Ahmed, 1998 ; Davis,et al. 1976) .

The neck segment is followed by the proximal segment called of proximal tubules ,the proximal tubules is lined by low columnar cells, those cells lack cilia but have well-developed microvillus on their luminal surface which called brush border . The next segment called of Intermediate segment , has an initial ciliated region that is followed by an area of mucus cells. The cells of this segment , while in appearance to those of the neck segment , this leads to the distal segment , which different to proximal tubules in have large lumen , absent the brush border and lining by cuboidal cells, fallowed by collecting duct which lining by short columnar cells (Ahmed, 1998 ; Jacobson, 2007) . The cytoplasm was slightly granular in appearance and have larger lumen (Davis et al. 1976).

In product seasonal the intermediate segment collecting ducts in male dimorphic to sexual segment , have secretory natural `(Ahmed , 1998).

The aim of these study to showed the histological structure of the lizard kidney which different from mammalian kidney.

MATERIALS AND METHODS

Four adult Lizards (*uromastys microlepis*) from both sexes were collected from Al_gazal market in Baghdad ,the lizards were killing and dissected ,the kidney was removal and small pieces were fixed in 10% formalin (Vacca, 1985). The fixed samples were washing and dehydrated in ascending series of ethanol, cleared in xyline and embedded in paraffin wax .Sections of 6mm thickness were cut , mounted and stained with mayers hematoxlyin and eosin for microscopically examination (Luna,1968).

RESULTS AND DISCUSSION

The transverse sections of the Lizard kidney showed that the kidney surrounded by very thin capsule , composed of reticular Fiber and smooth muscle (Figure 1),few of nephrons loss of loop of Henley and urinary tubules all of was

connected by connective tissue (Figure 2). The light Microscopic examination was revealed that the reptiles glomerulae consisted of a simpler system of capillary loops, with connective tissue, surrounded by Bowman's capsule which has two layers containing an outer (parietal layer) and an inner (visceral layer) (Figure 3). The results showed that reptiles glomerulas have two poles, urinary pole and vascular pole (Figure 3).

In histology section of reptiles kidney, three types of tubular segments are found in the stroma of kidney tissue: the first is the neck tubules which are lined by cuboidal cells (Figure 4), and the proximal convoluted tubule is lined by low columnar cells with round nuclei and well-developed microvilli on their luminal surface, called brush border (Figure 5). The next tubule is the intermediate tubule, lined by cuboidal cells, followed by the distal convoluted tubule, which is characteristically different from the proximal convoluted tubules in its lining epithelial cells, which are cuboidal and have lost their microvilli, and their lumen is larger (Figure 4).

The result appeared that the collecting duct is lined by low columnar cells, and has a large lumen (Figure 6).

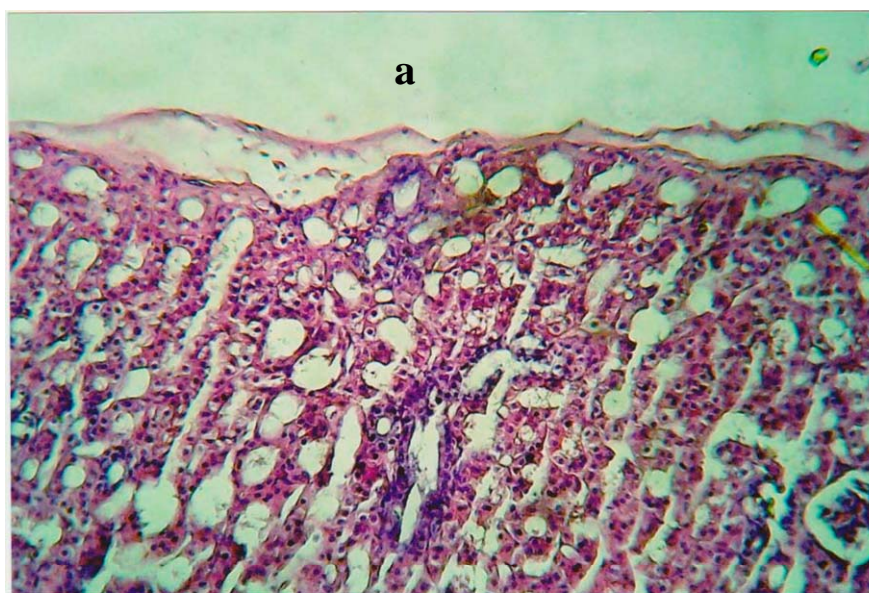


Figure 1. *Transverse section of the kidney of lizard showed that the thin capsule surrounded by tissue a 10x (H & E).*

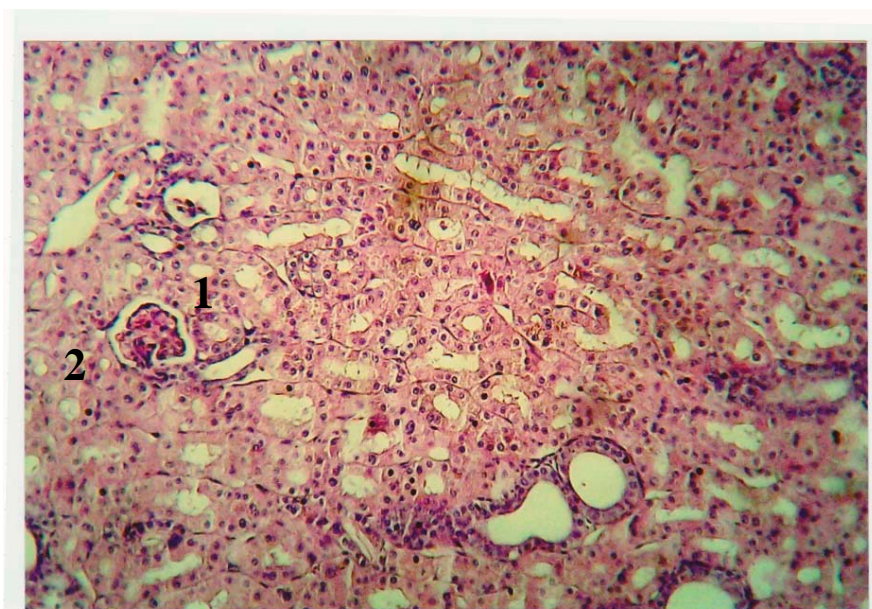


Figure 2. *Transverse section of lizard kidney showed that few nephrons (1) and connective tissue surrounded by urinary tubules (2) 10_x (H& E).*

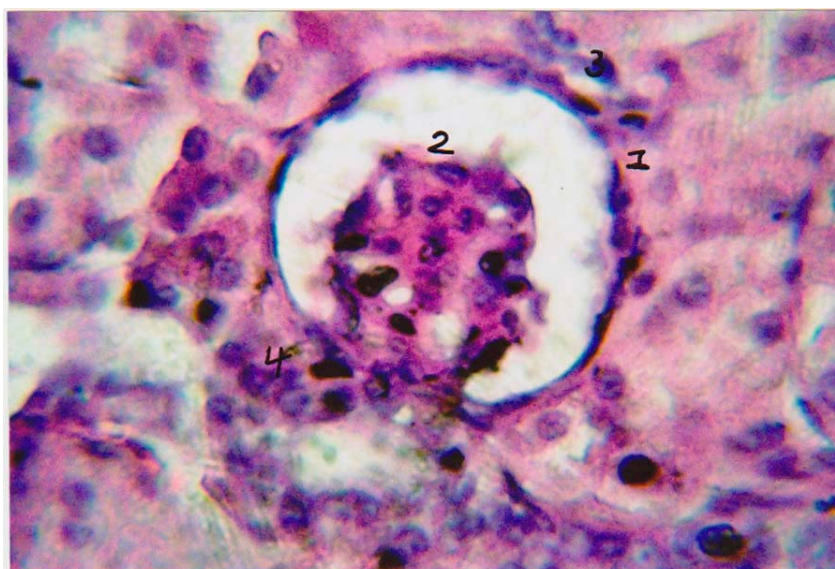


Figure 3 . *Transverse section of Reptiles glomerulae and Bowman's capsule showed parietal layer (1) ,Visceral layer (2),urinary pole (3) and Vascular pole (4) 40_x (H&E).*

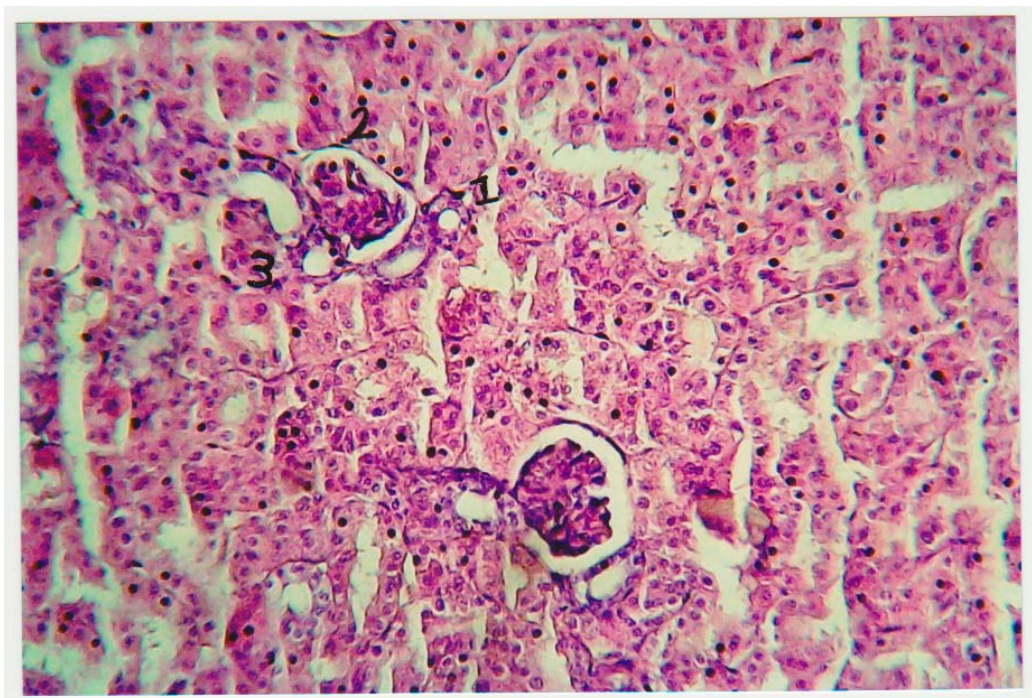


Figure 4. *Transverse section showed neck tubules (1), proximal tubules (2) & distal tubules (3) . (10-x)(H & E) .*

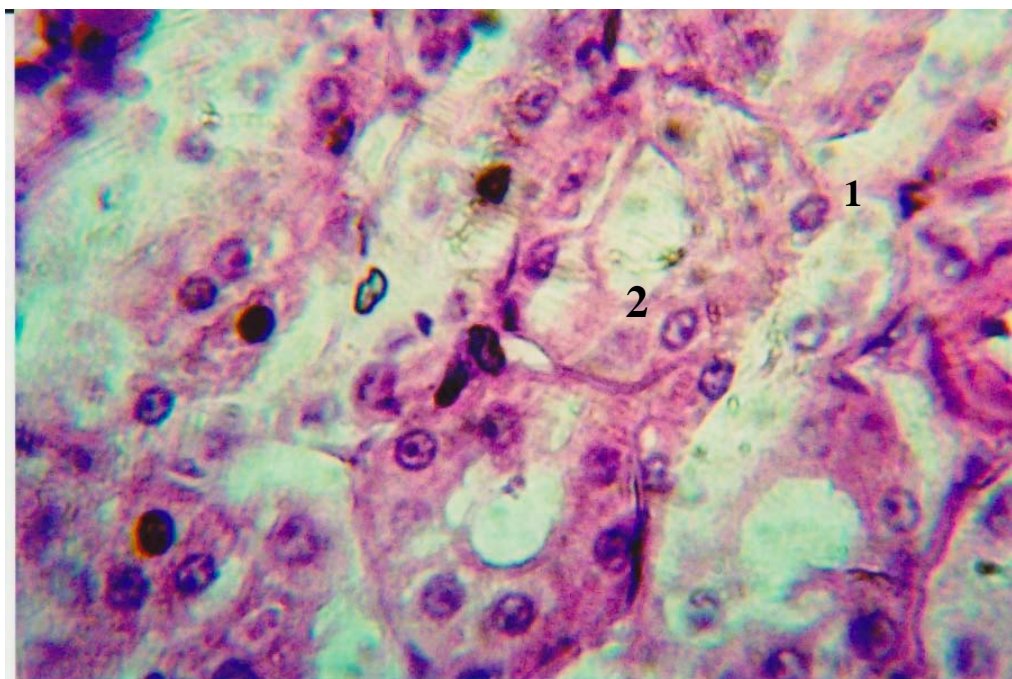


Figure 5. *Transverse section of kidney appeared of Proximal convoluted tubules (1) with brush border microvilli (2) (40-X)(H and E).*

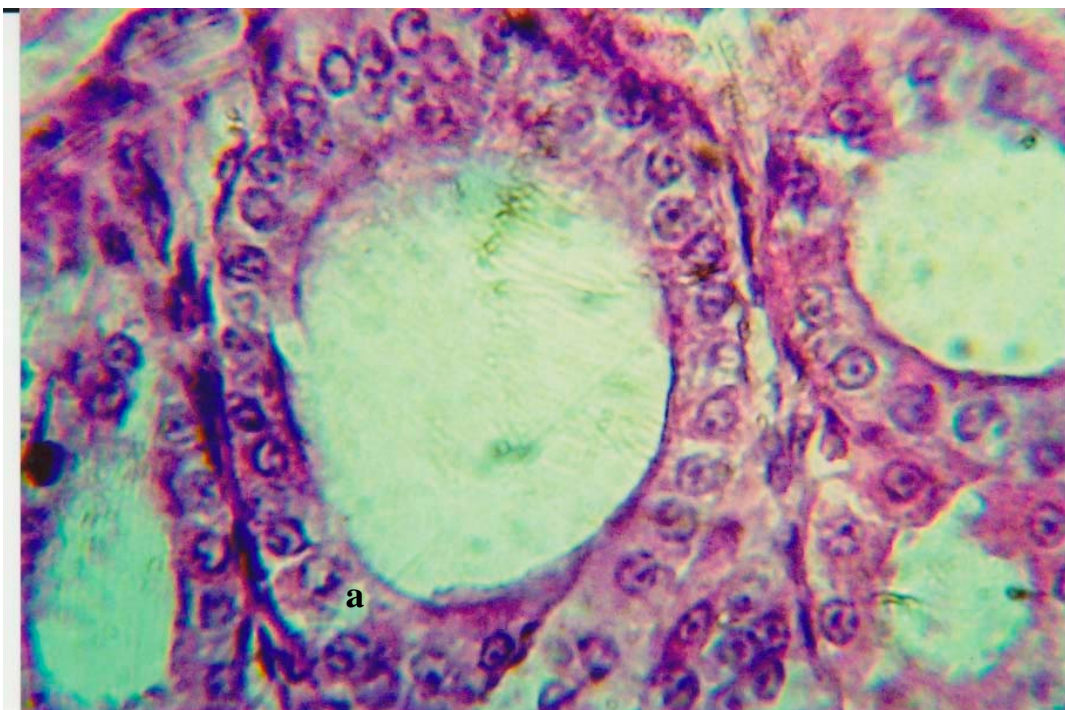


Figure 6. *Transverse section of kidney showed of Collecting duct lining by low columnar cell a .(40-x)(H and E) .*

The present study showed that the cortical and medullary layers have not distinguish limit between them comparing with other vertebrate , also notice very few of nephrons without loop of Henley while of urinary tubules all were connected by connective tissue this agree with Ahmed,(1998) McNab, (2002) and Edward(1998) . The results revealed that the glomerulus of reptile was consisted of simpler system of capillary loops with mesangium ,this results correspond with the McNab(2002) ,Gabri, and Butler(1984) the glomerulae surrounded by Bowman's capsule which have two layer parietal layer and visceral layer , this result was agree with the mention of Jacobson, (2007) and Gabri, and Butler(1984) .

However that three type of segments was consisted of nephron tubules the first is neck tubule lining by cuboidal cell, followed by proximal convoluted tubule which lining by low columner cell have round nuclei and have well developed microvilli in there luminal surface this result agree with Jacobson, (2007) and Ahmed,(1998). The cross section showed that the next tubule is the intermediate tubule which lined by cuboidal cell this followed by distal convoluted tubule which lined by cuboidal cells in shape , have not microvilli and have larger

lumen this results correspond with the result of Jacobson,(2007) ; Ahmed (1998) ; Davis *et al.*(1976) .

This followed by collecting duct lined by low columner cells , and have large lumen , this agree with result of Davis *et al.*(19768) ; Ahmed (1998).

REFERENCES

- Ahmed, S.M. 1998. Anatomical studies on the urinary tract in some species of Lizards , Research , king Abdulaziz University, Faculty of sciences.
- Bradshaw, S.D. .2002. Arginine Vasotocin :site and mode of action in the reptilian kidney- *Revue, Journal title*, vol.126, pp-7-13.
- Davis, L.E. N.B. Schmidt, and H. Stolte .1976. Anatomy and ultrastructure of the excretory system of the Lizard , *Sceloporus cyanogenys*. *J. Morphol*, Jul; 149, PP-279-326.
- Edward, M.C. 1998. Evaluating kidney function in Reptiles , united states of America , original Edition .
- Gabri ,M.S. and R.D. Butler .1984. The ultra structure of the renal corpuscle of a lizard .University of Manchester, England Department of zoology , Volume 16 , issue4, page 627-634.
- Jacobson, E.R. 2007. Infection diseases and pathology of Reptiles : color Atlas and textbook ,4 items .
- Jin, S.M. , A.M. Rodrigues , and A.C. desouza, .1995. Histology and histochemistry of the kidney and ureters of the Caiman *corcodilus Yacare* (Daudin 1802)—*Corcodilia Reptilia*). *Rev Bars Bid*. Feb;55 (1);97-103.
- Luna , G. 1968. manual of histological staining method of the Armed forces institute of pathology .3rd –ed – McRwhill, Book- Company –New York .
- Mcnab ,B.K. 2002. The physiological ecology of vertebrates: aview from energetics. Science , New York , page 184.
- Weichert, C.K and W. Presch . 1989. Elements of chordate anatomy .Mc Graw-Hill, inc. New York , fourth edition , page 295.

Vacca, L. 1985. Laboratory Manual Histochemistry , Kaven press-Book, ltd-
New York .

. (*Uromastyx Microlepis*)

*

*

.

-

-

*

(*Uromastyx microlepis*)

,

,

.