

Histopathological and macroscopical considerations of induced experimental periodontitis in rats

Mureșan Ștefana¹, Dreancă Alexandra^{1*}, Andras Nagy¹, Repciuc Călin¹, Purdoiu Robert Cristian¹, Alexandru Raul Pop¹, Pantea Stelian² and Oana Liviu¹.

¹ University of Agricultural Sciences and Veterinary Medicine, Calea Mănăștur no 3-5, 400372, Cluj-Napoca, România stefanamuresan@gmail.com; alexandra.dreanca@usamvcluj.ro; andras.nagy@usamvcluj.ro; calin-cosmin.repciuc@usamvcluj.ro; robert.purdoiu@usamvcluj.ro; alexandru.pop@usamvcluj.ro; oan-aliviu2008@yahoo.com

² University of Oradea, Universității street, no 1, 410087 Oradea, România

* Correspondence: alexandra.dreanca@usamvcluj.ro

Abstract: Ten Wistar male rats were used to induce experimental periodontitis by placing a 5-0 cotton thread ligature at the base of the first superior molar on the left side. Before this phase, the molar went through the process of scaling, rooting and planning. Soft movements of the molar were realized for creating an accumulation of plaque by flattening and resulting in the displacement of the gingival tissue, thus provoking an inflammatory response. After seven days, the ligatures were removed in all ten rats. After 14 days, results obtained showed gross aspects of periodontitis and microscopical lesions as well, installed in the periodontium. In addition, an inflammatory response with bone necrosis and alveolar bone loss was observed microscopically. This study aims to test an experimental protocol of periodontitis confirming the presence of this pathology by gross aspects and histopathological aspects. In conclusion, the tested procedure can provide all the critical biological elements in periodontal disease, representing good features for the biomaterial testing domain.

Keywords: chronic inflammation; dental ligature; bone necrosis.

1. Introduction

Many investigations have been done in the last years trying to search for an appropriate and efficient treatment for periodontal disease, and all the ways of therapy were very developed.

Periodontitis is spread worldwide and can affect a significant majority of both human and animal populations, so pathology needed to be experimentally induced in some species in order to assess all the factors involved in its development accurately and also to be able to test the effectiveness of different methods of therapy, some being experimental or ongoing implementation. Therefore, this experimental study was implemented to test a novel therapy represented by a hydrogel enriched with a photosensitizer and natural essential oils extract (i.e., oregano, frankincense and thieves blend) that could potentially treat and reverse the associated clinical and pathological symptoms.

As a general definition, periodontitis is an inflammatory chronic infectious oral disease caused by specific pathogen agents which lead to the destruction of supporting tissue that supports the teeth; respectively, it causes the loss of the periodontal ligament and, in the end, the loss of the alveolar bone. Clinically this pathology causes symptoms such as gum bleeding, dental laxity and plaque on teeth and could also develop a local inflammation as gingivitis [1,2]

All these symptoms are considered to result from the response of a capable host to exist as a microbial biofilm represented by bacterial pathogens [3]. Serum levels of inflammatory cytokines, such as interleukin-1beta (IL-1 β), interleukin-6 (IL-6), and tumor necrosis factor (TNF), are increased in patients with severe chronic periodontitis [1,4]. There is a great variety of pathogens in the composition of the oral bacterial flora from one subject to another, depending on the species, the age and the cleaning possibilities, as well as the

Received: 18.10.2022

Accepted: 07.11.2022

Published: 15.11.2022

DOI: 10.52331/cvj.v27i2.41



Copyright: © 2022 by the authors. Submitted for possible open access publication under the terms and conditions of the Creative Commons Attribution (CC BY) license (<http://creativecommons.org/licenses/by/4.0/>).

fluctuation of the host response to the interaction of bacterial species, are some of the main reasons why the particular etiology of periodontal disease could not be acknowledged [5–7]. Bacteria are known to be the first etiological agent of periodontal disease, and it has been considered that more than 500 different bacterial species are involved, like *Streptococcus mutans*, *Porphyromonas gingivalis*, *Aggregatibacter actinomycetemcomitans*, etc. [8,9].

A big part of the data published on periodontal disease etiology comes from human medicine research [10]. Periodontitis in domestic animals is almost identical to that found in humans in terms of progression and clinical presentation [11]. The accelerated rate of evolution of this affection reported in pets compared to humans may be caused by poor oral hygiene and the absence of routine dental care [12]. This pathology can suffer some changes depending on the animal's habitat and the genetic predisposition of each organism [13,14].

The aim of this study is: 1) to test the experimental induction of local inflammatory response in males rats by placing a braided ligature on the first superior molar in order to induce periodontitis lesions; 2) to prove the success of inducing the periodontal disease by histopathological aspects, by the presence of neutrophils, demineralization, necrosis and alveolar bone loss [15]; 3) to test the specific effects of biomaterials as hydrogels, also combined with natural extracts and laser therapy, implementing new ways of alternative therapy in the management of periodontal disease in animals in the following studies; 4) creating the possibility of avoidance of the analgesic medications because of their side effects defined by gastrointestinal affections and the emergence of antibiotic resistance when using an antibacterial medication because all these represent ways of conventional methods of treating periodontitis [2,16,17].

2. Materials and Methods

Ten medium weighted males, Wistar rats were used for this experiment. After the clinical exam, consisting of a short evaluation of their general status (i.e., checking the grimace, checking their degree of hydration, checking their appetite, and inspecting their skin), the rats were weighed in order to determine the weight loss that rats may suffer after the step of placing the ligature. The body weight variation was evaluated and monitored every day after the ligature placement for ten consecutive days. This evaluation was realized in order to establish whether there is necessary the implementation of a supportive therapy or adjust this therapy.

Optimal accommodation habitat was ensured throughout the experiment; the rats were housed in the Establishment for Breeding and Use of Laboratory Animals of USAMV (Cluj-Napoca, România) in standard conditions, at a temperature of 22–23 C, humidity 55%, and 12-h light/dark cycle. The rats were kept in plastic cages with free access to standard rodent granular food (Cantacuzino Institute, Bucharest, Romania) and freshwater ad libitum. In addition, an extra hyper lipidic diet (Cantacuzino Institute, Bucharest, Romania) with a smooth consistency for the first days after the surgery procedure was provided.

The rats were allowed to acclimate to the laboratory environment for two weeks. All procedures involving laboratory animals' use followed the European guidelines and rules 337, as established by the EU Directive 2010/63/EU and the Romanian law 43/2014 and were performed by an experienced practitioner. The study protocol was approved by the Research Ethics Committee of the University of Agricultural Sciences and Veterinary Medicine Cluj-Napoca, Romania, and they were authorized by the State Veterinary Authority (aut. No. 306/24.03.2022).

The surgical procedures were performed under the effect of general injectable anesthesia; this was an injectable type for the application of the ligature and was performed by administering the following anesthetic substances: Xylazine (Xilazin Bio 2%; Bioveta, Czech Republic), injectable solution 7,5 mg/kg IM and Ketamine injectable solution (Narkoman Bio 10%; Bioveta, Czech Republic), 75 mg/kg IM. The experimental protocol for inducing periodontitis consisted of the application of a surgical technique in order to position the 5-0 cotton thread ligature (BioSintex; Ilfov, Romania) at the base of the molar. To extract the ligature, seven days later, the following were administered: Midazolam (Dormicum 0.1%; F. Hoffmann-LA Roche Ltd., Switzerland), injectable solution 0.02 mg/kg SC and Ketamine, injectable solution 70 mg/kg IM. The animals were euthanized three weeks post-induction, according to the procedures recommended by Law no. 43/2014, through profound narcosis with Isoflurane (Isoflutek 1000 mg/g; Laboratorios Karizoo

S.A., Spain). The animal was considered dead at the moment of absence of cardiac and respiratory activity. Then the axo-atloid dislocation was performed to ensure the phenomenon's irreversibility if the inducing protocol's side effects significantly weakened the animals; according to the bioethical protocol, they were euthanized before the end of the study period.

As we already mentioned, all rats were weighed to have an effective body condition scoring tool for laboratory animal welfare in the first step.

The second step involved the application of a 5-0 cotton thread ligature (BioSintex; Ilfov, Romania) at the base of the first left superior molar (Fig. 1), previously performing a slight loosening of the gum in the submarginal position and secondary performing a dislocation of the periodontal ligaments (Fig. 2).

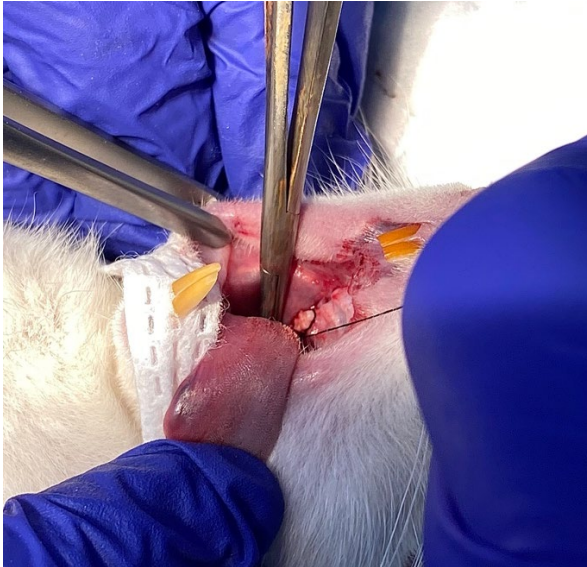


Figure 1. Placing the ligature at the base of the first left upper molar.

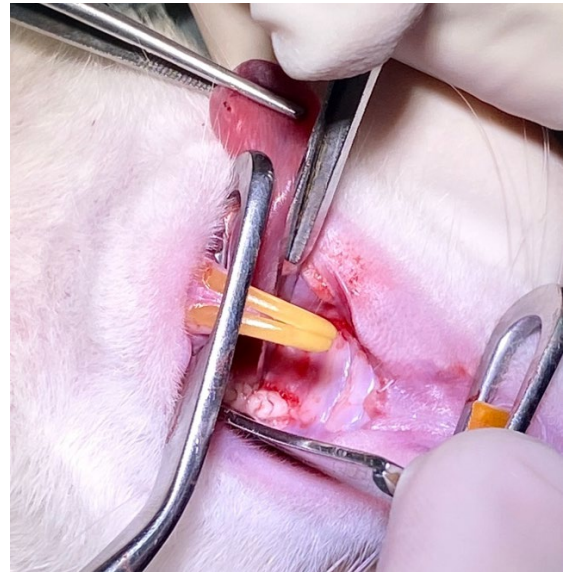


Figure 2. Creating the detachment of the gingiva by performing a slight loosening of the gum.

After the ligature placement (Fig. 3), the rats were evaluated daily, and a pre-determined quantity of specific food consisting of softer consistency hyper lipidic diet (Cantacuzino Institute; Bucharest, Romania) was offered in order to check their post-surgery appetite.

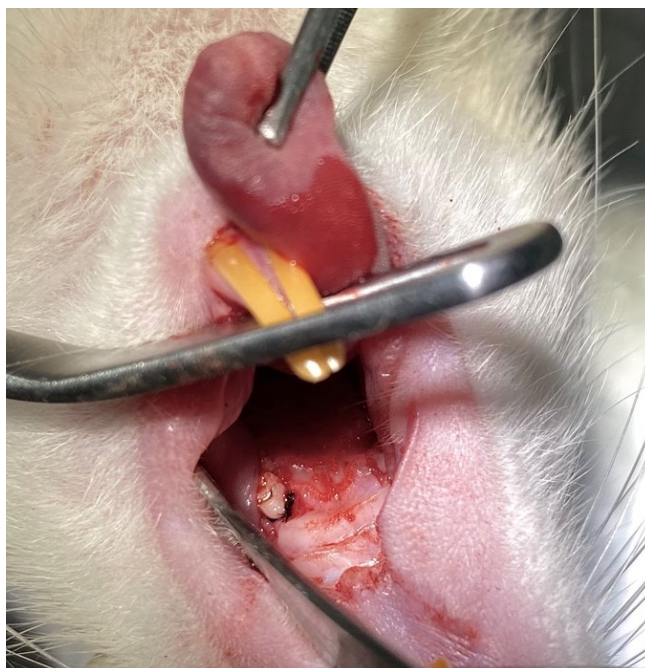


Figure 3. Aspect after the placement of the ligature

In the first two days post-op, a 10% solution of Glucose (B Braun Pharmaceuticals; Melsungen, Germany) injection was administered if they did not eat any food. The analgesia was also managed with an injectable solution of Tramadol (Tramadolum; 50 mg/1 ml Krka D.D., Slovenia). Finally, the third stage took place one week after the ligature was placed, when the rats were anesthetized again with the same anesthetic protocol, and the ligature was removed (Fig. 4).

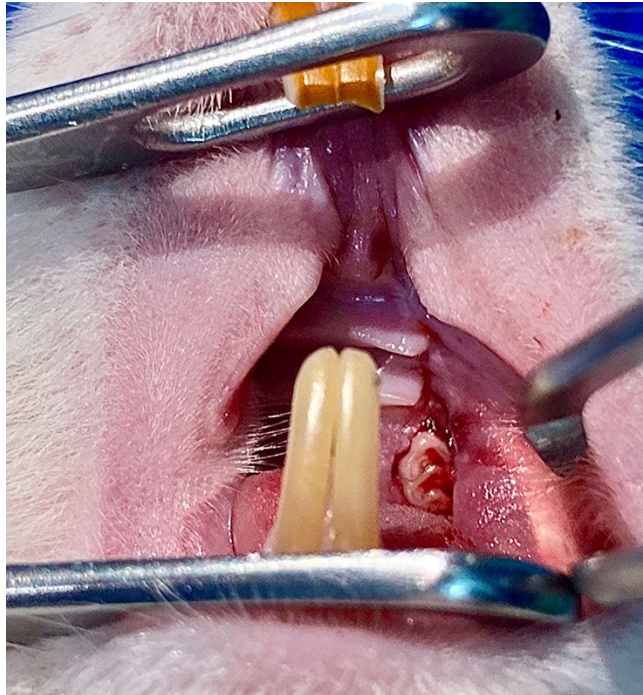


Figure 4. The aspect of the molar after the ligature was removed

This stage was followed by scaling, rooting and planning the affected molar. Next, easy and slight movements of the molar were applied to create an accumulation of bacteria by flattening, resulting in the detachment of the gingival tissue with the help of the dental curettes. The movements were repeated ten times by tractioning the molar in all the lateral planes, thus provoking an inflammatory response.

One week after removing the ligature, the rats were anesthetized again because the computed tomography analysis was performed with a Siemens Somatom Scope machine (SOMATOM Scope, Siemens, Germany) before euthanasia. The anatomical region of interest contained the maxilla of the rats; the targeted region is represented by the soft tissues around the upper left molar, the attachment tissues of the molar and its corresponding dental alveolus. The molars were scanned axially with a thickness of 1 mm, and the recorded images were saved in DICOM (Digital Imaging and Communications in Medicine) format on the Siemens workstation in the PACS server. The analysis of bone density in order to confirm the successful induction of periodontitis at the level of the upper left molar was carried out with the help of the Syngo Somaris 5 CT VC 28 program (Syngo VC 28; Siemens Health Care Sector, Forchheim, Germany).

So the rats were euthanized one week after the ligature was removed, after which the left maxilla was sampled for histopathological analysis to confirm the onset of periodontitis. In addition, gum and bone sampled from the injured site have been submitted for histological examination. After fixation in 10% buffered neutral formalin, the mandibular samples were decalcified using a mix of 1:1 (formic acid and clorhidric acid) for 24 hours and embedded in paraffin. Five-micron thickness sections were stained by the hematoxylin-eosin method (HE). The slides were examined under a BX51 Olympus microscope (Olympus Life Science Europa; Hamburg, Germany), and images were taken with an Olympus UC 30 digital camera (Olympus Life Science Europa; Hamburg, Germany) and processed using Olympus essential stream software. Sections were examined by an independent observer blinded to the experimental protocol.

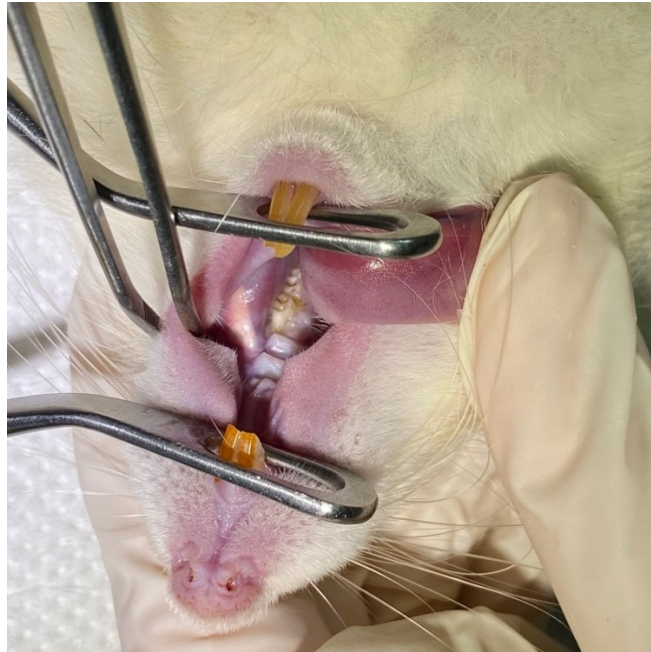


Figure 5. Gross aspects of installed periodontitis - accumulation of the plaque is present, and also discoloration of the molar is visible after seven days

3. Results

Ten rats were subjected to this procedure after the presentation of the protocol described above. Seven days after the experimental protocol, we could see the onset of periodontitis. Gingivitis was observed in five subjects, more moderate, in four others more acute, and in one subject, gingivitis was reduced, so dental laxity was recorded in only nine out of ten rats. This evaluation was performed with the help of the clinical scoring of periodontitis, which implies the mobility scoring and the gingival bleeding performed for each individual [19,20].

Six of ten rats lost weight, with variations ranging from 25 to 60 g, considered a moderate amount. When the rats lose more than 10% of their body weight, euthanasia is considered because this parameter is considered a pain assessment recommendation.

After the euthanasia of all ten rats, a necropsy was performed. Grossly, yellowish discoloration of the molar, mobility within the alveolus and gum reactivity have been observed in nine rats (Fig. 6).

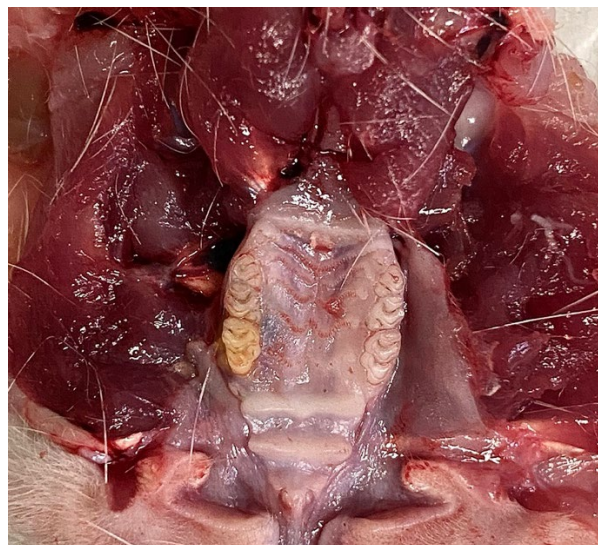


Figure 6. Gross features of periodontitis after euthanasia, represented by yellowish discoloration, gum retraction and reactivity, mobility within the alveolus

Following the histological aspects after the microscopical analysis, the tooth and the periodontal ligament (the periodontium), respectively, the dental alveolar bone, showed a normal appearance for one rat. However, microscopically, lesions such as inflammation, demineralization, thinning, and bone resorption could be seen in nine rats at different stages. A moderate gingival retraction was observed in the cervix of the teeth and the interdental space, and chronic and superficial local gingivitis were completed in eight rats (Fig. 7).

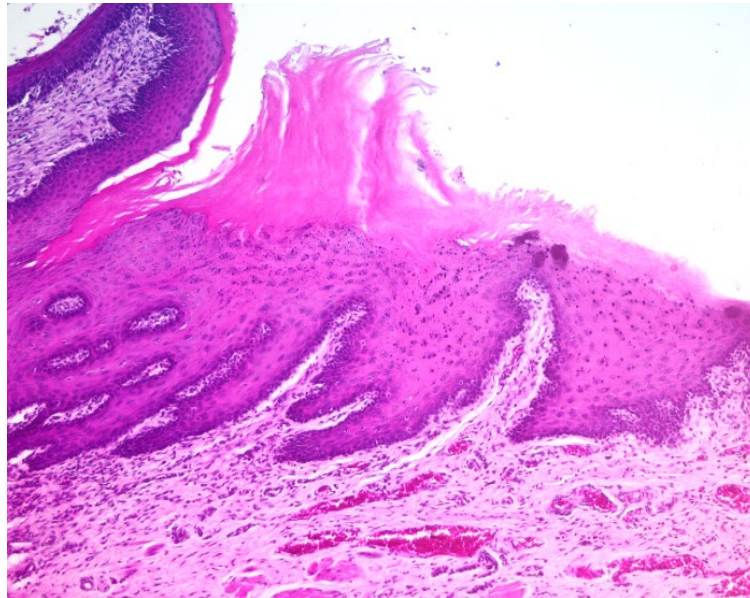


Figure 7. Hyperplasia and severe hyperkeratosis of the gingival epithelium, the subepithelial lamina propria is infiltrated with rare mononuclear cells; HE staining X20

The superficial part of the inflammatory process is covered by a layer represented by bacterially infected tissue and fodder debris. Furthermore, some segmental osteoclastic resorption of the alveolar bone was seen as also suppurative process represented by focal periodontitis extending from the previously described gingival defect (Fig. 8).

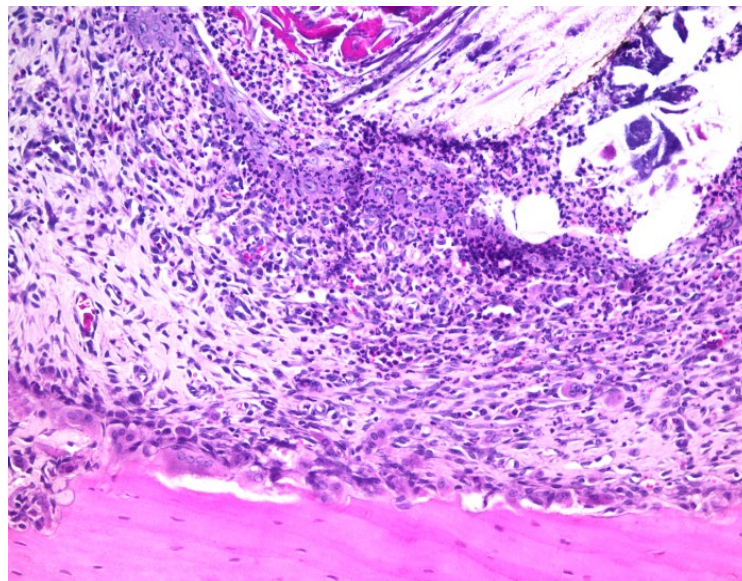


Figure 8. Chronic suppurative gingivitis, moderate-segmental osteoclastic resorption of the alveolar bone; HE staining X10

On the site of the subgingival region, abundant granulation tissue was seen, which could split the septic point and replace the dental ligament. In addition, hyperplasia and hyperkeratosis of the gingival layer with the organization of the anatomic epithelial papillae, divided by a fibro-vascular inflammatory stroma, moderate-segmental osteoclastic resorption of the alveolar bone tissue and periodontitis were observed. The inflammatory process was expressed by multiple bands and degenerated neutrophils combined with mononuclear cells and reactive fibroblasts (Fig. 9).

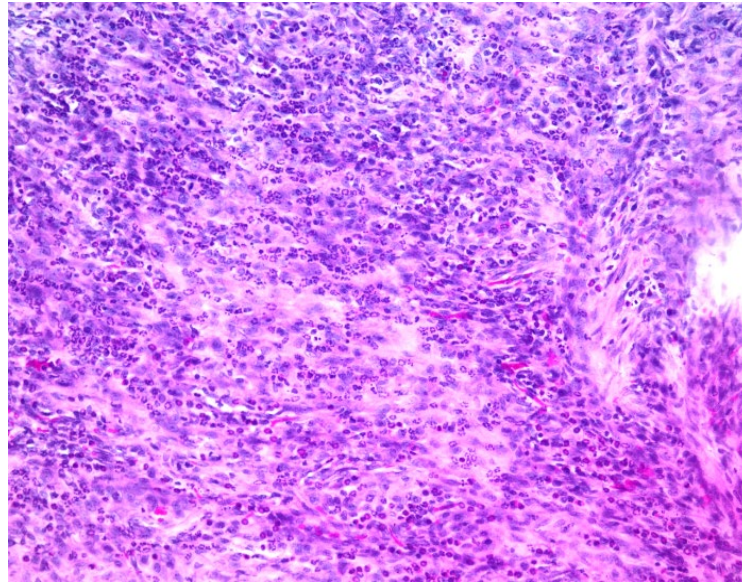


Figure 9. Granulation tissue, inflammatory infiltrate consisting primarily of neutrophils, rare mononuclear cells and reactive fibroblasts; HE staining x20

Also, the presence of hyperplasia and hyperkeratosis in the gingival epithelium layer was observed. Thus, the production of irregular epithelial papillae, divided by abundant inflammatory granulation tissue with neutrophils first and then macrophages, was observed. Furthermore, the superficial gingival area presented a minimal ulcer covered by a cellular layer mixed with cellular debris and nutrients. Fig. 9 also represented aspects of inflammatory granulation tissue with invasive degenerated neutrophils mixed with mononuclear cells and reactive fibroblasts. Gingival epithelial hyperplasia was also noted with hyperkeratosis and a partial replacement of the dental ligament with fibro-vascular connective tissue.

The CT scan showed changes in bone and periodontal tissue (Fig. 10) observed in 8 rats.

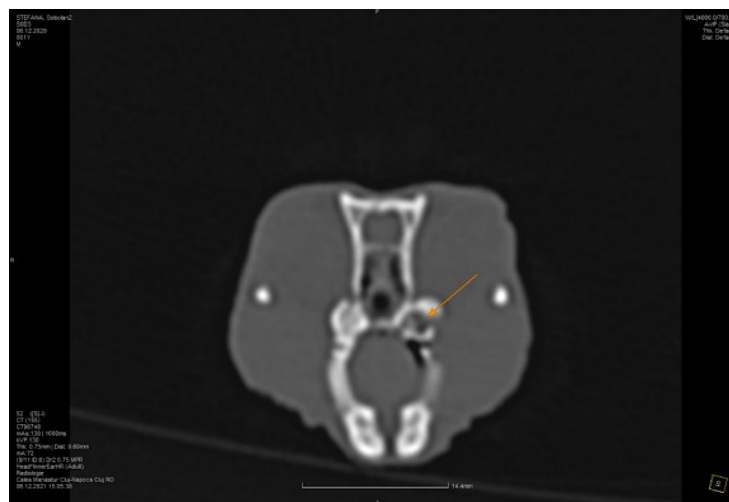


Figure 10. CT images consistent with changes in bone and periodontal tissue, bone necrosis, rarefaction and alveolar bone loss

4. Discussion

The tested procedure can provide all the critical biological factors in periodontal disease, representing good features for the biomaterial testing domain. Currently, ligature-induced periodontitis in rats is the primary model used in periodontal research, and alveolar bone loss is the main parameter evaluated by radiographic, morphometric, and histological techniques [22].

Because of the positioning of the ligature on the superior molar, as an advantage, there was a better resistance of the ligature during the induction of the periodontitis, also because the saliva is accumulated by the gravity reason on the mandibular sides, not on the maxillary ones. The main problem with the experimental techniques of inducing periodontitis consists in the resistance of the ligature on the molar, which may require another intervention of replacing the ligature or adding an extra ligature placed tight. Nevertheless, we succeeded in inducing periodontitis lesions after seven days, demonstrated by gross aspects and microscopical investigations, even if some authors reported that the ligature should be kept in position from 15 to 60 days to induce periodontal destruction [23].

Although we did not investigate the specific parameters of inflammation and necrosis by paraclinical investigations, the macroscopical aspects and the clinical signs were enough to prove and confirm the presence of periodontitis.

Comparative to other techniques described for inducing experimental periodontitis, such as placing a ligature on one of the incisors or on a group of incisors with a ligature on eight, the technique we chose was more stable, more resistant and much safer. Also, compared with another method of inducing experimental periodontitis by creating a lesion on the gum and inoculating an extract of specific periodontitis pathogens [24] [25] on the lesion created, the technique we used did not affect the general health and condition of the rats [26]. The body mass is considered a clinical endpoint, especially in periodontal experimental protocols where the prehension capacity of the animal is intensely affected, and the appetite could be poor. Other clinical endpoints for laboratory animals are their behavior, reluctance to move, dehydration and pain [18]. Alongside food consumption, monitoring these parameters is usually realized once a week and is considered a good practice as part of standard husbandry care [21]. We chose to evaluate and monitor these parameters every day after the ligature placement for ten consecutive days precisely so that we can closely observe the changes that occur during the installation of this pathology.

Another main aim of this research is to demonstrate in the following studies the effectiveness of regenerative therapy with biomaterials, photosensitizing agents and photodynamic therapy, reversing all the effects of periodontitis induced by the initially placed ligature.

5. Conclusions

This study showed that placing a cotton or silk thread around the cervical region of the upper left molar causes gingival inflammation, and the first symptoms of periodontitis developed from the seventh day of the experiment onwards. In the present study, it has been demonstrated that experimental periodontitis has general systemic biological implications; poor body conditions, weight loss secondary to loss of prehension and increased oral pain, and the correlation between periodontal disease and general health. This experimental protocol followed the exact surgical steps by performing ligatures, rooting and scaling and demonstrated gross and microscopic lesions. This article has been created to prove all steps necessary to achieve successful experimental periodontitis explicitly.

Author Contributions: Conceptualization, S.M, A.D. and R.C.; methodology, A.D and S.M.; software, R.P.; validation, A.D., A.N. and A.R.P.; formal analysis, A.N.; investigation, A.R.P. and S.P.; resources, S.M., A.R.P. and S.P.; data curation, R.P.; writing—original draft preparation, S.M. and A.D.; writing—review and editing, S.M and A.D.; visualization, A.N.; supervision, L.O.; project administration, L.O. All authors have read and agreed to the published version of the manuscript".

Acknowledgments: This work was supported by the project "The Development of Advanced and Applicative Research Competencies in the Logic of STEAM + Health"/POCU/993/6/13/153310, a project co-financed by the European Social Fund through The Romanian Operational Programme Human Capital 2014-2020.

Conflicts of Interest: All procedures involving laboratory animals' use followed the European guidelines and rules 337, as established by the EU Directive 2010/63/EU and the Romanian law 43/2014 and were performed by an experienced

practitioner. The study protocol was approved by the Research Ethics Committee of the University of Agricultural Sciences and Veterinary Medicine Cluj-Napoca, Romania, and they were authorized by the State Veterinary Authority (aut. No. 306/24.03.2022).

References

1. Lorencini, M.; Silva, J.A.F.; Almeida, C.A.; Bruni-Cardoso, A.; Carvalho, H.F.; Stach-Machado, D.R. A New Paradigm in the Periodontal Disease Progression: Gingival Connective Tissue Remodeling with Simultaneous Collagen Degradation and Fibers Thickening. *Tissue Cell* 2009, *41*, 43–50, doi:10.1016/J.TICE.2008.07.001.
2. Goyal, G.; Garg, T.; Rath, G.; Goyal, A.K. Current Nanotechnological Strategies for an Effective Delivery of Drugs in Treatment of Periodontal Disease. *Critical Reviews & Trade; in Therapeutic Drug Carrier Systems* 2014, *31*, 89–119, doi:10.1615/CRITREVTHERDRUGCARRIERSYST.2014008117.
3. Prates, R.A.; Yamada, A.M.; Suzuki, L.C.; França, C.M.; Cai, S.; Mayer, M.P.A.; Ribeiro, A.C.; Ribeiro, M.S. Histomorphometric and Microbiological Assessment of Photodynamic Therapy as an Adjuvant Treatment for Periodontitis: A Short-Term Evaluation of Inflammatory Periodontal Conditions and Bacterial Reduction in a Rat Model. *Photomed Laser Surg* 2011, *29*, 835, doi:10.1089/PHO.2010.2984.
4. Struillou, X.; Boutigny, H.; Soueidan, A.; Layrolle, P. Experimental Animal Models in Periodontology: A Review. *Open Dent J* 2010, *4*, 37–47, doi:10.2174/1874210601004010037.
5. Chen, X.; Wu, G.; Feng, Z.; Dong, Y.; Zhou, W.; Li, B.; Bai, S.; Zhao, Y. Advanced Biomaterials and Their Potential Applications in the Treatment of Periodontal Disease. *Crit Rev Biotechnol* 2016, *36*, 760–775, doi:10.3109/07388551.2015.1035693.
6. Dobson, J.; Wilson, M. Sensitization of Oral Bacteria in Biofilms to Killing by Light from a Low-Power Laser. *Arch Oral Biol* 1992, *37*, 883–887, doi:10.1016/0003-9969(92)90058-G.
7. Graves, D.T.; Fine, D.; Teng, Y.T.A.; van Dyke, T.E.; Hajishengallis, G. The Use of Rodent Models to Investigate Host-Bacteria Interactions Related to Periodontal Diseases. *J Clin Periodontol* 2008, *35*, 89–105, doi:10.1111/J.1600-051X.2007.01172.X.
8. Booi-Vrieling, H.E.; van der Reijden, W.A.; Houwers, D.J.; de Wit, W.E.A.J.; Bosch-Tijhof, C.J.; Penning, L.C.; van Winkelhoff, A.J.; Hazewinkel, H.A.W. Comparison of Periodontal Pathogens between Cats and Their Owners. *Vet Microbiol* 2010, *144*, 147–152, doi:10.1016/J.VETMIC.2009.12.046.
9. Graves, D.T.; Fine, D.; Teng, Y.T.A.; van Dyke, T.E.; Hajishengallis, G. The Use of Rodent Models to Investigate Host-Bacteria Interactions Related to Periodontal Diseases. *J Clin Periodontol* 2008, *35*, 89–105, doi:10.1111/J.1600-051X.2007.01172.X.
10. Maeda, H.; Fujii, S.; Tomokiyo, A.; Wada, N.; Akamine, A. Periodontal Tissue Engineering: Defining the Triad. *Int J Oral Maxillofac Implants* 2013, *28*, e461–e471, doi:10.11607/JOMI.TE26.
11. Oz, H.S.; Puleo, D.A. Animal Models for Periodontal Disease. *J Biomed Biotechnol* 2011, *2011*, doi:10.1155/2011/754857.
12. García-Salinas, S.; Elizondo-Castillo, H.; Arruebo, M.; Mendoza, G.; Irusta, S. Evaluation of the Antimicrobial Activity and Cytotoxicity of Different Components of Natural Origin Present in Essential Oils. *Molecules* 2018, *23*, doi:10.3390/molecules23061399.
13. Ripamonti, U.; Renton, L. Bone Morphogenetic Proteins and the Induction of Periodontal Tissue Regeneration. *Periodontol 2000* 2006, *41*, 73–87, doi:10.1111/J.1600-0757.2006.00155.X.
14. Andersen, M.L.; Winter, L.M.F. Animal Models in Biological and Biomedical Research - Experimental and Ethical Concerns. *An Acad Bras Cienc* 2019, *91*, doi:10.1590/0001-3765201720170238.
15. Partata Zuza, E.; Gouveia Garcia, V.; Helena Theodoro, L.; Ervolino, E.; Fernando Veloso Favero, L.; Longo, M.; Salimon Ribeiro, F.; Tadeu Martins, A.; Carlos Spolidorio, L.; Antônio Sampaio Zuanon, J.; et al. Influence of

- Obesity on Experimental Periodontitis in Rats: Histopathological, Histometric and Immunohistochemical Study., doi:10.1007/s00784-017-2207-y.
16. Ausenda, F.; Rasperini, G.; Acunzo, R.; Gorbunkova, A.; Pagni, G. New Perspectives in the Use of Biomaterials for Periodontal Regeneration. *Materials (Basel)* 2019, *12*, doi:10.3390/MA12132197.
 17. Charles, C.H.; Mostler, K.M.; Bartels, L.L.; Mankodi, S.M. Comparative Antiplaque and Antigingivitis Effectiveness of a Chlorhexidine and an Essential Oil Mouthrinse: 6-Month Clinical Trial. *J Clin Periodontol* 2004, *31*, 878–884, doi:10.1111/J.1600-051X.2004.00578.X.
 18. Hickman, D.L.; Swan, M. Use of a Body Condition Score Technique to Assess Health Status in a Rat Model of Polycystic Kidney Disease Available online: <https://pubmed.ncbi.nlm.nih.gov/20353688/>.
 19. Dhingra, K.; Vandana, K.L. Indices for Measuring Periodontitis: A Literature Review. *Int Dent J* 2011, *61*, 76–84, doi:10.1111/J.1875-595X.2011.00018.X.
 20. Deng, N.; Xie, L.; Li, Y.; Lin, H.; Luo, R. Oxymatrine Alleviates Periodontitis in Rats by Inhibiting Inflammatory Factor Secretion and Regulating MMPs/TIMP Protein Expression. *Acta Cir Bras* 2018, *33*, 945–953, doi:10.1590/S0102-865020180110000001.
 21. Turner, P. v.; Pang, D.S.J.; Lofgren, J.L.S. A Review of Pain Assessment Methods in Laboratory Rodents. *Comp Med* 2019, *69*, 451–467, doi:10.30802/AALAS-CM-19-000042.
 22. Katherine VARGAS-SANCHEZ, P.; Goetz MORO, M.; André dos SANTOS, F.; Lia ANBINDER, A.; Kreich, E.; Mendonça MORAES, R.; Padilha, L.; Kusiak, C.; Xavier SCOMPARIN, D.; Cesar Nobre FRANCO, G.; et al. (No Title). *J Appl Oral Sci* 2017, *25*, 490–497, doi:10.1590/1678-7757-2016-0517.
 23. Duarte, P.M.; Tezolin, K.R.; Figueiredo, L.C.; Feres, M.; Bastos, M.F. Microbial Profile of Ligature-Induced Periodontitis in Rats. *Arch Oral Biol* 2010, *55*, 142–147, doi:10.1016/J.ARCHORALBIO.2009.10.006.
 24. Aguirre, J.I.; Akhter, M.P.; Kimmel, D.B.; Pingel, J.; Xia, X.; Williams, A.; Jorgensen, M.; Edmonds, K.; Lee, J.Y.; Reinhard, M.K.; et al. Enhanced Alveolar Bone Loss in a Model of Non-Invasive Periodontitis in Rice Rats. *Oral Dis* 2012, *18*, 459–468, doi:10.1111/J.1601-0825.2011.01893.X.
 25. Zhang, W.; Ju, J.; Rigney, T.; Tribble, G. Porphyromonas Gingivalis Infection Increases Osteoclastic Bone Resorption and Osteoblastic Bone Formation in a Periodontitis Mouse Model. *BMC Oral Health* 2014, *14*, 89, doi:10.1186/1472-6831-14-89.
 26. Oktay, S.; Chukkapalli, S.S.; Rivera-Kweh, M.F.; Velsko, I.M.; Holliday, L.S.; Kesavalu, L. Periodontitis in Rats Induces Systemic Oxidative Stress That Is Controlled by Bone-Targeted Antiresorptives. *J Periodontol* 2015, *86*, 137, doi:10.1902/JOP.2014.140302.