

Case report

Splenic hematoma and pelvic bladder in a spayed German shepherd mongrel bitch (*Canis lupus familiaris*). A case report.

Iosif VasIU^{1,*}, †, Valentin Nicușor Oros¹, †, Andreea Niculina Aștilean¹, Iulia Melega¹, Andreea Rusu², Robert Purdoi³, Flaviu Tăbăran⁴, Mariana VasIU⁵, Emanuel Mihai Mocanu⁶, and Ciprian Andrei Ober¹

¹Department of Anaesthesiology and Surgery, University of Agricultural Sciences and Veterinary Medicine Cluj-Napoca, Faculty of Veterinary Medicine, 3-5 Mănăștur Street, Cluj-Napoca, 400372, Romania iosif.vasiu@usamvcluj.ro; nicusor-valentin.oros@usamvcluj.ro; andreea-niculina.astilean@usamvcluj.ro; iulia.melega@usamvcluj.ro; ciprian.ober@usamvcluj.ro

²Small Animals Emergency Hospital, University of Agricultural Sciences and Veterinary Medicine Cluj-Napoca, Faculty of Veterinary Medicine, 3-5 Mănăștur Street, Cluj-Napoca, 400372; andreearusu@yahoo.com

³Department of Imagistics and Internal Diseases, University of Agricultural Sciences and Veterinary Medicine Cluj-Napoca, Faculty of Veterinary Medicine, 3-5 Mănăștur Street, Cluj-Napoca, 400372 robert.purdoi@usamvcluj.ro

⁴Department of Pathology, University of Agricultural Sciences and Veterinary Medicine Cluj-Napoca, Faculty of Veterinary Medicine, 3-5 Mănăștur Street, Cluj-Napoca, 400372, Romania flaviutabaran@gmail.com;

⁵Bioclinica, 10 Ștrandului Street, Sibiu, 550068, Romania mariannvasiu@yahoo.com

⁶Fia Vet, 1 Fragilor Street Sibiu, 550246, Romania mihai_vetmocanu@yahoo.com

* Correspondence: iosif.vasiu@usamvcluj.ro

† These authors contributed equally to the article.

Abstract: Splenic hematomas represent the most encountered splenic benign masses in dogs (*Canis lupus familiaris*), and they are usually secondary to splenic nodular hyperplasia. In most spayed bitches with urinary incontinence (UI), pelvic bladders are a common finding. In addition, ovariohysterectomy (OHE), hormonal imbalances, and various anatomical anomalies are responsible for the onset of urethral sphincter mechanism incompetence (USMI). This case report highlights the aggravating aspect caused by a splenic hematoma to develop a pelvic bladder in a mongrel bitch, that was sterilized seven years ago. A 14-years-old spayed German shepherd was presented to the Emergency Veterinary Hospital in Cluj-Napoca, with a history of apathy, incontinence, and foul kennel smell, for several months. The diagnostic was based on anamnesis, medical history, imagistic, and routine laboratory assays. The main findings were the presence of a pelvic bladder, splenic hematoma, and chronic cholecystitis. The bitch was admitted for 14 days. Surgical intervention was required, so a splenectomy was performed. Besides the surgical management and the supportive care, the bitch also received treatment for UI with phenylpropanolamine (PPA; Propalin 5%; 1.2 mg/kg 12h PO *prn*). Three days after surgery and treatment, the bitch recovered the urinary tonus, and UI was absent. The bitch was discharged two weeks after the surgical intervention. Splenic hematomas can precipitate the development of UI by partially translocating the urinary bladder into the pelvic cavity (i.e., pelvic bladder), especially in old spayed bitches.

Received: 21 February 2022

Accepted: 22 March 2022

Published: 28 June 2022

Keywords: *Canis lupus familiaris*; splenic hematoma; pelvic bladder; OHE; UI; USMI.

DOI:10.52331/cvj.v27i1.36

1. Introduction

Urinary incontinence represents an uncontrolled or involuntary urine leakage during the storage phase of micturition [1,2]. It is a common pathology in both intact (i.e., 02-0.3%) and spayed bitches (i.e., 20%) [2]. Usually, females with acquired UI suffer from USMI [3,4]. However, the pathophysiology is multifactorial but incompletely elucidated, with OHE, weight, breed, age, and anatomical anomalies as primary contributing factors [5,6]. Nevertheless, the condition comprises hormonal, structural, and functional derangements [2].

Neurogenic factors comprise low and upper motor neuron disorders; detrusor urethral dyssynergia, dysautonomia, and primary bladder atony. Non-neurogenic urinary incontinence (i.e., USMI) includes congenital disorders, detrusor hyperreflexia, anatom-



Copyright: © 2022 by the authors. Submitted for possible open access publication under the terms and conditions of the Creative Commons Attribution (CC BY) license (<http://creativecommons.org/licenses/by/4.0/>).

ical or functional urethral obstruction leading to secondary bladder atony, and bladder atony due to muscle weakness or medications [2]. Usually, all females suffer from acquired USMI. In addition, USMI and anatomical anomalies may coexist [7].

Nodular lymphoid hyperplasia (NLH) and hematomas are benign, non-neoplastic focal masses [8,9] commonly encountered as splenic or hepatic lesions in older dogs, with a reported incidence between 38-59% and account for most focal canine splenic masses [10,11]. They can also be associated with other splenic or hepatic nodules [12].

Nodular lymphoid hyperplasia is cytologically characterized as a mixed lymphoid population with medium to small lymphocytes, lymphoblasts, few plasma cells, and other cells with no signs of malignancy on smears [8].

Splenic hematomas are blood collections within the tissue, mainly in lymphoid follicular hyperplasia areas with lymphoid aggregates. The coexistence of splenic hematomas and hyperplasia is common in dogs. Usually, splenic hematomas result from NLH since it disrupts local blood flow, causing blood pooling, hypoxia, bleeding, and necrosis. Usually, dogs with splenic hematomas survive the postoperative period and have an excellent outcome [10,12–14].

In the present case, we highlight the potential of splenic masses to increase abdominal pressure on urinary bladders, causing USMI-derived UI by partially translocating the bladder into the pelvic cavity in a sterilized 14-years-old mixed German shepherd bitch.

2. Materials and Methods

2.1. Case description

A 22 kg, nulliparous 14-year-old spayed German shepherd mixed breed female was presented to the Small Animal Emergency Hospital in Cluj-Napoca with a history of apathy, weakness, polyuria (PU), and foul urinary smell kennel for several months. In addition, the owner noticed the dog urinating while sitting or sleeping on the kennel floor, and the hindlimbs were always soaked in urine. The bitch was presented to the same hospital seven years ago for sterilization. At the same time, the bitch was diagnosed with recurrent bilateral otitis (i.e., *Pseudomonas aeruginosa*) due to a food allergy. Besides the treatment received for the food allergy (Posatex, Vet Pharma Friesoythe, Germany; Enrofloxacin; Baytril, USA; and Hypoallergenic food, Royal Canin, France) and the vets' regular visits for deworming and vaccination, the bitch had no other medical history.

During the check-up, the bitch was panting (R=100), presented bilateral senile cataract, enlarged mandibular and popliteal lymph nodes, a distended and sensitive abdomen, and vulval scalding. The bitch showed normal lung and heart sounds, pink mucosae membranes, and other vital signs within the physiological limits (P=100; T=39.2°C; TRC=1 "). From the cephalic *vena*, blood was collected for total solids (TS) (Element RC, Scil, Germany), a complete blood count (CBC) (VetScan, Abaxis, UK), and blood gases (Prime VET, Nova Biomedical, USA) assays.

An abdominal splenic space-occupying lesion was discovered on ultrasound (MyLabDeltaVet, Esaote, Italy); a computed tomography (CT) was recommended. In addition, an echo-guided urine sample was obtained aseptically from the urinary bladder, and a stool sample was collected for coproparasitological evaluation. The specimens were sent to the Microbiology, Pathology, and Parasitology Departments (University of Agricultural Sciences and Veterinary Medicine, Cluj-Napoca) for culture, sensitivity, sediment, cytology, and stool interpretation, respectively.

2.2. Anesthetic and CT protocol

A 20G safety IV catheter (B. Braun Melsungen, Germany) was placed on the anterior right limb, and a lactated Ringer's solution (Ringer-Lactat, B. Braun Melsungen, Germany; 10 ml/kg/h IV) was administered. The bitch was premedicated with midazolam

(Dormicum 0.1%, F. Hoffmann-LA Roche Ltd., Switzerland; 0.2 mg/kg IV) and ketamine (Narkamon Bio 10%, Bioveta, Czech Republic; 1.5 mg/kg IV). Next, the dog was induced with propofol (Propofol-Lipuro 1%, B. Braun Melsungen, Germany; 3 mg/kg IV) and maintained with isoflurane/oxygen (Isoflutek 1000 mg/g, Laboratorios Karizoo S.A., Spain) after endotracheal intubation using a 9.0 mm endotracheal tube (Well Lead Medical Co. Ltd., China). Finally, an abdominal and thoracic contrast CT scan (SOMATOM Scope, Siemens, Germany) with iohexol (Omnipaque 35%, GE Healthcare AS, Norway; 2 ml/kg IV) was performed under general anesthesia.

2.3. Anesthetic and surgery protocol

After the imagistic evaluation, it was decided to perform an exploratory laparotomy on the same day. The bitch was premedicated with pethidine (Mialgin 5%, Zentiva, Romania; 4 mg/kg IM in one dose) and midazolam (0.3 mg/kg IV). Anesthesia was induced with ketamine (2 mg/kg IV) and propofol (2-4mg/kg IV) and was maintained with isoflurane and oxygen mixture (MAC=0.9%-1%). The dog received during the surgery a constant rate infusion (CRI) of lidocaine (Xilină 2%, Zentiva S.A., Romania; 2.4 mg/kg/h, 24h IV) and ketamine (0.6 mg/kg/h, 24h IV), in Ringer's perfusion.

Next, the bitch was placed in dorsal recumbency and was aseptically prepped on the ventral aspect of the abdomen with chlorhexidine 2% (Lifo-Scrub 2%, B. Braun Melsungen, Germany) and isopropyl alcohol (Alcool Sanitar 70%, Dual Prod, Romania). In addition, a midline abdominal anesthetic blocage was also performed with bupivacaine on the *linea alba* (Bupivacaină 0.5%, Infomed Fluids SRL, Romania; 1 mg/kg SC). During the surgical intervention, all the vital signs, including pulse oximetry, ECG, and capnography, were evaluated with a noninvasive multi-parameter monitor (Life Vet 8c, Eickemeyer, Germany).

A ventral midline abdominal incision was performed from xiphoid to pubis for complete abdominal exploration. The edges of the incision were protected with abdominal pads. Approximately 100 ml of hemorrhagic fluid was present in the abdominal cavity. The spleen was exteriorized and appeared larger in volume, with macroscopic structures in the parenchyma (Figure S1). The capsule was not intact. The liver also presented small reddish nodules on the surface. After the abdominal cavity was explored, the spleen was removed, and a hepatic biopsy was collected. Both specimens were rushed to the Pathology Department for further histopathological evaluation.

The blood vessels were double ligated and transected with 3-0 Poldioxanone monofilament absorbable (PDO; BioSintex, Ilfov, Romania) suture material at the splenic hilus. Next, the abdominal wall was closed in three layers. First, the aponeurosis of the *rectus abdominis* muscle was sutured with a simple interrupted pattern with 2-0 PDO (BioSintex, Ilfov, Romania) suture material; the subcutaneous connective tissue was sutured in a continuous surjet and tied with an Aberdeen knot with 2-0 PDO (BioSintex, Ilfov, Romania) suture material. Finally, the skin suture was performed with a simple "X" pattern with a 2-0 nylon (BioSintex, Ilfov, Romania) suture material. The surgical procedure lasted 45 minutes, and no complications occurred.

2.4. Treatment plan

The lidocaine and ketamine CRI was continued for 24h, and the post-op protocol consisted of administration of ceftriaxone (Cefort 100%, Antibiotice, Romania; 22 mg/kg 12h IV for 10 days), metamizole (Novasul 50%, Richter Pharma, Austria; 25 mg/kg 12h IV for 3 days), gabapentin (Grimodin 300 mg/tb, Egis Pharmaceuticals PLC, Hungary; 300 mg/ administration 24h PO for 10 days), pantoprazole (Controloc 40 mg/tb, Takeda GmbH, Germany; 1 mg/kg 24h PO for 14 days), and PPA (Propalin 5%, Vetquinol, France; 1.2 mg/kg 12h PO for 14 days). After 3 days of treatment, metamizole was changed with meloxicam (Meloxidolor 2%, Le Vet Pharma, Holland; 0.2 mg/kg 24h SC for 7 more days).

3. Results

3.1. Imagistic results

Computed Tomographic findings were consistent with a large, cavitated hypoattenuating splenic space-occupying mass with a heterogenic structure with multiple fluid attenuating areas (Figure 1a,d).

The liver also had multiple hypoattenuating areas with a cyst-like structure. The gall bladder was mildly distended with hypoattenuating content (Figure 1b,e). The urinary bladder was in semi plentitude and presented with normal contrast uptake due to urine filtration and displaced caudally into the pelvic region (Figure 1c,f).

The gastrointestinal tract, alongside both kidneys, presented no pathological alterations.

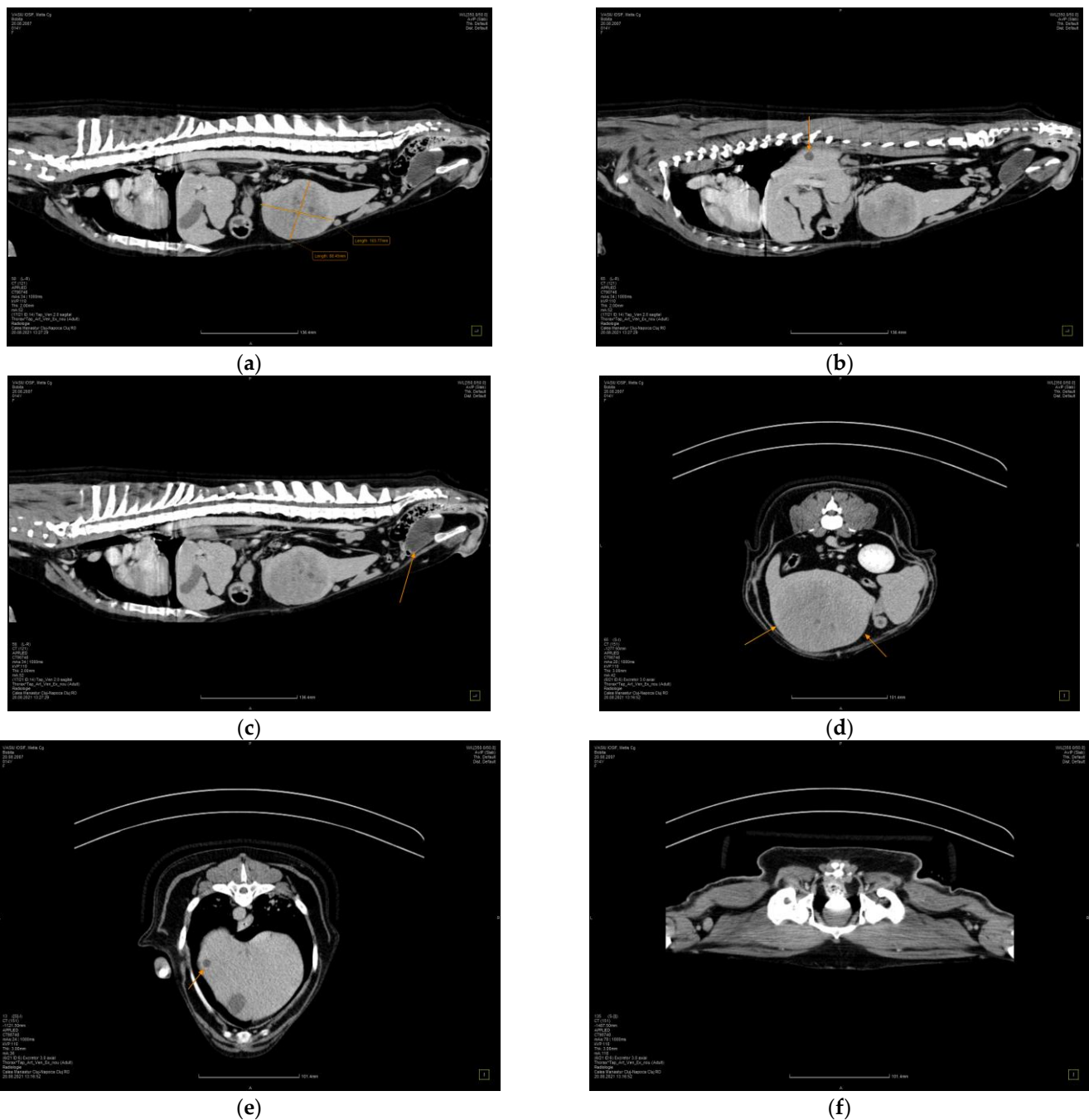


Figure 1. CT evaluation of the abdomen a, b, c: Sagittal view of the thorax and abdomen; d,e,f: axial view of the abdomen and pelvis. The reconstruction is made at different levels.

3.2. Laboratory results

Hematological assays showed the presence of hypochromic and microcytic anemia with anisocytosis and thrombocytosis. Folded levels of alkaline phosphatase (ALP), , and gamma-glutamyl transferase (GGT) confirmed the presence of cholecystitis. Cholesterol (CHOL) and lactate levels (LAC) were also folded (Supplementary Tables S1 and S2). The microbiological assays were negative; the urine sample was sterile, with no sediment or urinary cytology alterations, and the stool sample was negative.

After surgery, the anemia was accentuated, but the platelets (PLT) returned to the physiological levels, and except for ALP, alanine aminotransferase (ALT), and the globulins, all the other biochemical parameters returned within the physiological limits, including the LAC level (Supplementary Tables S1 and S2).

The histopathological evaluation confirmed the presence of splenic nodular hyperplasia (lymphoid), associated with extensive, acute splenic hematoma. The splenic mass was nodular, poorly demarcated, unencapsulated, elevating the capsule, and consisting of large blood-filled spaces (without an endothelial demarcation). The blood-filled spaces were separated by the preexistent splenic parenchyma and were focally admixed with discrete aggregates of lymphocytes organized in distinct follicular-like structures separated by a few stromal cells (occasionally demarcated by hyalinized collagen). The follicular-like structures showed typical germinal centers and consisted of a regular, stratified mixture of small and large lymphocytes with mantle and marginal zone morphologic features. Mitoses were not observed.

Within the liver, hepatic nodular hyperplasia was diagnosed. The nodular mass was well-demarcated unencapsulated, replacing the preexistent hepatic parenchyma focally and consisting of compact sheets and cords (uniform-cell hepatic plates, ≤ 4 hepatocytes thick) of hepatocytes separated by a delicate, fibrous stroma. Few foci of necrosis and extramedullary hematopoiesis (multilineage) were present. Portal spaces and mitotic figures were not observed.

3.3. Post-op results

At 12 h after surgery, the bitch was bright and alert and presented a good appetite. It received small amounts of commercially canned food. Water was provided *ad libitum*. The bitch was leashed and walked 4/5 times daily with no discomfort during the walk-overs.

After three days of treatment with PPA, the UI ceased, and the bitch was no longer wet on her hindlimbs. The sutures were removed 14 days after the surgical intervention, and the bitch was discharged from the hospital. The owner was instructed to continue the oral administration of PPA, following the same posological protocol, for life. The owner was also asked to give monthly feedback for the rest of the treatment, sooner if needed. A prescription for ursodeoxycholic acid (Ursofalk, Dr. Falk Pharma GmbH, Germany; 250 mg/tb, 10 mg/kg, 24h PO for 14 days) was released to treat the cholecystitis, and a hepatic diet was also recommended.

4. Discussion

In this case, we postulate that the presence of a splenic mass in a nulliparous sterilized 14-year-old German Shepherd bitch led to an increase in abdominal pressure, partially causing the urinary bladder to move from its abdominal topography into the pelvic cavity, facilitating the onset of USMI derived UI similar to the mechanism acknowledge in women where the increasing pressure of the enlarged uterus and fetal weight on the pelvic floor muscle (PFM) and the bladder throughout pregnancy [15], together with pregnancy-related hormonal changes, may lead to reduced PFM strength and their supportive and sphincteric function. In addition, these changes cause bladder, neck, and urethra mobility, leading to urethral sphincter incompetence [16–18].

In dogs, USMI is the most common cause of acquired UI (i.e., 3-5%). The frequency is influenced by gender, breed, body size, weight, docking, gonadectomy, urethral length, urethral tone, and bladder neck positioning, without any known breed predisposition [2,4,19].

Ovariectomy or OHE does not result in different continence rates; however, the risk of USMI developing increases with large breed dogs; although mixed young to middle-aged spayed females weighing more than 15 kg are typically affected, the risk decreasing every month the sterilization is postponed in the first year. However, spaying females before the onset of the first heat cycle is less likely to develop UI than those sterilized later in life. In contrast, dogs weighing less than 15 kg are less prone to develop this condition [3,5,20–22].

In adult females, USMI is the leading cause of UI [3], while in young bitches, the leading causes are various congenital abnormalities, especially ureteral ectopia [3,23]. In some breeds, including German Shepherds, USMI is encountered in juveniles and adult females [3]. In the present case, the bitch was a German Shepherd crossbreed and presented with UI about seven years after spaying intervention. To date, there is no clear correlation between the presence of USMI and the spaying age of the bitches; however, it is reported equally in both males and females [5,6,20,21].

Some reports suggest that about 89-90% of the spayed bitches may develop USMI [3,22]; moreover, UI can occur immediately after sterilization, with the majority of the females developing USMI in the first year after OHE; however, USMI can develop even after ten years after OHE. About 75% of bitches develop USMI within three years of gonadectomy [3,6,7,20,21,24].

Urinary incontinence may be permanent or intermittent [3,7]. The exact pathophysiology of USMI is mainly unknown; however, it is multifactorial [21]. The impact of OHE on urinary tract receptor expression is controversial. There is a decrease in urethral closure pressure within one year of OHE, even in continent individuals. If the urethral closure pressure drops below a certain threshold, the sphincter becomes incompetent, and UI develops [21,25].

Moreover, about 75% of the spayed bitches that acquired subsequent USMI had at least one oestrus, and 78% presented pelvic bladders [3,26]. Interestingly, one report showed that UI was present in a bitch when oestrus would have been expected, even though the bitch was spayed [3]. Moreover, compared with continent bitches, which usually show an intraabdominal bladder neck, incontinent bitches have a shorter and dilated urethra [3,22,26]. In the current case, a pelvic bladder was also identified on the CT.

In bitches with intrapelvic bladder neck, an increase in the intrabdominal pressure will be transmitted only to the bladder. Furthermore, the intravesical pressure will rise. If the urethral resistance is poor, urine leakage can occur, as in bitches with USMI, which tend to be more incontinent whenever the intra-abdominal pressure increases [26]. Generally, UI worsens in sleeping dogs or during increased abdominal pressure episodes while barking, coughing, jumping in the owner's car, or recumbency [3,21,24]. In the present case, the owner reported that the bitch was leaking urine, especially while sleeping or laying in the kennel.

Hormonal abnormalities, mainly estrogen deficiency, may also impact sphincter incompetence; however, since not all incontinent dogs improve with estrogen supplementation, it is unlikely that estrogens alone are solely responsible for the development of USMI [21]. Urethral sphincter mechanism incompetence may also predispose to urinary tract infections [1]; however, treatment and presence of concurrent urinary pathologies, including urinary tract infections, do not influence the degree of incontinence [3,22].

There are no specific physical findings to USMI, but clinicians should pay attention to the bladder size, tone, and location. The CBC and TS are usually unaltered; however, they should be performed to rule out other concurrent pathologies. In animals with inappropriate urination, urinalysis and uroculture via cystocentesis for occult infections

like cystitis or endocrinology problems like diabetes, liver failure, or other metabolic disorders, especially when dogs present PU and polydipsia (PD), are recommended. The differential diagnostic should also assess the behavior causes of inappropriate urination. Imagistics are usually normal in dogs with USMI; however, abdominal imagistic is very important to rule out neoplastic or urinary tract calculi. If all the investigations are negative, a trial of medical therapy is acceptable for diagnostic and therapeutic. Cystometrograms and urethral pressure profiles measuring pressure along the length of the urethra are required to document decreased urethral tone [1,6,21,24,26].

Imagistics revealed the presence of cholecystitis, a splenic mass, and a pelvic bladder in the present case. The elevated PAL and GGT levels are consistent with cholecystitis. Besides the anemia and thrombocytosis, biochemistry, hematology, and urinalysis showed no other signs of occulted infections before the splenectomy. Moreover, after the surgery, the folded hepatic enzymes were caused by the hepatic biopsy.

The long-term well-being of owners and pets is affected by USMI as its etiology is multifactorial and complicated. Therefore, treatment comprises a conservative approach followed by surgical management if needed. However, irrespective of the treatment protocol, life-long management of USMI is required [21].

Sympathomimetic alpha-adrenergic agents (i.e., PPA, Ephedrine, or pseudoephedrine) and hormonal-based drugs (i.e., estrogens, testosterone, or gonadotropin-releasing hormone; GnRH) are used to treat USMI. The first category of medical substances directly stimulates the smooth muscles of the internal urethral sphincter and bladder neck, leading to an increased sphincter tone and a subsequent alleviation of UI. As urethral sphincter tone increases, UI and vulvar scalding decrease over time [1,2,4,21,25].

Usually, before surgery, most females are conservatively treated, mainly with PPA [22]. This choice is the frontline treatment of USMI and is intended for the life-long management of USMI-derived UI. Therapeutic dosages are effective between 1.5-2 mg/kg SID or BID, reaching long-term continence in bitches suffering from USMI; however, the treatment with PPA is also effective at a 1 mg/kg TID dose [1].

The clinical effect is observed in the first month of treatment. Furthermore, PPA effectively maintains continence between 90-97% of the treated bitches [1,2,21,24]. In the present case, the condition was alleviated after the first three days of PPA administration. Concurrently, the splenectomy might have also played an essential part in the liquidation of the USMI since the extra pressure exercised by the splenic mass on the urinary bladder was suppressed.

The main side effects of PPA are diarrhea and vomiting; however, cardiovascular, neurologic, and behavioral changes like anxiety, excitement, and aggressiveness may also be present secondary to an increased sympathetic tone [1,4,21]. In the present case, no such side effects were reported; however, one month after the beginning of the PPA treatment, the owner reported that the bitch presented a healthy appetite, a shiny coat, and a substantial improvement in mentation and alertness. These positive effects could be partially explained by the increased sympathetic tone and the liquidation of the anemia.

Ephedrine or pseudoephedrine can also be of aid. However, these medical substances have an efficacy of only 25-75% and may show adverse effects such as panting, hypoxemia, and lethargy [1,21].

Oestrogens (i.e., Estriol) alone or combined with alpha-adrenergic drugs may be necessary to reach continence in some affected females. However, estrogens are not side-effect-free since vulvar hyperplasia, vaginal discharge, and even pyometra are reported [1,21,25]. A combination of GnRH analogs and PPA are also used; however, the treatment is effective for no more than six months [1].

In male dogs, testosterone may be considered if they do not respond favorably to the PPA treatment; however, side effects are also reported in this category of drugs [1,21,25]. Moreover, the use of methyltestosterone (0.32-1.27 mg/kg PO SID twice a week or *ead*) in spayed bitches, may be more effective than in castrated male dogs, with excel-

lent responses between 2 to 4 weeks; however, it seems that the taper off the testosterone dose has a negative impact on incontinence [27].

The main reasons owners decide to start surgical treatment are represented by poor response to medication (i.e., 17%), progressive unresponsiveness to PPA administration (i.e., 48%), presence of side effects associated with PPA therapy, and owner preference for surgical treatment rather than medical approach (i.e., 29%) [22].

In refractory patients, the following treatment options are mainly surgical and include minimally invasive urethral occluders, urethral bulking, urethropexy, cystourethropexy, and colposuspension, or surgically inserting a hydraulic artificial urethral sphincter (HAUS) [2,7,21,28].

The HAUS placement represents a relatively novel approach. It is implemented in animals where medical management or other surgical approaches are ineffective. To date, the HAUS system is believed to provide the best long-term results for the surgical treatment of bitches with refractory UI, with most dogs achieving complete continence with few reported complications and no other medical treatments needed [5,6,28]. Nevertheless, the overall prognosis for USMI is typically good with long-term therapy [21].

The nonmalignant splenic masses are usually identified in 7-14 years dogs; however, nonmalignant and malignant splenic masses can coexist in the same individual [10]. In affected dogs, 17-50% of splenic masses are hematomas and account for the majority (i.e., 46%) of the benign splenic masses [9,29-31]. In comparison, splenic and hepatic nodular hyperplasia is accounted for with a prevalence of about 44% and 38%, respectively [9].

Usually, in dogs, splenic hematomas are secondary to underlying splenic disorders, such as NLH, and are less commonly a consequence of trauma [10,12,13]. For example, in a case series, a fall on the stairs is the only trauma-related splenic hematoma event reported in dogs; however, whether a splenic mass existed prior to the traumatic event or not is unknown [14]. In the current case, the hematoma was identified in a 14-year-old spayed bitch, and the owner reported no trauma.

Grossly splenic hemangiosarcomas and hematomas are indistinguishable during clinical examination, during surgery [10,14,32], and to some extent, even imagistic evaluation poses limitations [10,12,13]; moreover, it is possible that what initially is thought to be a splenic hematoma may be cancer. Thus histologic diagnosis is mandatory since the risk of misdiagnosis is high (i.e., 11%) [14]. The histological evaluation of the specimens sent to the Pathology Department confirmed the presence of NLH.

The most affected dogs are the German shepherds (i.e., 11.3%) and Labrador retrievers (i.e., 6%), with splenic NLH, with or without hematomas, as the most diagnosed benign splenic mass (i.e., 86%); moreover, 46% of the animals being spayed bitches, with a mean age at the time of splenic removal of ten years [14,33].

Interestingly, about 7.6% of dogs with splenic masses die in the perioperative window. However, only 1% of these dogs die during hospitalization [31]. The leading underlying causes of death are uncontrolled hemorrhage (i.e., 24.4%), Portal system thrombosis (PST; i.e., 22%), Pulmonary thromboembolism (PTE; i.e., 9.8%), pneumonia (i.e., 9.8%, each) or, Disseminated intravascular coagulation (DIC; i.e., 7.3%) [31].

Gender, splenic mass volume, elevated ALP levels, hemorrhagic peritoneal effusion, anemia, body weight, transfusion coagulopathy, palpable masse, and metastasis are the main parameters evaluated for the survival of dogs diagnosed with splenic hematomas [14]. In addition, marked preoperative thrombocytopenia, anemia, and the development of intraoperative ventricular arrhythmias are risk factors for perioperative death in dogs with splenic masses [31]. However, besides the presence of a distended and sensitive abdomen, increased ALP levels, and anemia, no other risk factors had been identified in the perioperative window in the current case.

Prompt surgical interventions increase life expectancy after splenectomy in dogs with benign splenic masses [29,30]. In cases with splenic hematomas, the overall median survival is 647 days after surgery, up to 3287 days (i.e., 2-9 years) [14]. To date, at 219 days after splenectomy, the owner reports positive feedback. In addition, the health status of the bitch had much improved, with no reported side effects whatsoever.

To the author's knowledge, this is the first case report where a pelvic bladder, and consecutive USMI, are associated with a splenic hematoma in a nulliparous sterilized mixed German Shepherd bitch. Therefore, splenic masses should be considered predisposing factors for UI development, consecutive to USMI, especially in old, spayed bitches.

Supplementary Materials: Figure S1: The gross aspect of the splenic hematoma in a 14-years old spayed mixed German Shepherd bitch, after splenectomy, Table S1: Pre-operative and post-operative biochemical and hematological values, Table S2: Pre-operative and post-operative blood gases values (i.e., venous blood).

Author Contributions: Conceptualization, data curation, writing, review, and editing IV; Patient monitoring, anesthesia, surgery, CAO, ANA, VNO, and IM; Imagistics RP, AR; Post-op treatment AR, MV, EMM, and IV; Histopathologic examination and interpretation FT. All authors have read and agreed to the published version of the manuscript.

Funding: The publication was supported by funds from the National Research Development Projects to finance excellence (PFE)-14 (ID 546) granted by the Romanian Ministry of Research, Innovation, and Digitalization.

Institutional Review Board Statement: This research was conducted according to the national (Legea 43 din 2014) and European (Directiva EU 63/2010) legislation regulations regarding animal protection and welfare for scientific purposes. The owner was informed that the outcomes of this case report would be published and gave its verbal consent for publication. Accordingly, ethical review and approval were waived for this study, as standard procedures were implied.

Acknowledgments: We would like to acknowledge the entire Academic Veterinary Hospital staff for their unconditional involvement in the treatment and well-being of all patients treated in our Faculty of Veterinary Medicine.

Conflicts of Interest: The authors declare no conflict of interest.

References

1. Scott, L.; Leddy, M.; Bernay, F.; Davot, J.. Evaluation of phenylpropanolamine in the treatment of urethral sphincter mechanism incompetence in the bitch. *J. Small Anim. Pract.* **2002**, *43*, 493–496.
2. Timmermans, J.; Van Goethem, B.; De Rooster, H.; Paepe, D. Medical treatment of urinary incontinence in the bitch. *Vlaams Diergeneesk. Tijdschr.* **2019**, *88*, 3–8, doi:10.21825/vdt.v88i1.11399.
3. Holt, P.E. Urinary incontinence in the bitch due to sphincter mechanism incompetence: prevalence in referred dogs and retrospective analysis of sixty cases. *J. Small Anim. Pract.* **1985**, *26*, 181–190, doi:10.1111/j.1748-5827.1985.tb02099.x.
4. Noël, S.; Claeys, S.; Hamaide, A. Acquired urinary incontinence in the bitch: Update and perspectives from human medicine. Part 2: The urethral component, pathophysiology and medical treatment. *Vet. J.* **2010**, *186*, 18–24, doi:10.1016/j.tvjl.2010.06.011.
5. Morgan, K.R.S.; Milner, H.R.; Tikekar, A.; Smith, H.L.; Coomer, A.R. Long term use of hydraulic artificial urethral sphincters in nine dogs from New Zealand with urethral sphincter mechanism incompetence. *N. Z. Vet. J.* **2018**, *66*, 205–209, doi:10.1080/00480169.2018.1464975.
6. Gomes, C.; Doran, I.; Friend, E.; Tivers, M.; Chanoit, G. Long-Term Outcome of Female Dogs Treated with Static Hydraulic Urethral Sphincter for Urethral Sphincter Mechanism Incompetence. *J. Am. Anim. Hosp. Assoc.* **2018**, *54*, 276–284, doi:10.5326/JAAHA-MS-6709.
7. Holt, P.E. Urinary incontinence in the bitch due to sphincter mechanism incompetence: surgical treatment. *J. Small Anim. Pract.* **1985**, *26*, 237–246, doi:10.1111/j.1748-5827.1985.tb02108.x.
8. Mangano, C.; Macrì, F.; Di Pietro, S.; Pugliese, M.; Santoro, S.; Iannelli, N.M.; Mazzullo, G.; Crupi, R.; De Majo, M. Use of contrast-enhanced ultrasound for assessment of nodular lymphoid hyperplasia (NLH) in canine spleen. *BMC Vet. Res.* **2019**, *15*, 1–9, doi:10.1186/s12917-019-1942-5.
9. Leyva, F.J.; Loughin, C.A.; Dewey, C.W.; Marino, D.J.; Akerman, M.; Lesser, M.L. Histopathologic characteristics of

- biopsies from dogs undergoing surgery with concurrent gross splenic and hepatic masses: 125 cases (2012-2016). *BMC Res. Notes* **2018**, *11*, 14–18, doi:10.1186/s13104-018-3220-1.
10. Fife, W.D.; Samii, V.F.; Drost, T.; Mattoon, J.S.; Hoshaw-Woodard, S. Comparison between malignant and nonmalignant splenic masses in dogs using contrast-enhanced computed tomography. *Vet. Radiol. Ultrasound* **2004**, *45*, 289–297, doi:10.1111/j.1740-8261.2004.04054.x.
 11. Mallinckrodt, M.J.; Gottfried, S.D. Mass-to-splenic volume ratio and splenic weight as a percentage of body weight in dogs with malignant and benign splenic masses: 65 cases (2007–2008). *J. Am. Vet. Med. Assoc.* **2011**, *239*, 1325–1327, doi:10.2460/javma.239.10.1325.
 12. Ivančić, M.; Long, F.; Seiler, G.S. Contrast harmonic ultrasonography of splenic masses and associated liver nodules in dogs. *J. Am. Vet. Med. Assoc.* **2009**, *234*, 88–94.
 13. Kutara, K.; Seki, M.; Ishigaki, K.; Teshima, K.; Ishikawa, C.; Kagawa, Y.; Edamura, K.; Nakayama, T.; Asano, K. Triple-phase helical computed tomography in dogs with solid splenic masses. *J. Vet. Med. Sci.* **2017**, *79*, 1870–1877, doi:10.1292/jvms.17-0253.
 14. Patten, S.G.; Boston, S.E.; Monteith, G.J. Outcome and prognostic factors for dogs with a histological diagnosis of splenic hematoma following splenectomy: 35 cases (2001-2013). *Can. Vet. J.* **2016**, *57*, 842–846.
 15. Sangsawang, B. Risk factors for the development of stress urinary incontinence during pregnancy in primigravidae: A review of the literature. *Eur. J. Obstet. Gynecol. Reprod. Biol.* **2014**, *178*, 27–34, doi:10.1016/j.ejogrb.2014.04.010.
 16. Sangsawang, B.; Sangsawang, N. Stress urinary incontinence in pregnant women: A review of prevalence, pathophysiology, and treatment. *Int. Urogynecol. J.* **2013**, *24*, 901–912, doi:10.1007/s00192-013-2061-7.
 17. Frederice, C.P.; Amaral, E.; De Oliveira Ferreira, N. Urinary symptoms and pelvic floor muscle function during the third trimester of pregnancy in nulliparous women. *J. Obstet. Gynaecol. Res.* **2013**, *39*, 188–194, doi:10.1111/j.1447-0756.2012.01962.x.
 18. Chaliha, C.; Bland, J.M.; Monga, A.; Stanton, S.L.; Sultan, A.H. Pregnancy and delivery: A urodynamic viewpoint. *Br. J. Obstet. Gynaecol.* **2000**, *107*, 1354–1359, doi:10.1111/j.1471-0528.2000.tb11647.x.
 19. Gregory, S.P. Developments in the understanding of the pathophysiology of urethral sphincter mechanism incompetence in the bitch. *Br. Vet. J.* **1994**, *150*, 135–150, doi:10.1016/S0007-1935(05)80222-2.
 20. Byron, J.K.; Taylor, K.H.; Phillips, G.S.; Stahl, M.S. Urethral Sphincter Mechanism Incompetence in 163 Neutered Female Dogs: Diagnosis, Treatment, and Relationship of Weight and Age at Neuter to Development of Disease. *J. Vet. Intern. Med.* **2017**, doi:10.1111/jvim.14678.
 21. Applegate, R.; Olin, S.; Sabatino, B. Urethral sphincter mechanism incompetence in dogs: An update. *J. Am. Anim. Hosp. Assoc.* **2018**, *54*, 22–29, doi:10.5326/JAAHA-MS-6524.
 22. White, R.N. Urethropexy for the management of urethral sphincter mechanism incompetence in the bitch. *J. Small Anim. Pract.* **2001**, *42*, 481–486, doi:10.1111/j.1748-5827.2001.tb02452.x.
 23. Callard, J.; Mcloughlin, M.A.; Byron, J.K.; Chew, D.J. Urinary Incontinence in Juvenile Female Soft-Coated Wheaten Terriers: Hospital Prevalence and Anatomic Urogenital Anomalies. *J. Am. Anim. Hosp. Assoc.* **2016**, *52*, 27–35, doi:10.5326/JAAHA-MS-6220.
 24. Claeys, S.; Rustichelli, F.; Noël, S.; Hamaide, A. Clinical evaluation of a single daily dose of phenylpropanolamine in the treatment of urethral sphincter mechanism incompetence in the bitch. *Can. Vet. J.* **2011**, *52*, 501–505.
 25. Reichler, I.M.; Hubler, M. Urinary incontinence in the bitch: An update. *Reprod. Domest. Anim.* **2014**, *49*, 75–80, doi:10.1111/rda.12298.
 26. Holt, P.E. Importance of urethral length, bladder neck position and vestibulovaginal stenosis in sphincter mechanism incompetence in the incontinent bitch. *Res. Vet. Sci.* **1985**, *39*, 364–372.
 27. Nishi, R.; Motegi, T.; Maeda, S.; Tamahara, S.; Momoi, Y.; Matsuki, N.; Yonezawa, T. Clinical assessment of testosterone

- analogues for urethral sphincter mechanism incompetence in ten spayed female dogs. *J. Vet. Med. Sci.* **2021**, *83*, 274–279, doi:10.1292/jvms.20-0515.
28. Timmermans, J.; Van Goethem, B.; de Rooster, H. Surgical treatment of refractory incontinence in the bitch. *Vlaams Diergeneesk. Tijdschr.* **2020**, *89*, 177–183, doi:10.21825/vdt.v89i3.16540.
29. Burgess, K.E.; Price, L.L.; King, R.; Kwong, M.; Grant, E.; Olson, K.A.; Lyons, J.A.; Robinson, N.A.; Wendelburg, K.M.; Berg, J. Development and validation of a multivariable model and online decision-support calculator to aid in preoperative discrimination of benign from malignant splenic masses in dogs. *J. Am. Vet. Med. Assoc.* **2021**, *258*, 1362–1371, doi:10.2460/javma.258.12.1362.
30. Cleveland, M.J.; Casale, S. Incidence of malignancy and outcome incidentally detected nonruptured splenic nodules 105 cases (2009-2013). *J. Am. Vet. Med. Assoc.* **2016**, *248*, 1267–1273.
31. Wendelburg, K.M.; O'toole, T.E.; McCobb, E.; Price, L.L.; Lyons, J.A.; Berg, J. Risk factors for perioperative death in dogs undergoing splenectomy for splenic masses: 539 cases (2001–2012). *J. Am. Vet. Med. Assoc.* **2014**, *245*, 1382–1390, doi:10.2460/javma.245.12.1382.
32. Hammond, T.N.; Pesillo-Crosby, S.A. Prevalence of hemangiosarcoma in anemic dogs with a splenic mass and hemoperitoneum requiring a transfusion: 71 cases (2003-2005). *J. Am. Vet. Med. Assoc.* **2008**, *232*, 553–558, doi:10.2460/javma.232.4.553.
33. O'Byrne, K.; Hosgood, G. Splenic mass diagnosis in dogs undergoing splenectomy according to breed size: 234 dogs (2008-2017). *Vet. Rec.* **2019**, *184*, 1–5, doi:10.1136/vr.104983.