

The glaucomas in dogs

Andreea Alina Zăvoi ^{1*}, Andra Elena Enache ²

¹ University of Agricultural Sciences and Veterinary Medicine Cluj Napoca, Faculty of Veterinary Medicine; andreea-alina.zavoi@usamvcluj.ro

² North Downs Specialist Referrals, Bletchingley, UK; Andra.Enache@ndsr.co.uk

* Correspondence: andreea-alina.zavoi@usamvcluj.ro

Abstract: The glaucomas (the plural term is used intentionally) represent a group of diseases commonly defined by an increased intraocular pressure which interferes with normal function of the optic nerve and retina. Characteristic changes of glaucomas include reduced axoplasmic flow in the optic nerve head, retinal ganglion cells death, cupping of the optic disc and visual damage or blindness due to retinal and optic nerve atrophy. This communication describes the clinical signs, diagnosis and medical treatment of glaucomas in dogs.

Keywords: glaucoma, blindness, ocular hypertension, gonioscopy, dogs

1. Introduction

According to the European College of Veterinary Ophthalmologists (www.ecvo.org) Manual 'Glaucoma is characterized by an elevation of intraocular pressure (IOP) which, when sustained, results in destruction of the intraocular structures and function, resulting in blindness. The elevated IOP occurs mainly with developmental abnormalities or disease processes affecting the intraocular circulation and especially the drainage of aqueous humour from the eye through the irido-corneal angle (ICA). DNA-tests for Open Angle Glaucoma (POAG) in specific breeds are available.'

Glaucoma typically occurs as a result of impaired aqueous humor drainage whereby the obstruction of the drainage pathway may lie at the level of either the pupil (pupil block glaucoma), the ICA (trabecular meshwork, the conventional pathway), the uveo-scleral outflow (unconventional pathway), the lens, the ciliary body or the vitreous [1, 2].

The main function of the aqueous humor is to provide nutrients to the cornea and lens. The aqueous humor is constantly produced at the level of the non-pigmented epithelium of the ciliary processes (Fig. 1). It flows through the posterior chamber, the pupil and into the anterior chamber (in a dorsal to ventral direction due to thermal convection currents) to be drained into the ICA (the filtration angle, the anterior most portion of the ciliary body, Fig 2.). The ICA is formed by the junction of the inner cornea (the corneoscleral tunic), base of the iris and ciliocleral cleft (which contains the pectinate ligaments). The aqueous humor is then drained through the trabecular meshwork and associated aqueous collecting channels (the conventional and main pathway) and less through the ciliary body and anterior uvea (the uveoscleral pathway, also called the unconventional/alternative pathway).

Received: 14.12.2021

Accepted: 30.12.2021

Published: 31.12.2021

DOI: 10.52331/cvj.v26i3.34



Copyright: © 2021 by the authors. Submitted for possible open access publication under the terms and conditions of the Creative Commons Attribution (CC BY) license (<http://creativecommons.org/licenses/by/4.0/>).

The entire anterior chamber volume (0.4 ml in the dog) is replaced within an hour in most species (46-80 minutes in the dog) [1,2]. Therefore, the IOP is the result of the balance between production and outflow of aqueous humor. The production of aqueous humor is a dynamic process, the inflow of aqueous humor equals the outflow [1,2].

In glaucoma, both the aqueous humor production and outflow are altered. In understanding the pathogenesis of glaucoma it is important to understand the anatomy and physiology of the aqueous humor outflow pathways in normal and glaucomatous eyes.

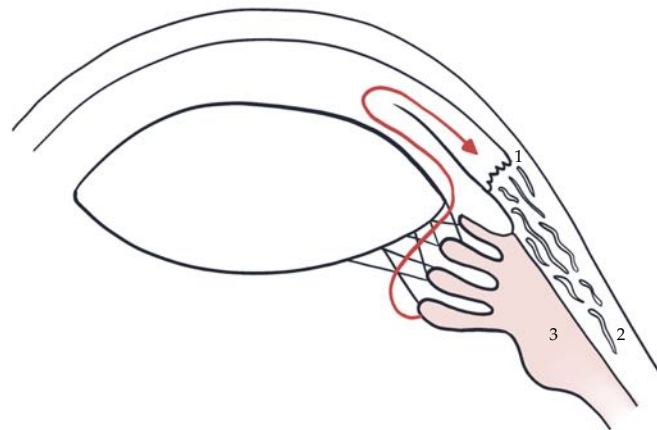


Figure 1. Aqueous humor drainage routes in canine eye. After being produced at the level of the ciliary processes, the aqueous humor flows through the posterior chamber into the anterior chamber (dorso-ventral direction, via convection currents). Here, it is drained via the trabecular meshwork of the ciliary cleft and into the angular aqueous plexus then directed anteriorly into the episcleral venules (1) or posteriorly into the scleral venous plexus and the vortex venous system (2). An alternative aqueous humor drainage pathway (3) is the diffusion through the ciliary muscle interstitium to the suprachoroidal space and through the sclera (ie, uveoscleral outflow).

Source: Original AZ adapted after [3]

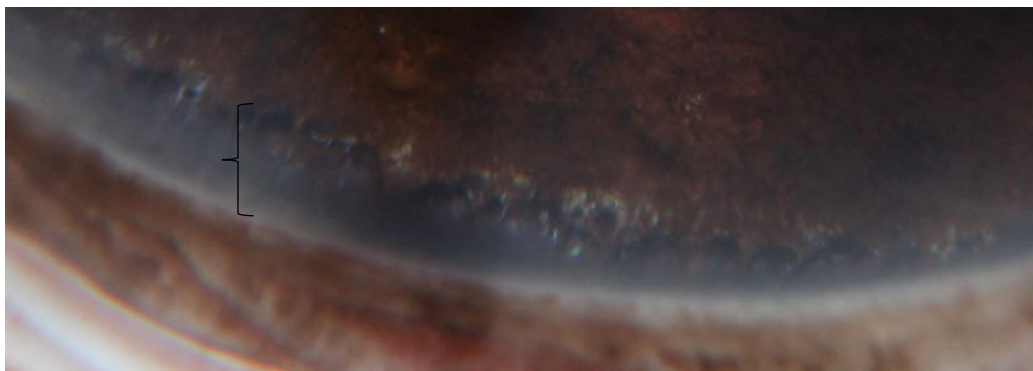


Figure 2. The pectinate ligament visualized by gonioscopy (accolade '{') (AE Enache)

2. Causes and clinical signs of glaucoma

Glaucomas have been classified according to their cause into congenital, primary or breed-related (open angle and closed angle glaucoma) and secondary to other intra-ocular diseases (eg. chronic uveitis, primary lens

luxation and intraocular neoplasia, Table 1). The canine glaucomas can also be classified according to the stage of progression into acute or chronic.

Table 1. Causes of glaucoma adapted after [3]

Congenital glaucoma	Goniodysgenesis associated with multiple ocular defects
Primary glaucoma	Goniodysgenesis/narrow/closed irido-corneal angle: Breeds affected www.ecvo.org : <ul style="list-style-type: none"> • Japanese Shiba Inu • Dandie Dinmont terrier • Leonberger • Retriever (Flat Coated) • Siberian Husky • Spaniel (American Cocker) • Spaniel (Cocker) • Spaniel (English Springer) • Spaniel (Welsh Springer) • Spanish Water Dog and others
	Primary open angle glaucoma - Beagle, Norwegian Elkhound, Petit Basset Griffon Vendéen, Basset Hound, Shar Pei
Secondary glaucoma	Formation of pre-iridal fibrovascular membranes (PIFM) over the ciliary cleft opening - secondary to retinal detachment, neoplasia or uveitis
	Intraocular haemorrhage (due to systemic hypertension, coagulopathies, thrombocytopenia)
	Intumescence of a cataractous lens (phacomorphic glaucoma in diabetic cataracts)
	Golden Retrievers pigmentary uveitis
	Intraocular neoplasia
	Postoperative following cataract surgery
	Ocular melanosis and pigmentary glaucoma in Cairn Terriers
	Primary lens luxation - terrier breeds, Border collie and other breeds
	Uveitis, including lens - induced uveitis (phacolytic, phacoclastic uveitis)
Vitreous prolapse after surgical lens extraction (obstruction of the drainage angle by the vitreous)	

Clinical signs of glaucoma vary with the duration, intensity and cause of the IOP elevation from simple ocular surface redness (conjunctival hyperaemia and episcleral congestion that can be misdiagnosed as

conjunctivitis or retrobulbar disease), third eyelid protrusion and ocular discharge (commonly mistaken for conjunctivitis) to diffuse corneal oedema (cloudiness) that comes and goes (due to intermittent pressure spikes) and enlarged globe. Visual impairment may not be obvious to the owner as the dog will likely rely on vision from the contralateral eye, however the owner may report that the dog had been bumping into things on a particular side, missing things or being startled when approached from a particular side.

As the dog is presented with a red eye, other ocular diseases should be included on the differential list such as uveitis (Fig. 3), episcleritis, conjunctivitis, retrobulbar disease. It is not uncommon to misdiagnose glaucoma as conjunctivitis which leads to irreversible blindness due to the delay in the appropriate treatment. Distinguishing between various diseases that can cause ocular redness should be based on the result of the clinical examination (the presence of menace response, pupillary light and dazzle reflexes) and tonometry (when available).

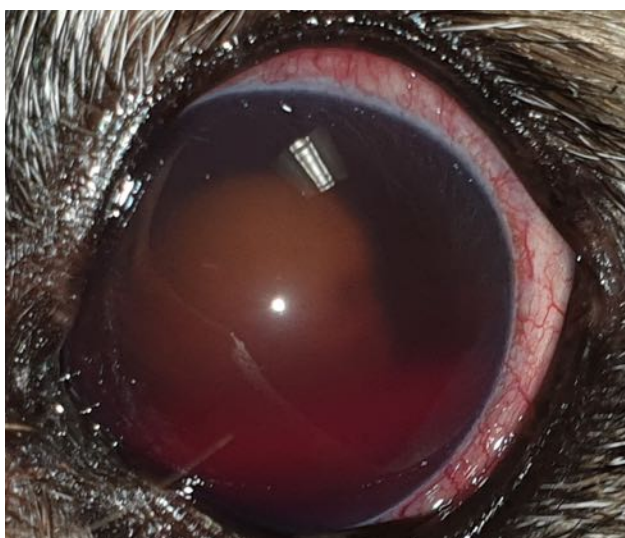


Figure 3. Uveitis, Border terrier, 7yo, MN- note the diffuse conjunctival hyperaemia, mid-dilated pupil, hyphaema, hypermature cataract (North Downs Specialist Referrals)

Primary sudden onset congestive glaucoma is easier to recognize as the dog will be typically middle age, female and will have absent menace response, fixed dilated pupil +/- absent dazzle reflexes, diffuse corneal oedema, episcleral congestion and conjunctival hyperaemia (Fig. 4). Cases of secondary glaucoma are more difficult to recognize solely based on the clinical signs but one should carefully look for signs of uveitis, retinal detachment or intraocular neoplasia, mid-dilated pupil with absent PLR and reduced or absent menace response.




Figure 4. English Cocker Spaniel, 8yo FN- Primary closed angle acute congestive glaucoma left eye, note the anisocoria with dilated left pupil, diffuse corneal oedema, third eyelid protrusion (North Downs Specialist Referrals)

Clinical signs of acute onset glaucoma (more common in primary glaucoma cases)

- Severe ocular and head pain;
- Lethargy, reduced appetite;
- Diffuse corneal oedema (Fig. 5);
- Blepharospasm;
- Epiphora;
- Marked conjunctival hyperaemia which can be misdiagnosed as conjunctivitis;
- Third eyelid protrusion;
- Marked episcleral vascular congestion;
- Mid to large dilated and unresponsive pupil;
- Deep perilimbal corneal vascularisation;
- Mild aqueous flare or pigment dispersion in the anterior chamber
- Changes in the appearance of the optic nerve appearance: pale or dark optic nerve head (atrophy), attenuation of the retinal vasculature, cupped optic nerve head (retinal vessels stop at the rim of the optic nerve, no vessels are seen crossing the optic nerve), hyperreflectivity of the tapetal fundus.

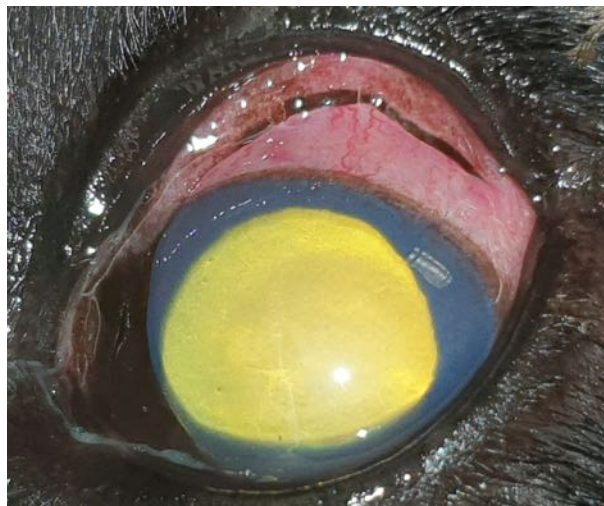

Figure 5. 8y6mo Cocker spaniel, FN with primary angle closed glaucoma – note the mucoïd discharge at the medial canthus, third eyelid protrusion, moderate conjunctival hyperaemia, episcleral congestion, diffuse corneal oedema and dilated pupil (North Downs Specialist Referrals)

Clinical signs of chronic glaucoma (more common in secondary glaucoma):

- Development of Haab' striae (Fig. 6): these are breaks in the Descemet membranes (allowing aqueous humor to enter the posterior stroma) secondary to stretching of the eye globe.
- Buphthalmos: physical enlargement of the globe, resulting from severe and chronic elevations in IOP. It may be especially pronounced in young animals and Shar Pei dogs (with POAG), who have a more easily distended cornea and sclera than most adult dogs; buphthalmic eyes are almost always blind [1,2].
- Scleral thinning and visualization of the underlying choroid owing to globe enlargement.

- Phthisis bulbi: this develops with advanced cases of glaucoma when the ciliary body stops producing aqueous humor.

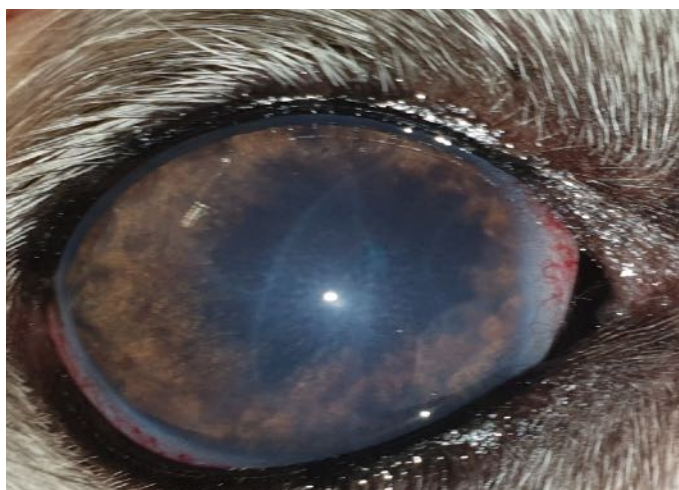


Figure 6. 6yo FN Whippet- Anterior uveitis and secondary chronic glaucoma- note the Haab's striae (curvilinear grey/white lines across the cornea), the pupil was miotic owing to the recent application of latanoprost (North Downs Specialist Referrals)

Congenital glaucoma

Congenital glaucoma is a rare condition which develops owing to the presence of severe ocular malformation and extensive goniodysgenesis associated with multiple ocular defects. Affected animals display severe, bilateral, ocular pathology, very early in life (generally within weeks to months) [1].

Primary glaucoma

Primary glaucoma is a bilateral disease which is not associated with any pre-existing intraocular disease, but has been associated with dysgenesis of the mesenchymal structures of the ICA (pectinate ligament dysplasia/goniodysgenesis) and/or narrowing or closure of the iridocorneal angle and/or the ciliary cleft (CC) in some breeds [1].

Clinical signs usually do not become evident until relatively late in life and this could be the consequence of age-related changes in the ICA. Primary glaucoma is a bilateral disease, however the onset of disease varies between the eyes [4].

Based on the appearance of the drainage angle at gonioscopy, primary glaucoma may be classified as open-angle glaucoma (Beagle, Petit Basset Griffon Vendéen, Basset Hound, Shar Pei, Norwegian Elkhound) and closed angle glaucoma more common in the majority of breeds (Cocker spaniel, Welsh springer spaniel etc). When the ICA appears abnormal on gonioscopy then goniodysgenesis has been diagnosed. A defect in the development of the ICA leads to a decreased width or malformation of the pectinate ligament. It is advised against breeding of dogs diagnosed with PCAG.

Typical presentation of a dog with PCAG is a sudden onset of unilateral acute congestive glaucoma (sudden blindness, dilated pupil, third eyelid protrusion, diffuse corneal oedema, marked episcleral congestion) in a middle aged dog (6-8 years of age) more common in female dogs belonging to one of the following breeds: American/English Cocker spaniel, Springer spaniel, Beagle, Boston Terrier, Norwegian elkhound (full list of affected breeds available at <https://www.bva.co.uk/canine-health-schemes/eye-scheme/> or

<https://www.ecvo.org/hereditary-eye-diseases/ecvo-manual.html> to check if a specific breed can be affected by primary glaucoma). The second eye typically follows the same outcome within 6-12 months after diagnosis.

Bilateral presentation of PCAG is rare and other intraocular conditions should be considered particularly uveitis/panuveitis, uveo-dermatologic syndrome, chorioretinitis and retinal detachment when a dog is presented with bilateral high IOPs.

Secondary glaucoma (post-inflammatory)

Describes elevated IOP that occurs secondary to underlying ocular disease. Common causes of secondary glaucoma include cataract (Fig. 7), post-cataract surgery, lens (sub)luxation, intraocular neoplasia, severe or chronic uveitis, retinal detachment, lens-induced uveitis, uveo-dermatologic syndrome.

Secondary glaucoma can develop acutely, subacutely, or chronically and may affect one or both eyes. Clinical signs include ocular discomfort, blepharospasm, corneal oedema, episcleral congestion (Fig 8), third eyelid protrusion, miosis or mydriasis, uveitis, buphthalmos and/or blindness [1-3]. Cases of glaucoma may be mistaken for conjunctivitis or retrobulbar disease due to the conjunctival hyperaemia, third eyelid protrusion and ocular discharge.



Figure 7. 13yo FN Miniature Schnauzer- chronic lens-induced uveitis and secondary pupil block glaucoma, under treatment- pigment dispersion on the surface of the iris and anterior lens capsule, posterior synechiae, fixed pupil (North Downs Specialist Referrals)

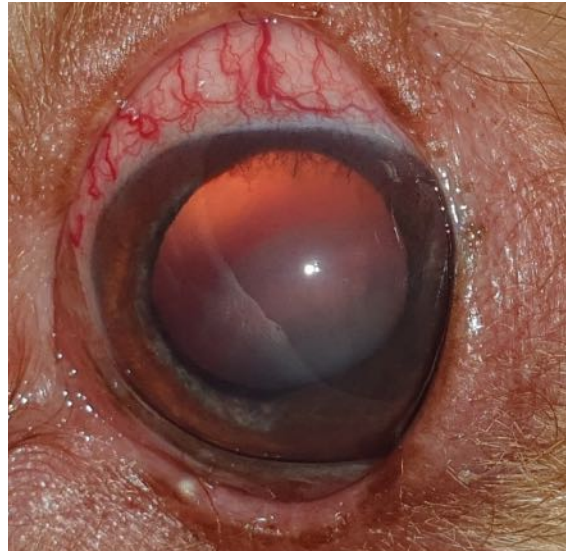

Figure 8. 8yo FN Miniature Poodle - posterior lens luxation and secondary glaucoma. Note the conjunctival hyperaemia, engorged episcleral vessels and the aphakic crescent dorsally indicating a posteriorly luxated lens. (North Downs Specialist Referrals)

Pigmentary glaucoma

Pigmentary glaucoma (ocular melanosis) is a form of glaucoma which occurs as a result of the proliferation and accumulation of cells containing melanin in the aqueous outflow [1]. Studies support a hereditary aetiology. Ocular signs are generally bilateral, although not always symmetrical. Commonly affected breeds include the Cairn Terrier, Boxer and Labrador Retriever.

3. Diagnosis of glaucoma in the dog

Vision loss can happen gradually over a few weeks or months or acutely in dogs with glaucoma. Ophthalmic examination, including funduscopy, should be performed to rule out other ocular causes such as retinal disease or uveitis. The history, clinical presentation and full ophthalmic examination findings support the diagnosis of glaucoma. IOP values greater than 25 mmHg are consistent with ocular hypertension and should raise the suspicion of glaucoma.

For the evaluation of visual function, the most important part is the assessment of the PLRs (pupillary light reflexes). It is important to evaluate the size of both pupils, and note any difference in pupil size (anisocoria). With raised intraocular pressure the PLR function is affected, the pupil will be fixed and dilated.

Evaluating the menace response (Fig. 9) is another important step of the ophthalmic examination. This response is elicited by a threatening hand gesture heading towards the eye. A blinking response and globe retraction are expected to occur. This response involves cerebral cortical integration and interpretation, therefore it is not a reflex. It requires the entire peripheral (retina, optic nerve) and central visual pathways, as well as the visual cortex and the facial nucleus of cranial nerve VII, to be intact [1,4].

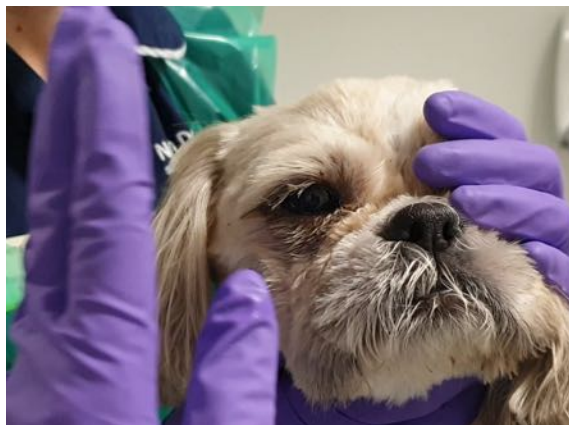

Figure 9. Evaluation of the menace response- note the contralateral eye should be covered during the assessment (North Downs Specialist Referrals)

To avoid **false positive** response from the visual, contralateral eye, the menace response should be evaluated in one eye, while the other eye is covered. It is important to avoid touching the eyelashes/hairs of the patient, or causing air movement, as this may also elicit false positive response. A facial nerve paralysis may cause a **false negative** response. Therefore, in the absence of a menace response the blinking reflex should be assessed by tapping the skin at the canthus. The menace response is absent in very young (<10–12 weeks) animals, and may also be affected by the patient's mental status [1, 5].

In glaucoma, the menace response will be either reduced/inconsistent or absent, due to the retinal ganglion cells damage and reduced axoplasmic flow. If the high IOP persists, the damage can be irreversible leading to blindness.

The *dazzle reflex* (Fig. 10) is a subcortical reflex (mediated by reflex centers in the midbrain with fibers to the facial nucleus) whereby a strong light shone into the eye leads to blinking, globe retraction, third eyelid protrusion, and/or head movement [1]. This is helpful when the ocular media are opaque (hyphaema, cataract) and when the menace response and/or PLRs can't be evaluated. However, it doesn't indicate that the eye is visual, as this reflex can still be present even after retinal detachment due to the presence of a subspecialized population of retinal ganglion cells that are involved in the control of the PLR. Though, when the dazzle reflex is absent in a dog with high IOP it most likely indicates retinal damage and unless immediate action is taken (medical treatment/aqueous centesis), blindness is likely to be permanent.

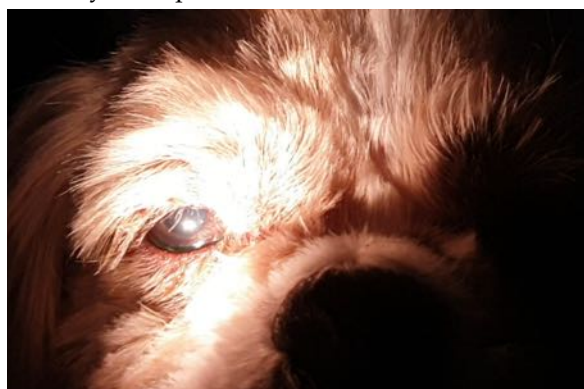


Figure 10. Assessment of dazzle and pupillary light reflexes (North Downs Specialist Referrals)

1. **Tonometry:** there are three methods of estimating the intraocular pressure in animals: the indentation tonometer (Schiotz) which is not routinely available in clinical practice, applanation tonometer (TonoPen)

and the rebound tonometer (TonoVet, Fig. 11). Tonometry is also useful for identifying low IOP, which is common with anterior uveitis; normal values vary between individuals and time of the day (diurnal variation). Normal reported range for the IOP in dogs is 10-20 mmHg. Diurnal variation has been reported in the dog with higher IOPs in the early morning, therefore IOP curves (IOP checks every 3 hours over 24 hours in hospital regime) may be recommended in order to detect IOP spikes in dogs predisposed to or diagnosed with glaucoma [6].

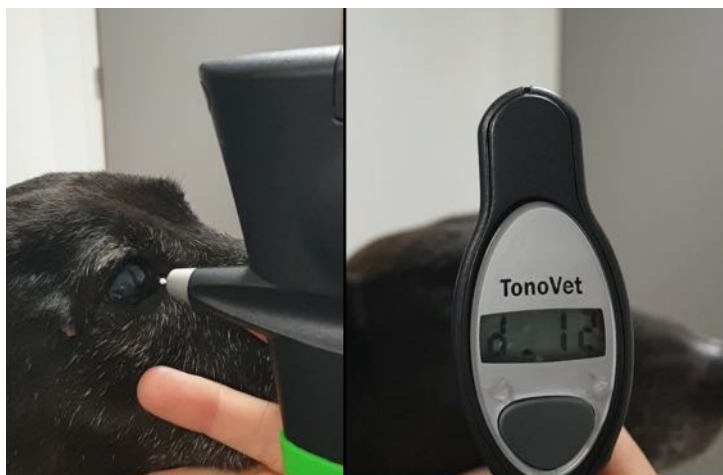


Figure 11. Estimation of the intraocular pressure using the TonoVet (rebound tonometer) in a dog (North Downs Specialist Referrals)

- Ophthalmoscopy:** direct and indirect ophthalmoscopy (Fig. 12) may be used to examine the retina (look for hyperreflective striations or generalized hyperreflectivity) and the health of the optic nerve (Fig. 13, normally the optic nerve head should be well vascularised, the blood vessels should be seen crossing its border). Optic disc cupping (the blood vessels stop at the rim of the optic disc due to increased pressure) is the hallmark of glaucoma [1]; however, this may be difficult to notice in cases of acute congestive glaucoma due to the marked corneal oedema.




Figure 12. Indirect ophthalmoscopy using a 30 D Volk lens- note the optic disc at the top with the retinal vessels, tapetal fundus at the bottom (the image is inverted in indirect ophthalmoscopy) North Downs Specialist Referrals

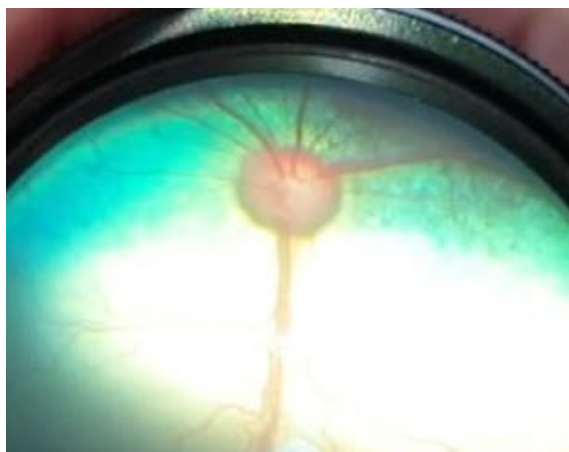

Figure 13. Normal appearance of the optic disc - pink with a physiologic pit centrally, retinal vessels are seen crossing the border of the optic disc (North Downs Specialist Referrals)

3. **Gonioscopy:** facilitates visualization of the pectinate ligament using a gonioscens (eg. Koeppe lens) which refracts the incoming light in such a way that the posterior cornea, ICA and anterior iris can be assessed [1,2]. This test is performed on the conscious dog under local anaesthetic and is used to diagnose goniodysgenesis (predisposition factor for primary glaucoma in a few breeds of dogs); it also provides information regarding the anatomy of the pectinate ligament which makes up the ICA.

There are three categories of ICA appearance (ECVO scheme): open, narrow or closed angle; with this test you can also visualise the base of the iris, pectinate ligaments and the base of the cornea. Abnormalities of the pectinate ligament may be classified into: fibre latae and laminae. Depending on the % of the affected area within the pectinate ligament, the dog may be classed as unaffected or affected (mild, moderate or severe).

4. **Ocular ultrasonography:** can be used to rule out intraocular neoplasia, haemorrhage, vitriitis/vitreous membranes and retinal detachment.
5. **Ultrasound biomicroscopy:** high frequency (50-100 MHz) ultrasound, useful to assess the width of the ciliary cleft/ the opening of the iridocorneal angle [1].

Other tests are available and are not discussed here: chromatic PLR testing, electroretinography (pattern ERG to assess the retinal ganglion cell function), optical coherence tomography (OCT, used to measure the retinal layer and optic nerve head thickness [7]), scanning laser polarimetry (evaluates the retinal nerve fibre layer, may be of use for early detection of glaucoma patients).

4. Discussion

There are two options of dealing with glaucoma in dogs: medical and surgical treatment either alone or in combination. Very early diagnosis and aggressive therapy are generally required to preserve vision and delay the onset of blindness due to retinal and optic nerve degeneration.

In primary glaucoma, despite normalization of the IOP following medical management, the glaucoma continues to progress, thereby supporting the evidence that changes occur at a molecular level and the condition can only be delayed but not cured. Despite aggressive medical or surgical treatment, the outcome is always the same which is blindness and loss of the eye and this needs to be explained to the owner.

Sadly, by the time the owner notices changes in the eye, often the IOP exceeds 40 mmHg therefore glaucoma is a leading cause of irreversible vision loss in dogs. The patient is lethargic and reluctant to exercise and the affected eye becomes blind and appears red, painful and sore with a bluish tinge (corneal oedema) over the cornea. Often the eyes are enucleated because of the painfully high and uncontrolled IOP. Glaucomas can easily mask

underlying systemic diseases, such as infectious uveitis and neoplasia (lymphoma). Submission of the enucleated eyes for histopathological examination is always recommended [1,2].

Treatment of primary glaucoma (table 2): acute glaucoma should be considered an emergency and the IOP must be reduced to the normal range in order to save the patient's vision; hospitalization is required and treatment is generally commenced with topical prostaglandin analogues. If the IOP doesn't return to normal within the first 30–60 min then the use of osmotic diuretics or aqueous centesis should be considered.

In current clinical practice, ophthalmologists rarely use osmotic diuretics due to the availability of prostaglandin analogues which are as or even more efficient without the risk of inducing side effects. Furthermore, osmotic diuretics should be cautiously used as they are contraindicated in patients with kidney disease, owing to the risk of causing dehydration and electrolytes imbalance. The use of osmotic diuretics has been generally replaced by prostaglandin analogues (eg latanoprost) combined with topical carbonic anhydrase inhibitors (brinzolamide, dorzolamide) and beta-blockers (eg timolol).

Treatment of glaucoma should be aimed at two directions:

- Decreasing the aqueous humor production: carbonic anhydrase inhibitors, beta-blockers. Alternatively, surgery aimed at destroying the ciliary processes thereby reducing the aqueous humor production may be considered: endocyclophotocoagulation, transscleral laser with its potential risks and complications [7,8]. Because newly developed glaucoma medications are emerging at a very slow rate and may not be effective, working toward improving surgical options may be the most rewarding approach in the near term [8].
- Increasing the aqueous humor outflow: eg. prostaglandin analogues (eg. latanoprost). One effect of this class of hypotensive drugs is the secondary miosis as well as conjunctival hyperaemia, due to the increased vasodilation (Fig. 14). Surgery to create alternate pathways of drainage within or outside of the eye (anterior chamber bypass surgery) may be considered with its potential risks and complications [8, 9].

Others less commonly used hypotensive drugs include osmotics, adrenergics (non-selective alfa, beta-agonists epinephrine, dipivalyl epinephrine, alfa-2 agonists such as apraclonidine, brimonidine) and adrenergic blockers, parasympathomimetics (pilocarpine, carbachol, demecarium bromide, ectothiopate iodide) and are not discussed here [1,2].

Typically, a primary glaucoma patient will receive combinations of carbonic anhydrase inhibitors, beta-blockers and prostaglandin analogues (eg. dorzolamide, timolol and latanoprost) as ongoing medical treatment with frequency which depends on the IOP readings.

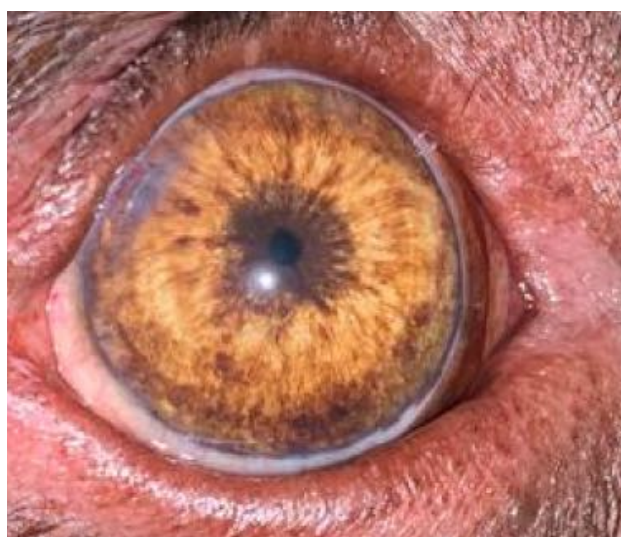

Figure 14. The effect of latanoprost application, leading to extreme pupil (North Downs Specialist Referrals)

Although there is no clear-cut evidence, long-term anti-glaucoma medication (e.g. with topical carbonic anhydrase inhibitors and beta-blockers such as dorzolamide and timolol q8 hours) for the second, predisposed, but normotensive eye should be considered [2].

Analgesia should be considered in dogs with glaucoma. An IOP over 35 mmHg causes migraines in people. Dogs with glaucoma are typically less active, lethargic, they sleep more, eat less and are less willing to go for walks. Analgesia should be provided in the form of systemic non-steroidal medication, paracetamol and/or opioids if there are no contraindications.

Treatment of secondary glaucoma depends on the etiology; therapy may consist in the removal of the lens in cases of primary lens luxation to enucleation for those secondary to an intraocular tumor, but in all cases referral to a veterinary ophthalmologist should always be considered and discussed with the owner.

In blind eyes, the treatment options include: transscleral laser, intravitreal injection of gentamicin [10, 11] with a reported IOP control of 65%- 85%, intravitreal injection of cidofovir [12] with a reported IOP control of 97% and enucleation.

Table 2. Most commonly used hypotensive drugs for glaucoma in dogs and cats

Source: Adapted after [8]

Drug	Available Preparations	Dose or Timing	Contraindications
Osmotic diuretics			
Mannitol	20% solution Only in acute congestive glaucoma	1-1.5 g/kg i.v. slowly over 20 min	cardiac or renal disease, dehydration, chronic glaucoma
Prostaglandin analogues			
Latanoprost	0.005% solution	q12-24 h, can be increased to q6-8 hours until a response is seen	severe uveitis, anterior lens luxation
Travoprost	0.004% solution		
Bimatoprost	0.03% solution		
Carbonic anhydrase inhibitors			
Brinzolamide	1% solution	q8-12h	none in dogs, but may cause local irritation shortly after instillation; keratitis, corneal oedema, blepharitis (especially dorzolamide) systemic absorption can lead to acute kidney injury in cats (check electrolytes before starting treatment) [13, 14]
Dorzolamide	2% solution		

β -adrenergic blockers			
Timolol maleate	0.25% and 0.5% solution	Q8-12h	cardiac or respiratory disease use cautiously in cats and small dogs due to systemic absorption, cautious in dogs with asthma and chronic bronchitis

5. Conclusions

Despite medical therapy, a significant proportion of cases may require surgery in an attempt to keep the IOP within the normal range and delay the progression of glaucoma and blindness or to reduce the ocular discomfort. The prognosis depends on the underlying cause of glaucoma. Long-term therapy is necessary and regular intraocular pressure checks are required in order to ensure a normotensive and comfortable eye. Eyes that have lost vision but still have an increased pressure are a source of chronic pain. In such cases, enucleation must be considered to guarantee the well-being and comfort of the patient. Due to the aggressive and progressive nature of the disease, most animals lose their vision despite treatment, therefore their owners should be carefully advised regarding the prognosis of this disease.

Author Contributions: All authors have read and agreed to the published version of the manuscript.

Funding: This research received no external funding.

Conflicts of Interest: The authors declare no conflict of interest.

References

1. Gelatt, K.N.: *Veterinary Ophthalmology, Fifth Edition*, Wiley-Blackwell, 2013:1050-1146.
2. Maggs, D.J.; Miller, P.E.; Ofri, R.; Slatter's Fundamentals of Veterinary Ophthalmology, *Fourth Edition*, Elsevier Inc., Philadelphia, 2008:81-106, pp. 230-249.
3. Peiffer, R.L.; Petersen-Jones, S.M.; *Small Animal Ophthalmology: A Problem-Oriented Approach, Fourth Edition*, Elsevier Inc., Philadelphia, 2008:120-123, pp. 227-234.
4. Reinstein, S.; Rankin, A.; Allbaugh, R.: Canine glaucoma: pathophysiology and diagnosis, 2009:450-452.
5. Gelatt, K.N.; *Ophthalmic examination and diagnostic procedures*, ed. *Essentials of Veterinary Ophthalmology*. Philadelphia: Lippincott Williams & Wilkins, 2000:1-26.
6. Sanchez RF, Vieira da Silva MJ, Dawson C. Design of an intraocular pressure curve protocol for use in dogs. *J Small Anim Pract*. 2017 Jan;58(1):42-48.
7. Graham, KL, McCowan, CI, Caruso, K, et al.: Optical coherence tomography of the retina, nerve fiber layer, and optic nerve head in dogs with glaucoma. *Vet Ophthalmol*. 2020; 23: 97- 112.
8. Komáromy, A.M.; Dineli, B.; Douglas, W.E. et al.: The Future of canine glaucoma therapy. *Vet Ophthalmol*. 2019:726-728.
9. Willis, A.M.; Ocular hypotensive drugs. *Vet Clinics of North America: Small Animal Practice* 2004:755.

10. Julien, M.E., Schechtmann, S.A., Michau, T.M. et al.: Pharmacologic ciliary body ablation for chronic glaucoma in dogs: A retrospective review of 108 eyes from 2013 to 2018; *Vet Ophthalmol.* 2021; 24(Suppl. 1): 125– 130.
11. Rankin, A.J., Lanuza, R., KuKanich, B., et al.: Measurement of plasma gentamicin concentrations postchemical ciliary body ablation in dogs with chronic glaucoma. *Vet Ophthalmol*, 2016; 19: 57-62.
12. Low MC, Landis ML, Peiffer RL.: Intravitreal cidofovir injection for the management of chronic glaucoma in dogs. *Vet Ophthalmol.* 2014 May;17(3):201-6.
13. Thiessen, E.C.; Tofflemire, K.L.; Makielski, K.M. et al.: Hypokalemia and suspected renal tubular acidosis associated with topical carbonic anhydrase inhibitor therapy in a cat. *Journal of Veterinary Emergency and Critical Care* 2015:1–5.
14. Czepiel, T.M.; Wasserman, N.T.: Hypokalemia associated with topical administration of dorzolamide 2% ophthalmic solution in cats. *Vet Ophthalmol.* 2021;24:12-19.