

Case report

# The influence of Electroacupuncture on a dog diagnosed with osteoarthritis: A case report

Madalina Florina Dragomir <sup>1\*</sup>, Cosmin Petru Pestean <sup>1</sup> and Liviu Oana <sup>1</sup>

<sup>1</sup> Department of Surgery and Anesthesiology and Intensive Care, University of Agricultural Science and Veterinary Medicine Cluj-Napoca, Calea Manastur no. 3-5, 400372, Cluj, Romania; [cosmin.pestean@usamvcluj.ro](mailto:cosmin.pestean@usamvcluj.ro); [oanaliviu2008@yahoo.com](mailto:oanaliviu2008@yahoo.com)

\* Correspondence: M.F.D; PhD Student; e-mail: [madalina.dragomir@usamvcluj.ro](mailto:madalina.dragomir@usamvcluj.ro); Tel.: 0040748103455; <https://orcid.org/0000-0002-5287-4370>

**Abstract:** Electroacupuncture is a specific branch of acupuncture that uses electrical stimulation through the selected acupoints. Osteoarthritis is considered a complex condition associated with painful joints and locomotor dysfunction.

The aim of this case report was to bring scientific support regarding the effect of electroacupuncture in a dog with chronic joint degeneration.

An 11-year-old male German shepherd referred to the University of Agricultural Sciences and Veterinary Medicine of Cluj with severe pain in his hind limbs and around his back. Diagnosis based on a western examination, neurological assessment and radiographs indicated chronic osteoarthritis with hip dysplasia. From Traditional Chinese Veterinary Medicine based diagnosis was Kidney Qi Deficiency leading to Bony Bi Syndrome. For the last two years, the treated dog with Mavacoxib (single dose every month) did not show any significant improvement.

A combination of a fine needle with dry acupuncture, electroacupuncture (30-40Hz alternated with 80-100 Hz) and aqua-acupuncture using Zeel (AP) was performed. During the winter, weekly treatment was planned, after that, every two weeks treatment with electroacupuncture and dry needle, for five months until the present.

Since we started the acupuncture treatment, the dog is more active and enjoys playing again. We have managed to stop the administration of NSAID's and improve his life quality.

In the present study, we evaluated the effect of complementary medicine on a dog with chronic pain and joint degeneration. Electroacupuncture is a complex technique that requires special training; if used wisely, it can be an excellent complementary therapy for veterinary patients' pain control.

**Keywords:** dog; electroacupuncture; osteoarthritis; complementary medicine.

Received: 5.06.2021

Accepted: 11.08.2021

Published: 09.09.2021

DOI:10.52331/cvj.v26i2.24



**Copyright:** © 2021 by the authors. Submitted for possible open access publication under the terms and conditions of the Creative Commons Attribution (CC BY) license (<http://creativecommons.org/licenses/by/4.0/>).

## 1. Introduction

Osteoarthritis (OA), also known as a degenerative joint disease (DJD), is an inflammatory condition that occurs progressively in the joint as a result of loss of hyaline cartilage[1]. Cartilage is made of chondrocytes and is composed of type II collagen and a proteoglycan called aggrecan, which represents the link with hyaluronic acid[2]. In cases of OA, with the appearance of predisposing factors such as age, injury or various pathologies (obesity, poor conformation, prior elbow or hip dysplasia), the cartilage begins to decompose. This action leads from pain to immobility due to inflammation. It is most common in the lower limbs and in the lumbar-sacral area[3]. Large breed dogs, such as German Shepherd, Labrador or Golden Retrievers are more predisposed to this condition[3].

Traditional Chinese Veterinary Medicine (TCVM) has its origins in Old China and has been used for treating animals for thousands of years until present[4].

Meridians are represented by a complex system in which all the tissues and organs are connected and have an important role in the treatment of acupuncture[4]. The meridians transport the Qi and Blood through the whole body. This communication allows all the organs to coordinate and maintain an equilibrium of the system[4].

Acupuncture (Ac) is a complex method that uses very thin, filiform needles that are inserted in special points called "acupoints". Some recent studies show that these acupoints are actually the "locus" where nerves enter tissues or branches[5].

Electroacupuncture (EA) uses electric current (alternative, continuous or intermittent) which passes through needles that are already inserted into acupoints. EA is useful in case of degenerative lesions of the nervous system[5].

The aim of this study was to investigate the efficacy of EA and assess an acupuncture protocol for pain management in the case of OA. Also to reduce or, if possible, stop the administration of NSAIDs and improve quality of life.

## 2. Materials and Methods

### 2.1. Case description

Rufus is an 11 years old, male, German shepherd with chronic pain on his hind limbs, hip dysplasia and chronic keratitis. About 3 years ago, the dog started to have back pain around his hips and to crawl his hind limbs. Since then he was kept on NSAIDs (Mavacoxib – single dose every month) and Gabapentin when needed. From time to time, he loses stool and eats a smaller quantity of food, but after that, he starts eating better.

On October 2020, when M.F.D examined the dog for the first time. The mucous membranes were pink with a capillary refill of <2sec. The overall conformation was good with a 7/9 nutritional status. The coat was good, except for a small amount of hair loss. The dog was panting, but the respiration was unlabored. The body temperature was slightly elevated at 38.3°C. The pulse rate was 96 bpm. Neurological examination was within normal except for the presence of pain in the caudal area of the hips and proprioception was delayed on his right back leg.

From the TCVM point of view, the patient has an outward appearance as previously described. When observed, Rufus seems to be an Earth Constitution; he is friendly and communicative with people, but with other animals is aggressive, especially with cats. He lives with another German Shepherds, female and a Golden Retriever, male. He likes to be with people in the house, but he prefers to sleep outside. Rufus has a capricious appetite; he eats dry kibbles and cooked food (meatballs with different herbs). The dog prefers cold and seems better when he stays outside, in the yard. The tongue is slightly pale, thin with a white coat. The pulse was stronger on his left side. Sensitivity was noticed at Bladder (BL 17), Bladder (BL18), Bladder (BL 20), Bladder (BL22), Bladder (BL 23) and Bai-Hui. He did not let me touch his back.

From a Western diagnostic point of view, Rufus has hip dysplasia and osteoarthritis. From TCVM diagnostic point of view, Rufus has Bony Bi Syndrome (Kidney Yang and Qi Deficiency) and Blood Deficiency.

### 2.2. Treatment plan

A combination of a fine needle, dry acupuncture (Ac), electrical acupuncture (EA) at 80-100 Hz, aqua-acupuncture using (AP) was performed. Weekly treatment during the winter was planned. After that, every two weeks treatment with EA and Ac, until in present.

The treatments were performed using sterile disposable stainless-steel Ac needles with copper coil handle, size 0.25x25mm, guide tubes (Acimut), and stainless-steel Ac needles with plastic handle, size 0.22x25mm, without guide tubes (Cloud and Dragon) and sterile acupuncture needles 0.25x30mm with silver handle (Ener-Qi). Dry needling (insertion at 1cm-1.5cm with an intermittent manipulation of the point by twirling anti-clockwise) and EA (insertion at 1cm-1.5cm, 40Hz and ~1.5V-2V for the first 5-10 minutes, then 80-120Hz and ~1,5V-2V for 10-20 minutes) was used during the 15-20 minutes of each treatment, depending on the reaction of the dog. The acupoints used are presented in Table 1. We used Electro-Acupuncture Stimulator JM-3A by Dr Xie Huisheng (Figure 1). During each treatment, a maximum of six to eight points were used, depending on dog's reaction. The acupoints were selected according to TCVM principles. Every once a month we used Zeel injection solution (2.0 ml Ampules).

Table 1 Acupuncture points used

Local points	Bai-Hui, Shen-Shu, Shen-Peng, Shen-Jiao
Constitutional points	GV20, KID3, KID6, BL23, ST36, GB29, GB30, BL54
Association Points	BL11, BL18, BL20



Figure 1. Electro-Acupuncture Stimulator JM-3A by Dr. Xie Huisheng


### 3. Results

#### 3.1. Treatment and results

Unfortunately, OA is a progressive disease and there is no known cure for it[3]. The best way to keep a dog's joints healthy is to prevent the reproduction of the ones already diagnosed with hip dysplasia, weight management and prevention of obesity and joint supplements in order to reduce inflammation and slow progression of joint damage[3]. NSAIDs remain a popular treatment for OA despite their well-known side effects that may occur with their long-term use[1].

In the case of Rufus, he was on Mavacoxib also known as Trocoxil, for more than two years, one dose every month. He was also on chondroprotective such as Glucosamine and Chondroitin and gastric protectors. From time to time he developed diarrhea and capricious appetite, which we assume might be side effects of NSAIDs.

Since the condition appeared to be amenable to Ac therapy and had not previously responded well to conservative treatment, the owner decided to pursue Ac treatment (Figure 2 and 3). Alternatively, conservative management could be continued with chondroprotective.



**Figure 2.** Rufus sleeping during the electroacupuncture treatment.

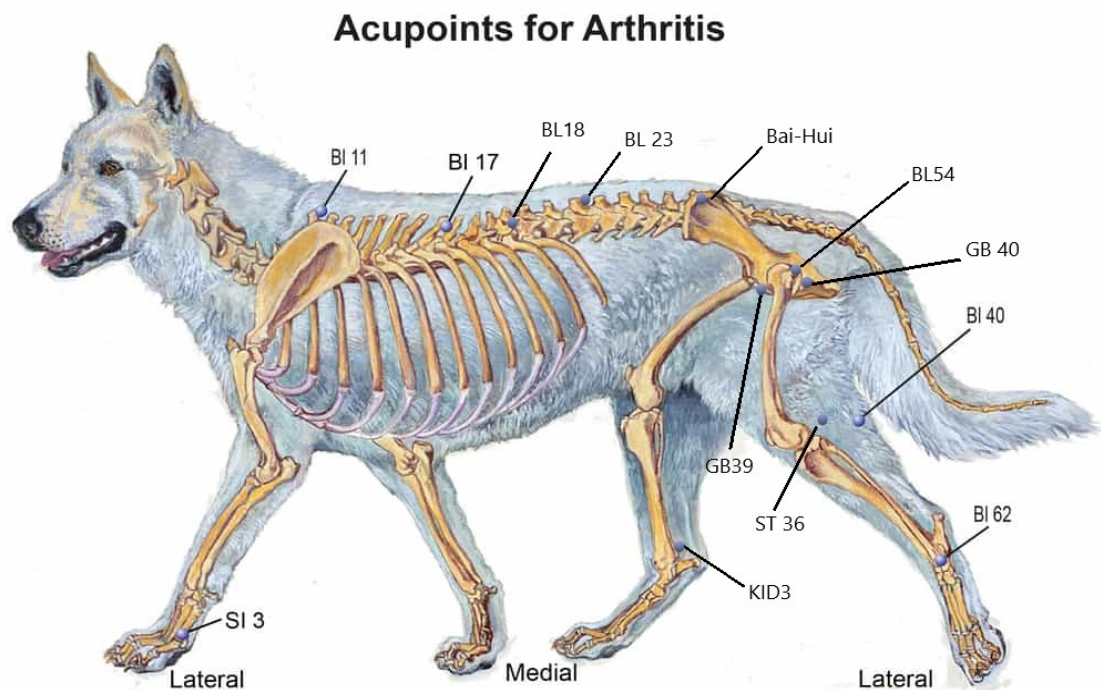


**Figure 2.** Rufus during the treatment: LIV3 (bilaterally), KID3.

During the winter, weekly treatment was planned in order to reduce the inflammation and also the side effects that may occur once the cold weather is coming. Most of the time, the dog stays outside the house. During each treatment, the dog relaxes and starts to sleep. The owners said that he had slept several hours after each session.

After the fourth treatment, the dog started to have more energy, enjoys long walks and playing. Also, now he enjoys being rubbed on his back. Most important, we've managed to stop the administration of NSAIDs for 6 months since we started the acupuncture treatment until the present. The owners are very pleased with the evolution of their dog. We've managed to improve his life quality.

The Kidney Meridian represent the root of prenatal life and holds the Jing, also known as life essence. Moreover, Kidney along with Bladder control water metabolism and regulates its excretion, and dominates the bones and marrow. As the animal increases with age, the Qi is consumed and the Kidney Patterns include diseases such as urinary incontinence, intervertebral disc disease or arthritis [4]. Each acupoint has a specific role in the treatment of this pathology. The aim of each acupuncture treatment is to re-establish the equilibrium of the whole body. Some of the most used acupoints in treating OA are represented in the adapted Figure 3 [6]. We must remember that this type of treatment should be used only by trained practitioners in order to have the best results.



**Figure 3.** Some of the acupoints used for treatment. Adapted after [6].

#### 4. Discussion

The aim of this study is to bring relevant information and to describe a complementary method for the treatment of OA in dogs.

Western medicine is described as a medical method to treat a disease process, while TCVM is more about creating a balance with Qi flow through the body[5]. Each of them has strengths and weaknesses,

but the main purpose of both is to cure diseases, this is one of the reasons why TCVM is considered complementary medicine. As so, TCVM continues to change and to adapt as the new medical information are developing into the medical field[4].

From a Western point of view, an alternative could have been surgery, which would involve total hip replacement to treat his hip dysplasia. However, because he would need both hips to be replaced, the recovery time and the costs would have been too much. The owners would not afford it, especially because of the risk involving the anaesthesia.

Another treatment option could include administration of NSAIDs such as Meloxicam, Mavacoxib, Carprofen or Robenacoxib, but in time, this type of drug has side effects, especially in the gastrointestinal tract[1,7]. According to Monteiro-Steagall's[8] study about the side effects of NSAIDs, more than 50% of the studies reported adverse effects. Of course, we cannot exclude these treatments in the acute phase of OA. On the other hand, Teixeira et al.'s study showed neither acupuncture nor carprofen differs significantly. Both treatments reduced the degree of lameness, while acupuncture was associated with a decrease in validated chronic pain scores[9].

From a TCVM point of view, Rufus was diagnosed with Bony Bi Syndrom, or Kidney Yang and Qi Deficiency. A Kidney Qi Deficiency Pattern is, generally described as an animal's condition in old age, weakness with difficulty in rising. The Kidney dominates the lower back and hind limbs, and when there is a problem with Qi flow in this area, a deficiency might occur. General speaking, a chronic condition with Kidney Qi Deficiency leads to Kidney Yang Deficiency in time, if not treated[4]. In other words, we will have an animal with difficulty in standing up or lying down, cold back, hind limbs and ears and warm seeking (the animal want to stay in warm places, lay in the sun, or even refuse to go outside if is rawish)[10].

EA is a superior method of stimulating specific acupoints by using electric current applied through the needles. EA can be applied with different machines that have the ability to offer a wide range of amplitude and frequency[5]. Furthermore, you can customize each treatment. When compared to Ac, EA has the advantage of shorting the treatment time and delivers a better level of stimulation[5].

AP was made with Zeel, once a month. Zeel offer a safe and effective homeopathic alternative. It is the treatment for hip osteoarthritis, joint pain, bone fracture and stiffness from mild to moderate and high form. Zeel is particularly effective in relieving the symptoms associated with degenerative arthritis[14]. It is made of plants and was used as an injection in certain acupoints.

The mechanism involved in acupuncture includes pain management through muscle relaxation, reducing compression in the joints, but also increasing blood flow with oxygen to the tissues. All these actions translate into reducing inflammation at the site of acupuncture[9,11].

Mechanisms of acupuncture involve increases in plasma  $\beta$ -endorphin concentration, which is responsible for inhibiting presynaptic pain transmission. Also, serotonin is involved in relieving pain[12]. In addition to the anti-inflammatory and immune-boosting effects, acupuncture alleviates physical and emotional stress[13]. Furthermore, it accelerates the process of healing tissues through the release of endorphins and serotonin[12,13].

The limitations of this study are related to the need for more accurate parameters regarding the effect of acupuncture. In the future, studies are needed on larger samples of dogs with OA, respectively, more comparative studies between acupuncture, electroacupuncture and Western medicine.

## 5. Conclusions

EA confers excellent analgesia and lessens the time needed to regain normal neurologic function, but what we must not forget is that rigorous training of the acupuncturist is required to have good results. Each acupoints has a precise position, and the treatment plan is chosen according to several parameters within which TCVM works.

## 6. Patents

**Author Contributions:** Conceptualization, M.F.D; Writing- original drag preparation, M.F.D., Supervision, C.P.P. and L.O. All authors have read and agreed to the published version of the manuscript.

**Funding:** This research received no external funding.

**Institutional Review Board Statement:** Not applicable.

**Data Availability Statement:** The data used to support the findings of this study are included in the article.

**Acknowledgements:** No financial support has been received for this study.

**Conflicts of Interest:** The authors declare no conflict of interest.

## Appendix A

### Acupuncture points used and their clinical relevance[4]:

- GV20: Calming point, Shen Disturbance;
- GB29/GB30: Gluteal muscle soreness, pelvic limb pain, arthritis of coxofemoral joint;
- KID3: Dyspnea, deagness, back pain;
- KID6: Insomnia, dysuria, Yin Deficiency;
- BL54: Master point for pelvic limbs, hip problems, lumbar pain;
- BL23: Association point for Kidney Qi Deficiency, deafness, back pain;
- BL20: Association point for Spleen, abdominal fullness, back pain;
- BL18: Association point for Liver, back pain, epilepsy;
- BL11: Influential point for Bone, cervical stiffness, intervertebral disc disease, back pain;
- ST36: Master point for gastrointestinal tract and abdomen, gastric pain, general tonic;
- Bai-Hui: Yang Deficiency, intervebral disc disease, pelvic limb paresis;
- Shen-Shu/Shen-Peng/Shen-Jiao: Yang Deficiency, pelvic limb paresis or paralysis.

## References

1. Spencer, A.J.; Ronald, M.M.; Steven C, B. Nonsurgical Management of Osteoarthritis in Dogs. *Vet. Clin. North Am. Small Anim. Pract.* **2008**, *38*, 1449–1470, doi:<https://doi.org/10.1016/j.cvsm.2008.08.001>.
2. Philip Tisdall, K.R. *Pathology*; USMLE Step 1; Becker Professional Education Corp: United States, 2018;
3. Parnell's Glyde Mobility Chews Osteoarthritis in Dogs — Signs and Treatment 2021.
4. Vanesa Preast, H.X. *Traditional Chinese Veterinary Medicine - Fundamental Principles*; 2nd ed.; Chi Institute Press: Reddick, Florida, 2013;
5. Dragomir, M.F.; Oana, L.; Pestean, C.; Purdoiu, R. Current Aspects Regarding the Clinical Relevance of Electroacupuncture in Dogs with Spinal Cord Injury: A Literature Review. *Animals* **2021**, *11*, 219, doi:<https://doi.org/10.3390/ani11010219>.
6. AMY SNOW, N.Z. Acupressure Points For Canine Osteoarthritis 2020.
7. Johnston SA, W.D. et al. The Effect of Dosing Interval on the Efficacy of Misoprostol in the Prevention of Aspirin-Induced Gastric Injury. *J Vet Intern Med* **2003**, *17*, 282–290, doi:10.1016/j.cvsm.2008.08.001.
8. B.P. Monteiro-Steagall, B.D.X.L. Systematic Review of Nonsteroidal Anti-Inflammatory Drug-Induced Adverse Effects in Dogs. *J Vet Intern Med* **2013**, doi:10.1111/jvim.12127.
9. Lívia R. Teixeira, A.H.-B. et al. Owner Assessment of Chronic Pain Intensity and Results of Gait Analysis of Dogs with Hip Dysplasia Treated with Acupuncture. *Small Anim. Exot.* **2016**, *249*, doi:10.2460/javma.249.9.1031.
10. Xie Huisheng Chinese Veterinary Herbology. In *CHINESE VETERINARY HERBOLOGY*; 2010; pp. 295; 488.
11. Ma M Ma Y-t, C.Z. Peripheral Mechanisms of Acupuncture. *Elsevier* **2005**, 31–48.
12. S, A. Clinical and Endocrino Logical Changes after Electro-Acupuncture Treatment in Pa Tients with Osteoarthritis of the Knee. *Pain* **2009**, *147*, 60–66.
13. Lin JG, C.W. Acupuncture Analgesia: A Review of Its Mechanisms of Actions. *Am J Chin Med* **2008**, *36*, 635–645.
14. Star Medical Zeel Comp N (Zeel T) 10 Fiole - Produs Homeopat, Tratament Antireumatic ~ Coxartroza, Gonartroza, Dureri Articulare, Afectiuni Reumatismale, Reumatism Poliarticular, Fracturi Osoase, Inflatatii Articulare.