

A pilot study on the use of biolase in the treatment of recurrent aphthous ulcer

Nazih shaban Mustafa¹, Muhannad Ali Kashmoola¹,
Muhamad ZulhelmiBaharudin², Hafiz Izzuddin Hashim²,
Omar Abdul Jabbar¹, Basma Ezzat Mustafa Alahmad³

¹ Department of Oral Maxillofacial Surgery and Oral Diagnosis, Kulliyah of Dentistry, IIUM Kuantan Campus

² Student, Kulliyah of Dentistry, IIUM Kuantan Campus

³ Department of fundamental basic medical sciences, Kulliyah of Dentistry, IIUM Kuantan Campus

Corresponding author:

Basma Ezzat Mustafa Al-Ahmad
Address: Kulliyah of Dentistry,
International Islamic University
Malaysia, Bandar Indera Mahkota,
25200 Kuantan, Pahang, Malaysia
Email: drbasma@iium.edu.my
Office: 006095705487
Fax: 00605705580

Received: March 22, 2018

Accepted: May 24, 2018

Recurrent Aphthous Ulcer (RAU) is a common oral pathology that produces pain which affects the lifestyle of the patient. Its aetiology and pathogenesis still remain unclear. A considerable number of treatments are available with the main goal directed towards pain relief. Previous studies on RAU treatment using low level laser therapy (LLLT) show immediate pain relief after application. **Aim:** This study aims to evaluate and compare treatment effectiveness in relieving pain provided by Waterlase (BIOLASE) LLLT and conventional topical corticosteroid using Triamcinolone Acetonide 0.1% dental paste. **Methods:** Thirty (30) volunteered patients of age between 18-27 years old were divided into two groups. Each group consists of 15 patients with 7 males and 8 females. Group 1 patients were treated by using LLLT while group 2 patients were treated by using triamcinolone acetonide 0.1%. The patient's details, pain intensity and clinical photographs were recorded in a specially prepared case sheet. Mann-Whitney U test was used to compare significance in pain reduction provided by both methods of treatment. **Results:** Both groups showed significant pain reduction immediately, day 3 and day 7. Higher reduction in pain intensity was observed immediately ($p=0.001$) and 3 days ($p=0.002$) after treatment in group 1 patients (LLLT) compared to group 2 patients (triamcinolone acetonide 0.1%). **Conclusion:** Waterlase (BIOLASE) LLLT is clinically more effective in relieving pain compared to Triamcinolone Acetonide 0.1%.

Keywords: Laser therapy. Lasers. Stomatitis, Aphthous. Ulcer.



Introduction

Recurrent aphthous ulceration (RAU) a common oral mucosal disease. Prevalence varies from 5% to 20% and has a predilection towards female. Generally, RAU presents as single or multiple, flat, ovoid or round ulceration on the oral mucosa. The lesion has characteristic appearance of yellow-white fibrinopurulent membrane surrounded by thin erythematous halo. Typically, RAU occurs in the nonkeratinized part of the oral mucosa most often appearing at the buccal and labial mucosa followed by ventral surface of the tongue, mucobuccal fold, floor of the mouth and soft palate. The recurrence rate of RAU varies from one to two episodes per month¹. It has a characteristic prodromal burning sensation lasting 2-48 hours before ulcer appearance. The ulcer results in damaged oral mucosal epithelium with exposed nerve endings causing pain and discomfort to the patient. The latter affects the patient's quality of life by diminished ability to eat, drink and maintain a good oral hygiene².

RAU can appear in three forms; minor, major and herpetiform. Several clinical presentation criteria such as size, number, localization and duration of lesion are used to distinguish between the three different forms. Minor type appears most commonly. It is characterized by single or multiple (1-5) lesions of less than 1cm in diameter and heals within 7 to 10 days without scarring. Typically it heals within 1 to 2 weeks with scarring³. The aetiology of RAU remains unclear. However, several factors such as genetic, trauma, immunological factor, haematological or nutritional deficiencies, menstruation cycle, upper respiratory infection and psychological stress have been proposed that render an individual more susceptible to develop RAU⁴.

Therapy for RAU aims to relieve pain and promote healing. Despite the availability of several treatment modalities in the objective to reduce patient's discomfort and pain, an immediate therapeutic regimen is yet to be provided⁵. Several treatment options are available, however the main stay of RAU treatment uses topical corticosteroids. Topical corticosteroids are formulated in paste form such as Triamcinolone Acetonide 0.1%, act by limiting the inflammatory process associated with the lesion and provide a temporary symptomatic relief. The paste is to be applied 3-4 times daily directly onto the lesion to form a protective film. Conventional method however is rather symptomatic than curative⁶.

Low level laser therapy (LLLT) uses low power laser to modulate inflammatory response which reduces edema and pain while enhancing cellular biostimulation⁷. Studies have suggested that LLLT could be a positive alternative or adjunct treatment that provides immediate pain relief in RAU patients⁷⁻⁹.

Albrektson et al.¹⁰ (2014) concluded that LLLT proves to be more superior to Fito-stimule Gel in treating aphthous ulcer. Use of LLLT to treat chronic RAU is claimed to be a reliable therapeutic modality and showed greater efficacy than pharmacotherapy¹¹. Aggarwal et al.¹² (2014) concluded that LLLT is a safe and effective treatment options in treating aphthous ulcer. Application of LLLT enhances the speed of wound healing, provides significant analgesia, and cause no major side effects to the subjects treated¹³.

MATERIALS AND METHODS

This research is done on volunteered patients referred to the oral medicine clinic in Kulliyah of Dentistry, IIUM. Subjects received a full disclosure of the nature of the study with an extended opportunity to ask questions prior and throughout participation. Informed and written consent were obtained and recorded; patient's data were kept confidentially for research purposes only. Ethical approval was obtained from IIUM Research Ethics Committee (IREC) (REF NUMBER: IIUM/504/14/11/2/ IREC 705).

Patient selection

The subjects are volunteered patients who presented to the oral medicine clinic with a complaint of pain from RAU. Full history taking and examination were done by the operator and presented to the supervisor (specialist). Patients with confirmed diagnosis of RAU were selected.

Sampling Method and Sample Size

This is a pilot study, a total of 30 patients (14 male and 16 female) in which all are Malays who attended the oral medicine clinic at Kulliyah of Dentistry, IIUM were divided into two groups. Group 1 consisting of 15 patients were treated with LLLT while group 2 consisting of 15 patients were treated with triamcinolone acetonide 0.1% dental paste. **Exclusion criteria:** Patients through history and examination with known: Smoking, Systemic disease, Immune compromised patients, Pregnancy

Methodology

Patients were asked to rate the pain of the ulcer during the visit using Numerical Rating Scale (NRS-11) prior to treatment.

Group 1 consist of 15 patients referred to the oral medicine specialist clinic. Prior to LLLT application, patients were seated on the dental chair, full personal protective equipment (PPE) always worn by the operator and the assistant. Protective eyewear were worn by the operator, assistant and the patient to prevent potential damage by the reflective energy from the laser irradiation. The type of laser used was Er, Cr: YSGG laser by Waterlase MD, Biolase, Irvine, CA, USA. The laser unit was set at 0.5 W - 30 Hz for low level energy with 20% air and without water coolant spray. The laser beam was applied on the ulcer lesion for 30 seconds with continuous circular motion. The distance between the laser tip and the surface of the ulcer was maintained at about 5mm throughout application of single unit dose.

Group 2 consisting of 15 patients were treated with triamcinolone acetonide 0.1% dental paste. The surface of the ulcer was dried using a sterile gauze and the paste was applied using a cotton roll to form a thin film over the lesion surface. Patients were instructed to apply the paste twice daily; before a meal and before bed for 7 days.

Patients from both groups were instructed to refrain from using any other type of medication to relief the ulcer pain for a period of 7 days. The pain score of the ulcer was

evaluated immediately, after 3, and 7 days. Follow up by using NRS-11 together with photographic record of the lesion., all data were collected into a special case sheet .

Data analysis

The collected data were analysed using SPSS software version 21. Intragroup and intergroup comparisons were evaluated using Wilcoxon Signed Rank Test and Mann Whitney U test respectively.

RESULTS

Demographic profile was presented in terms of category, frequency and percentage. For reliability of the sample, based on Cronbach's alpha, the reliability is 0.681 which is unacceptable scale (Table 1). Coefficient of alpha between 0.5 to 0.8 is considered an acceptable level of internal reliability for scales, where group comparisons are to be made.

Table 1. Demographic profile

Category	Frequency	Percentage (%)
Gender		
Male	14	46.7
Female	16	53.3
Total	30	100
Age		
18 – 22 years old	8	26.7
23-27 years old	22	73.3
Total	30	100
Type of Treatment		
LLLT	15	50
Triamcinolone Acetonide	15	50
Total	30	100
Number of Ulcer		
Single	22	73.3
Multiple	8	26.7
Total	30	100
Type of Ulcer		
Minor	30	100
Major	0	0
Total	30	100

The Mean pain score based on type of treatment immediately, on day 3 and day 7 after LLLT application is lower compared to Triamcinolone Acetonide by which laser shows more pain score reduction compared to Triamcinolone Acetonide. After 7 days of treatment, complete pain relief was observed in LLLT group compared to Triamcinolone Acetonide group which still has some degree of pain (Figure 1)

Significant difference in pain reduction is evident immediately (<0.001) and 3 days (0.002) after treatment when mean pain score of LLLT and Triamcinolone Acetonide groups are compared. However, no significance difference in pain reduction is noted 7 days post treatment (Calculated using Wilcoxon Signed Rank Test ---- intragroup comparison).

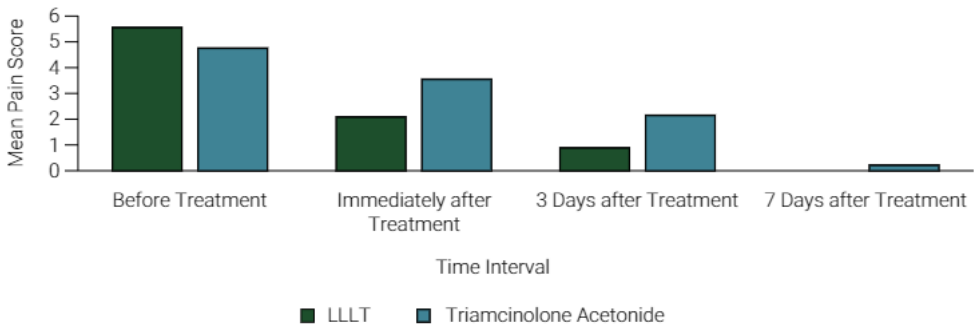


Figure 1. Mean pain score before treatment, immediately, on day 3 and day 7 after treatment.

Table 2 and 3 show no significant difference in pain reduction in patients of different gender ($p > 0.05$) and age groups ($p > 0.05$).

Table 2. Comparison between mean reductions of pain score between genders

Reduction of Pain Score	LLLT		p-value*	Triamcinolone Acetonide		p-value*	Male versus Female p-value*
	Male	Female		Male	Female		
	Mean \pm SD	Mean \pm SD		Mean \pm SD	Mean \pm SD		
Before Treatment (Baseline)	-	-	-	-	-	-	-
Immediately After Treatment	3.86 \pm 1.574	3.13 \pm 1.808	0.463	1.29 \pm 1.254	1.13 \pm 0.641	0.779	0.578
3 Days After Treatment	5.00 \pm 1.633	4.38 \pm 2.066	0.779	2.71 \pm 1.254	2.5 \pm 1.852	0.694	0.751
7 Days After Treatment	5.71 \pm 1.799	5.38 \pm 1.302	0.613	3.05 \pm 1.799	4.38 \pm 1.685	0.779	1.00

Table 3. Comparison between mean reduction of pain score between age group

Reduction of Pain Score	LLLT		p-value*	Triamcinolone Acetonide		p-value*	18-22 years old versus 23-27 years old p-value*
	18 – 22 years old	23-27 years old		18 – 22 years old	23-27 years old		
	Mean \pm SD	Mean \pm SD		Mean \pm SD	Mean \pm SD		
Before Treatment (Baseline)	-	-	-	-	-	-	-
Immediately After Treatment	3.25 \pm 0.957	3.55 \pm 1.916	0.463	1.00 \pm 0.816	1.27 \pm 1.009	0.661	0.578
3 Days After Treatment	4.75 \pm 1.500	4.64 \pm 2.014	0.779	2.75 \pm 2.217	2.55 \pm 1.368	0.851	0.751
7 Days After Treatment	5.75 \pm 1.258	5.45 \pm 1.635	0.613	4.75 \pm 1.708	4.45 \pm 1.753	0.753	1.00

*Calculated using Mann Whitney U Test (Sig $p < 0.05$)

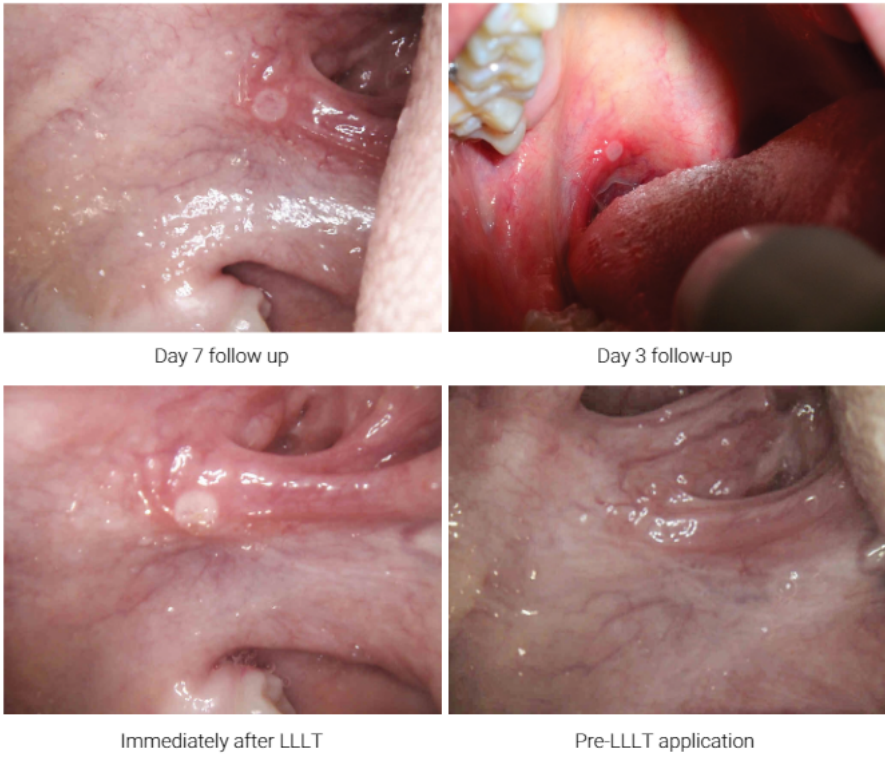

Figure 2. Treatment with LLLT

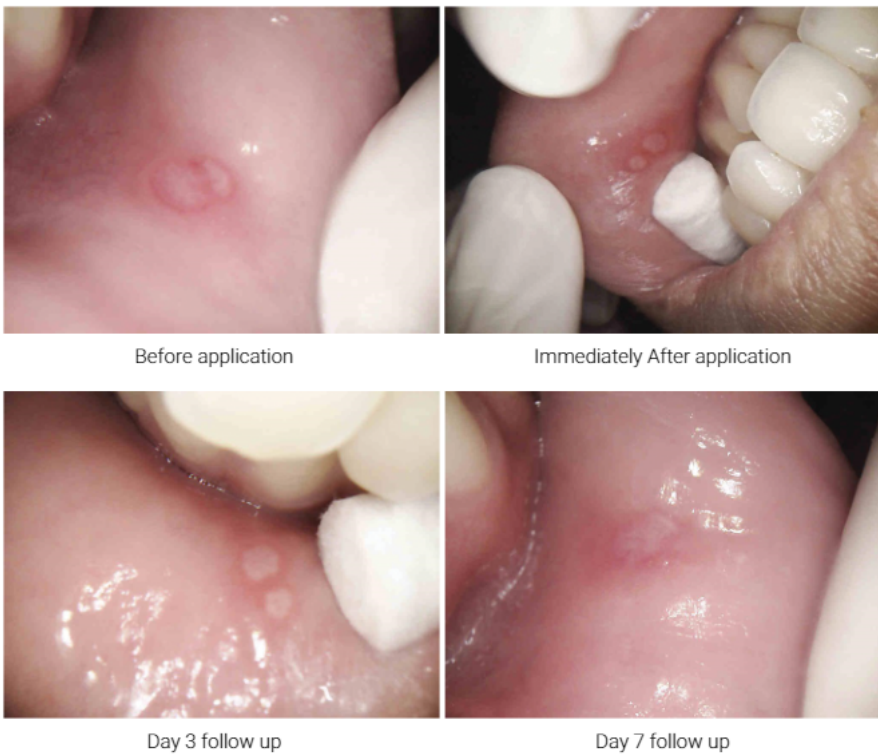

Figure 3. Treatment by Triamcinolone Acetonide 0.1%

DISCUSSION

The present result shows that LLLT is more effective in relieving pain in RAU patients compared to treatment with a topical corticosteroid. Application of LLLT provides significant pain reduction immediately, 3 days, and 7 days after treatment. This finding is in accordance to a controlled study conducted by Aggarwal et al.^{12,14}, which has a mean pain reduction of 4.79 ± 0.86 immediately post-LLLT and 4.72 ± 1.22 on day 3 of follow up. Similar result was reported by Prasad and Pai^{13,15} with the mean pain score in the laser group immediately after treatment (0.68 ± 0.6) compared with pretreatment (8.48 ± 0.71 ; $P < .001$).

However, Sattayut et al.¹⁶ (2013) found that no significant pain relief was observed immediately but only after 3 days of treatment compared to a placebo group. Furthermore, pain reduction in patients treated by Triamcinolone Acetonide 0.1% dental paste was also significant immediately, 3 days, and 7 days after treatment. The latter replicates the result of an randomized controlled trial study conducted by Deshmukh and Bagewadi¹⁷ that showed significant pain reduction from day 0 to 7 after its application. The fact that both treatments significantly reduce pain intensity could suggest both can be a viable treatment option in treating RAU patients.

However, intergroup comparison showed significantly higher pain reduction in patients treated using LLLT compared to Triamcinolone Acetonide 0.1% immediately and on day 3 after the treatment. A comparative study conducted by Deshmukh RA (2014) comparing Nd:YAG laser and Triamcinolone Acetonide 0.1% reported similar findings with significant difference in pain relief on day 1 ($P < 0.05$) and day 4 ($P < 0.05$) after treatment¹⁷. In contrast to another comparative study by De Souza et al.¹⁸ (2010), no statistically significant difference was noted between groups, however 86.60% of the patients treated with laser reported a reduction in pain in the same session ($p = 0.0006$). On day 7 after the treatment, the difference was not significant because the ulcers were most likely healed and there were very little to no pain by the time the patients were asked to rate the pain intensity of the lesion. Since the result of present study shows better pain reduction in RAU patients could be achieved by treatment using LLLT, practicing clinicians may choose LLLT as a positive alternative treatment to conventional topical corticosteroids in treatment of recurrent oral ulceration.

All subjects in this study presented with minor type of RAU. High prevalence of minor type in this study coincides with an epidemiological update in Malaysia by De Souza et al (2010)¹⁸. There was no significant difference in pain reduction observed in patients of different gender and age groups.

Unlike many studies on laser treatment efficacy, Numerical Rating Scale(NRS-11) was used in this study instead of Visual Analogue Scale(VAS) principally to allow ease for follow-up. Since follow up is not possible on the dental chair on certain situations especially on weekends, the use of NRS-11 allows evaluation of patients, pain intensity through phone calls. According to a systematic review by Hjerstad et al.¹⁹ (2011), NRS when compared to VAS and VRS has a higher compliance rate, better responsiveness, ease of use and good applicability.

Triamcinolone Acetonide 0.1% dental paste is a synthetic topical corticosteroid used in the conventional treatment of RAU. It is administered as a pomade in

orabase when the lesion is localized or in rinse format when lesions are diffuse²⁰⁻²³. The emollient paste serves as an adhesive vehicle to deliver the active medication to the oral tissue. It provides a temporary protective layer that isolates the surface of the ulcer from the oral environment thus reducing pain associated with irritation. On cellular level, anti-inflammatory effect of Triamcinolone Acetonide is provided by reduced cellular membrane permeability, impaired lysosomal enzyme release, and inhibition of various chemical mediators released during inflammatory process. It also interferes with the migration of PMNL through the walls of blood capillary in addition to decreased WBC adherence to capillary endothelium. Interference in the normal functioning of lymphocytes and macrophages also contributes to its anti-inflammatory effect.

According to a systematic review by Han et al.¹¹ (2016), the mechanisms of LLLT are still not clearly understood. However, several theories are available at present. Pain relief after laser irradiation may be provided by photobanding, whereby there is formation of a protective layer on the exposed connective tissue of the ulcer²³. The heat generated from the laser helps to seal small blood and lymphatic vessels hence reducing bleeding and edema. The coagulum formed from the laser action which comprises of denatured proteins in the tissues and plasma acts as a wound protection from friction and bacterial invasion. After 48-72 hours of photobanding, the protective layer becomes hydrated, swollen and disintegrates revealing an early healing bed of new tissue²⁴. This layer provides a barrier from the oral environment and reduces pain that derives from inflammatory sensitization of small-diameter afferent nerve endings that form plexus and extend upwards into the epithelial layer. Pain relief is also related to the enhanced ATP synthesis in the mitochondria of the neurons. Increased ATP synthesis causes hyperpolarization which increases the threshold of triggering an action potential thus reducing the induction of pain stimuli²⁵. Furthermore, relief of pain can be associated with the inhibition of interleukin-1Beta and prostaglandin E2 that function to lower the pain receptor threshold if it becomes accumulated²⁶.

With immediate pain relief and faster wound healing, the use of laser greatly enhances patient's satisfaction and gives positive impact in improving the quality of life. To the best of our knowledge, no research has been done in Malaysia to compare the effectiveness of LLLT and Triamcinolone acetonide 0.1% dental paste in treating patients with RAU.

In conclusion, pain from RAU reduces patients' quality of life. Immediate pain relief should be the main goal of any treatment modalities proposed. The results of the present study support the theory that LLLT promotes pain relief. The effectiveness of LLLT in relieving pain in RAU patients may provide clinicians with a positive alternative mode of treatment to reduce chairside time as well as to enhance the quality of dental service to the community. Further studies with different laser parameters should be conducted to establish an ideal protocol for RAU treatment using LLLT. The promising results of present study need to be supported by a larger sample size and comparative studies done using other treatment modalities. Moreover, the fact that Malays were the only race used as samples, future studies could include other races such as Chinese and Indians as well.

REFERENCES

1. Neville BW. Oral & maxillofacial pathology. 2nd ed. Philadelphia: Saunders; 2002.
2. Scully C. Oral and maxillofacial medicine: the basis of diagnosis and treatment 3rd ed. Edinburgh: Churchill Livingstone, Elsevier; 2013. doi: 10.1016/C2011-0-04227-8.
3. Regezi JA. Oral pathology clinical: pathologic correlations. 6rd ed. Saint Louis: Saunders; 2012.
4. Tarakji B, Gazal G, Al-Maweri SA, Azzeghaiby SN, Alaizari N. Guideline for the diagnosis and treatment of recurrent aphthous stomatitis for dental practitioners. *J Int Oral Health*. 2015 May;7(5):74-80.
5. Akintoye SO, Greenberg MS. Recurrent aphthous stomatitis. *Dent Clin North Am*. 2014 Apr;58(2):281-97. doi: 10.1016/j.cden.2013.12.002.
6. Altenburg A, Zouboulis CC. Current concepts in the treatment of recurrent aphthous stomatitis. *Skin Therapy Lett*. 2008 Sep;13(7):1-4.
7. Gross, A. J. & Herrmann, T. R. W. History of lasers. *World J. Urol*. 2007;25: 217–220.
8. Abstracts of the 22nd Congress of the International Association of Paediatric Dentistry. Munich, Germany. June 17-20, 2009. in *International journal of paediatric dentistry / the British Paedodontic Society [and] the International Association of Dentistry for Children* 2009;19 Suppl 1: 1–170.
9. Najeeb S, Khurshid Z, Zohaib S, Najeeb B, Qasim SB, Zafar MS. Management of recurrent aphthous ulcers using low-level lasers: A systematic review. *Medicina (Kaunas)*. 2016;52(5):263-268. doi: 10.1016/j.medici.2016.07.006.
10. Albrektson M, Hedström L, Bergh H. Recurrent aphthous stomatitis and pain management with low-level laser therapy: a randomized controlled trial. *Oral Surg Oral Med Oral Pathol Oral Radiol*. 2014 May;117(5):590-594. doi: 10.1016/j.oooo.2014.01.228.
11. Han M, Fang H, Li QL, Cao Y, Xia R, Zhang ZH. Effectiveness of Laser Therapy in the Management of Recurrent Aphthous Stomatitis: A Systematic Review. *Scientifica (Cairo)*. 2016;2016:9062430. doi: 10.1155/2016/9062430.
12. Aggarwal H, Singh MP, Nahar P, Mathur H, Gv S. Efficacy of low-level laser therapy in treatment of recurrent aphthous ulcers - a sham controlled, split mouth follow up study. *J Clin Diagn Res*. 2014 Feb;8(2):218-21. doi: 10.7860/JCDR/2014/7639.4064.
13. avlič V, vujić-Aleksić V, Aoki A, Nežić L. Treatment of recurrent aphthous stomatitis by laser therapy: A systematic review of the literature. *Vojnosanit Pregl*. 2015 Aug;72(8):722-8.
14. Prasad R S, Pai A. Assessment of immediate pain relief with laser treatment in recurrent aphthous stomatitis. *Oral Surg Oral Med Oral Pathol Oral Radiol*. 2013 Aug;116(2):189-93. doi: 10.1016/j.oooo.2013.02.011.
15. Zand N, Ataie-Fashtami L, Djavaid GE, Fateh M, Alinaghizadeh MR, Fatemi SM, et al. Relieving pain in minor aphthous stomatitis by a single session of non-thermal carbon dioxide laser irradiation. *Lasers Med Sci*. 2009 Jul;24(4):515-20. doi: 10.1007/s10103-008-0555-1.
16. Sattayut S, Trivibulwanich J, Pipithirunkarn N, Danvirutai N. A clinical efficacy of using CO2 laser irradiating to transparent gel on aphthous stomatitis patients. *Laser Ther*. 2013 Dec 30;22(4):283-9. doi: 10.5978/islsm.13-OP-24.
17. Deshmukh RA, Bagewadi AS. Comparison of effectiveness of curcumin with triamcinolone acetonide in the gel form in treatment of minor recurrent aphthous stomatitis: A randomized clinical trial. *Int J Pharm Investig*. 2014 Jul;4(3):138-41. doi: 10.4103/2230-973X.138346.
18. De Souza TO, Martins MA, Bussadori SK, Fernandes KP, Tanji EY, Mesquita-Ferrari RA, et al. Clinical evaluation of low-level laser treatment for recurring aphthous stomatitis. *Photomed Laser Surg*. 2010 Oct;28 Suppl 2:S85-8. doi: 10.1089/pho.2009.2661.

19. Hjerstad MJ, Fayers PM, Haugen DF, Caraceni A, Hanks GW, Loge JH, et al. Studies comparing Numerical Rating Scales, Verbal Rating Scales, and Visual Analogue Scales for assessment of pain intensity in adults: a systematic literature review. *J Pain Symptom Manage*. 2011 Jun;41(6):1073-93. doi: 10.1016/j.jpainsymman.2010.08.016.
20. Quijano D, Rodríguez M. [Topical corticosteroids in recurrent aphthous stomatitis. Systematic review]. *Acta Otorrinolaringol Esp*. 2008 Jun-Jul;59(6):298-307. Spanish.
21. Scully C, Porter S. Oral mucosal disease: recurrent aphthous stomatitis. *Br J Oral Maxillofac Surg*. 2008 Apr;46(3):198-206.
22. Elad S, Epstein JB, von Bültzingslöwen I, Drucker S, Tzach R, Yarom N. Topical immunomodulators for management of oral mucosal conditions, a systematic review; Part II: miscellaneous agents. *Expert Opin Emerg Drugs*. 2011 Mar;16(1):183-202. doi: 10.1517/14728214.2011.528390.
23. Kotlow L. Lasers and soft tissue treatments for the pediatric dental patient. *Alpha Omegan*. 2008 Sep;101(3):140-51.
24. Pirnat, S. Versatility of an 810 nm Diode Laser in Dentistry : an overview. *J Laser Heal. Acad*. 2007(4):1-9.
25. Posten W, Wrone DA, Dover JS, Arndt KA, Silapunt S, Alam M. Low-level laser therapy for wound healing: mechanism and efficacy. *Dermatol Surg*. 2005 Mar;31(3):334-40.
26. Shimizu N, Yamaguchi M, Goseki T, Shibata Y, Takiguchi H, Iwasawa T, Abiko Y. Inhibition of prostaglandin E2 and interleukin 1-beta production by low-power laser irradiation in stretched human periodontal ligament cells. *J Dent Res*. 1995 Jul;74(7):1382-8.