

# MODIFIED WALKING SUTURE TECHNIQUE IN RHYTIDECTOMY IN A SHAR-PEI DOG

## TÉCNICA WALKING SUTURE MODIFICADA NA RITIDECTOMIA EM SHAR-PEI

**Cristiane dos Santos HONSHO<sup>1</sup>; Daniel Kan HONSHO<sup>1</sup>;  
Fernanda Gosuen Gonçalves DIAS<sup>1\*</sup>; Orlando Marcelo MARIANI<sup>1</sup>; Lucas Alves RAMON<sup>1</sup>;  
Nicole Alessandra Luizari STÁBILE<sup>1</sup>; Natacha Alves ALEXANDRE<sup>1</sup>;  
Adriana Torrecilhas JORGE<sup>1</sup>**

1. UNIFRAN – Universidade de Franca, Avenida Dr. Armando Salles de Oliveira, 201, Parque Universitário, CEP 14404-600, Franca - SP, Brazil. \*cristiane.honsho@unifran.edu.br

**ABSTRACT:** Excessive facial skin folds is observed in several breeds of dogs and the weight exerted on the eyelids accents or promotes entropion, trichiasis and ptosis. Thus, this study reported a case of the 8-months-old male Shar-pei weighting 21.5kg was presented with an obstructed visual axis, eye discharge, fetid odor in facial folds around the jaw and the neck. It was indicated the surgical resection of the folds and correction of the upper and lower entropion. In this case, the association of Hotz-Celsus technique with rhytidectomy shaped in semiarchs, using the anchoring points with the modified walking suture, was effective in correcting the entropion and unblocking the visual axis with minimal scarring and preservation of the breed standard in 12 months follow up after surgery.

**KEYWORDS:** Entropion. Ophthalmology. Reconstructive Surgery.

### INTRODUCTION

The Shar-pei dog is characterized by the presence of cutaneous wrinkles on the skull, especially in the frontal, maxillary, lacrimal and zygomatic bone regions, which, together with the racial predisposition to entropion, deserve attention (VIANA et al., 2006; GELATT; GELATT, 2011), since the choice of a surgical technique capable of correcting the various changes at the same time represents a challenge in the breed (STUHR et al., 1997).

The weight of the skin folds on the head, especially on the upper eyelids, forcing them down, sometimes makes it impossible to correct the entropion by the technique of Hotz-Celsus alone, making it necessary a combination of techniques (STUHR et al., 1997; WILLIS et al., 1999; GELATT; GELATT, 2011), as well as the resection of the excess of facial folds, called rhytidectomy, term derived from the Greek *Rhytis* = wrinkles and *ektomé* = excision, also known as facelift (STUHR et al., 1997; MCCALLUM; WELSER, 2004; STEINMETZ, 2015).

Despite the description of techniques for rhytidectomy in dogs, such as the elliptical rhytidectomy in the midline of the craniocaudal head described by Bedford (1990); the stellate technique described by Stuhr et al. (1997); the coronal rhytidectomy associated with the walking suture adopted by McCallum and Welser (2004) and more

recently the bilateral crescent-shape section of skin removal in the supraorbital region associated with shortening of the palpebral fissure (STEINMETZ, 2015), it was noted that none of these techniques would be effective in the present case. Thus, it is presented in this report an association of the mentioned techniques for rhytidectomy, taking advantage of its qualities for the correction of excessive skin folds covering the zygomatic, masseteric and lateral regions of the neck, as well as the supraorbital regions, which included the modified walking suture and walking suture pattern for deep anchorage for closure of the cutaneous wound.

### CASE REPORT

A 8-months-old male Shar-pei weighting 21.5 kg was presented with an obstructed visual axis, eye discharge, fetid odor in facial folds around the jaw and the neck. The dog walked cautiously guiding himself through olfaction.

On ophthalmologic exam, excessive folds in the supraorbital region blocked both eyes on the visual axis (Figure 1A and B). Raising the brow folds, it was observed bilaterally ptosis, upper and lower eyelid entropion, chemosis and seromucous secretion. The Schirmer tear test, in both eyes, exceeded 30 mm/min, pupillary reflexes were normal and the fluorescein eye stain test was negative. After desensitization of the ocular surface with drops of proxymetacaine hydrochloride 0.5%, discrete

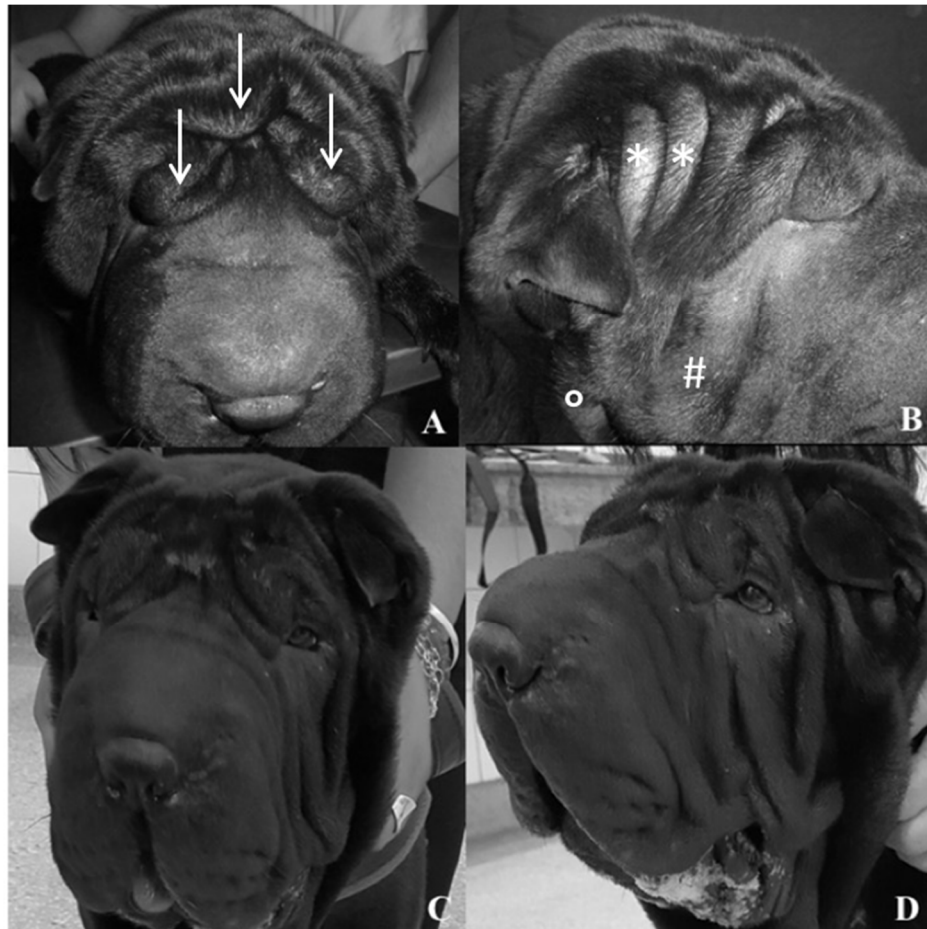lymphoid follicles were noted in the internal structure of the third eyelid.

In general inspection, there was a lot of folds around the trunk and face, especially in cranial regions and skull sides, extending to the zygomatic regions, masseteric and sides of the neck. The latter two featuring intertrigo and fetid odor.

The surgical treatment was indicated for definitive correction of the palpebral alterations and removal of the excess of facial folds as well as the castration. Thus, by means of the surgical indication and the presence of dermatological lesions, topical therapy with 0.1% chlorhexidine digluconate was

instituted ten days prior to surgery at a 12-hour interval, for hygiene of the mandibular folds; ophthalmic cleaning with physiological solution followed by 0.1% dexamethasone eye drops, 0.5% neomycin sulphates and polymyxin B 6000 IU/ml, every 12 hours and 0.002% polyacrylic acid ocular lubricant, at the interval of six hours and, orally, cephalexin (30 mg/kg, every 12 hours) and omeprazole (1 mg/kg, every 24 hours).

The evaluation of the hematimetric indexes and biochemical profile performed in the preoperative period were within the normal range for the species.



**Figure 1.** Photographs of male Shar-pei, cranial view (A) and right lateral (B) of the head, revealing facial folds in supraorbital regions (arrows), zygomatic (\*), masseteric (#) and side of the neck (°), obstructing visual axis. In (C) cranial view, in (D) left side view, 12 months after rhytidectomy in archs and use of modified walking suture.

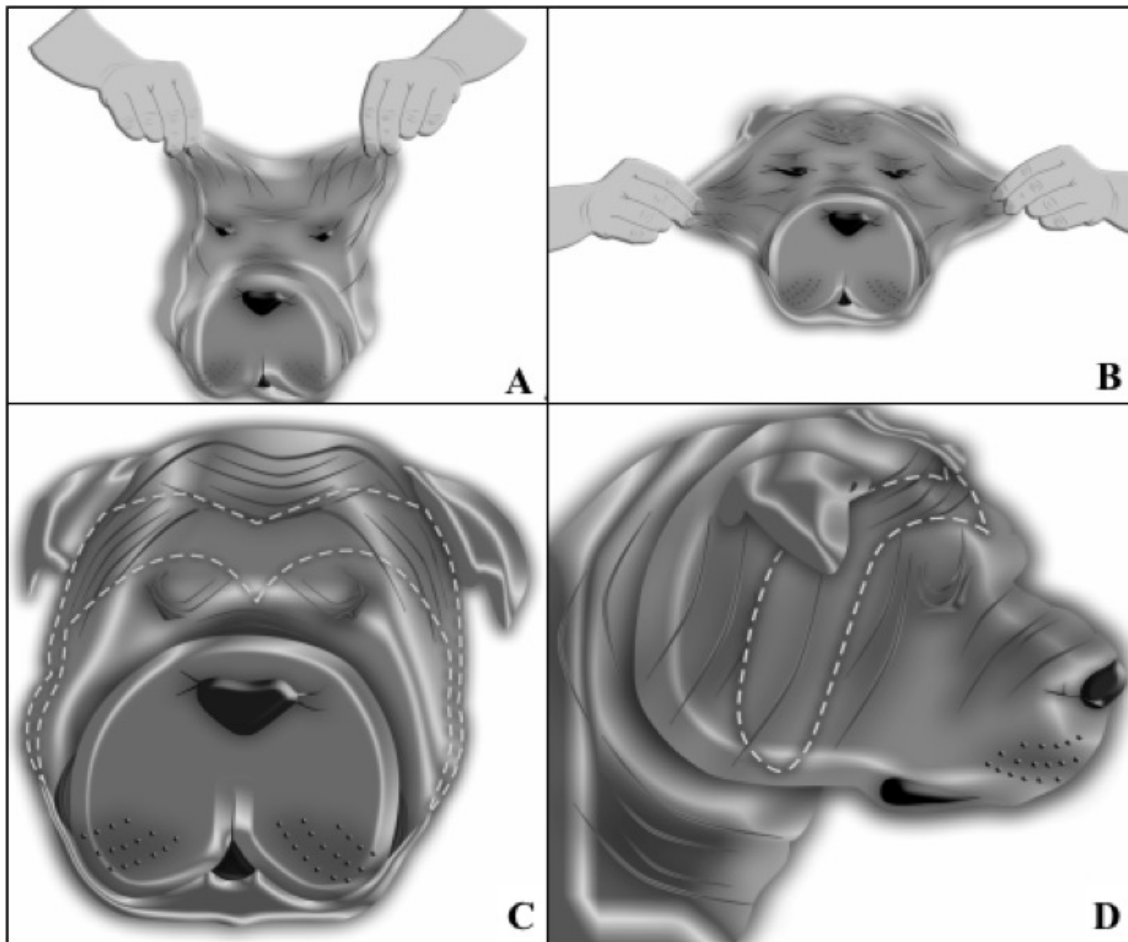
The animal was premedicated with acepromazine (0.03 mg/kg) and methadone (0.3 mg/kg), both intramuscularly. After the tricotomy, there was a decrease on the facial folds due to the muscular hypotonicity caused by premedication.

The shape and area of tissue to be removed were estimated prior to surgery. The skin of the rostral region of the head (Figure 2A) was dorsally

drawn with the fingers until the eyes were visualized and then demarcated with a pen for skin marking (VIANA et al., 2006). As the folds of the lateral head and masseteric regions were overweighted at the lateral commissure of the eyes, shifting the eyelids to the ventral plane, the cheek skin was drawn laterally (Figure 2B) until there was no overweight at the lateral commissure of the eyelids. The area was

demarcated with a specific pen for the skin and considering the midline of the rostral face, two 6,5x30 cm arch-shaped blades were obtained, starting

from the midline of the rostral face of the skull, which would be resected (Figures 2C and 2D).



**Figure 2.** Illustrations of the Shar-pei dog's head showing in (A) the dorsal traction of the skin in the region of the head and in (B) the lateral traction of the skin of the cheeks to determine the amount of tissue to be removed. In (C) cranial view, in (D) right side view evidencing the area of tissue to be removed.

The animal was induced to anesthesia with propofol (3 mg/kg) and midazolam (0.2 mg/kg) intravenously and maintained with isoflurane, in closed system and controlled ventilation.

The entropion was corrected by the technique of Hotz-Celsus (GELATT; GELATT, 2004). The suture was performed with simple interrupted pattern with 4-0 nylon suture. The rhytidectomy was performed and for tissue approximation, sutures were distributed with the modified walking suture pattern, presented by Rodaski et al. (2003) for anchoring the skin to the deepest musculature as indicated by McCallum and Welser (2004). Five sutures were made in the cranial portion and 3 in the caudal portion. The walking suture pattern was adopted with polyglactin 910 3-0 to approximate the subcutaneous in the dorsal region of the head. On the sides of the skull, the subcutaneous was approached with polyglactin 910, 3-0, in two planes of simple

continuous suture, anchored in the lower plane every two sutures. The skin was sutured with nylon 4-0 at simple interrupted sutures.

At the end of the procedure, as immediate analgesia, intravenous dipyrone (25 mg/kg), meloxicam (0.1 mg/kg) and tramadol (3 mg/kg) were administered. Postoperatively, cephalexin and omeprazole were maintained for ten days. Tramadol (3 mg/kg) and dipyrone (25 mg/kg) for five days every eight hours; and meloxicam (0.1 mg/kg) every twenty four hours for four consecutive days. Rifamycin was prescribed four times a day on the surgical wound, after cleansing with saline solution and gauze, until the sutures were removed. The animal was maintained with protective collar until sutures were removed. Returns were made at 5-day intervals and the owner emphasized the significant change in the behaviour of the animal after the surgery, reporting that it moved with extreme agility

and speed due to the recovery of the vision. The sutures were removed with 15 days.

After a year, the animal returned without complications or recurrences, no entropion, ptosis, discomfort, or eye discharge, with minimal scarring and presence of facial folds typical of the breed (Figures 1C and D).

There are several techniques aiming the correction of facial wrinkles and the changes triggered by them. The technique's choice or their associations should be based on racial peculiarities as well as the severities of the case (BEDFORD, 1990; STEINMETZ, 2015). Thus, in this case, because it is evident that the entropion, the ptosis and visual impairment resulted from the excessive folds, the rhytidectomy associated with Hotz-Celsus for entropion correction was chosen.

The stellate rhytidectomy used successfully in a Shar pei by Stuhr et al. (1997) would not be enough to solve the folds on the neck and the weight of the remaining folds would continue to pull the eyelids ventrally. Thus, initially using as a reference the technique used by Stuhr et al. (1997) and including the excision of the excessive skin of the side regions of the head and neck area it was obtained an area similarly to the junction of two semiarcs, which surrounded the supraorbital region promoting its suspension.

Considering the amount of skin removed and the cutaneous mobility area, the standard walking suture was applied to the subcutaneous throughout the cranial region, since this suture permits effective reduction of dead space and facilitates the progressive advance of the skin to the bed of the wound, neutralizing and distributing the tractive

forces along the length of the wound (FOWLER, 1999). However, as done by McCallum and Welser (2004), eight walking suture points, including deep planes, were distributed along the cranial and caudal margins of the wound in order to mitigate the severe tissue mobility with sultan suture. The adopted modified pattern of sultan suture was also reported by Rodaski et al. (2003), to minimize tension and possible ischemia. It was found that this procedure favored the healing process without being observed tissue necrosis, suture dehiscence or infection, commonly reported complications in cases of rhytidectomy (STUHR et al., 1997) or plastic surgeries involving large areas of tissue (FOWLER, 1999).

As noted in previous studies (STUHR et al., 1997; WILLIS et al., 1999) many tutors are reluctant to rhytidectomy, since the proposed techniques remove or modify the breed characteristics, such as the facial folds and promotes significant scarring (BEDFORD, 1990; STUHR et al., 1997). In this case, one year follow up after the surgery, the animal showed minimal scarring and preservation of facial folds typical of the breed.

## CONCLUSION

The association of Hotz-Celsus technique with rhytidectomy shaped in semiarchs, using the anchoring points with the modified walking suture, was effective in correcting the entropion and unblocking the visual axis with minimal scarring and preservation of the breed standard in a 12 months follow up after surgery.

---

**RESUMO:** O excesso de pregas faciais é observado em várias raças de cães e o peso exercido sobre as pálpebras acentua ou promove entrópio, triquíase e ptose. Assim, este estudo relata o caso de Shar-pei, macho de 8 meses de idade, pesando 21,5 kg que apresentava o eixo visual obstruído, secreção ocular e odor fétido nas dobras faciais em torno da mandíbula e do pescoço. Foi indicada a ressecção cirúrgica das pregas e a correção do entrópio superior e inferior. Neste caso, a associação da técnica de Hotz-Celsus com a rítidectomia em forma de semiarcos, utilizando pontos de ancoragem com a técnica "walking suture" modificada, foi efetiva na correção do entrópio e na liberação do eixo visual, com mínima cicatriz e preservação do padrão da raça 12 meses após a cirurgia.

**PALAVRAS-CHAVE:** Entrópio. Cirurgia reconstrutiva. Ophthalmologia.

---

## REFERENCES

BEDFORD, P. G. C. Surgical Correction of Facial Droop in the English Cocker Spaniel. *Journal Small Animal Practice*, v. 31, n. 5, p. 255-258, 1990. May. 2016. <http://doi.org/10.1111/j.1748-5827.1990.tb00799.x>.

FOWLER, D. Tension Relieving Techniques and Local Skin Flaps. In: FOWLER D. & WILLIAMS, J. M.(Ed). **BSAVA Manual of canine and feline wound management and reconstruction**. Cheltenham: BSAVA, [1] p. 57-68, 1999.

GELATT, K. N.; GELATT, J. P. **Veterinary Ophthalmic Surgery**. London: Elsevier. 400p. 2011.  
MCCALLUM, P.; WELSER, J. Coronal rhytidectomy in conjunction with deep plane walking sutures, modified Hotz-Celsus and lateral canthoplasty procedure in a dog with excessive brow droop. **Veterinary Ophthalmology**, v. 7, n. 5, p. 376-379, 2004. May. 2016. <http://doi.org/10.1111/j.1463-5224.2004.04050.x>

RODASKI, S.; WOUK, A. F. P. F.; SOUSA, R. S.; DE NARDI, A. B.; PIEKARZ, C. H.; RIOS, A.; CASTRO, J. H. T. Walking suture modificada para a reconstrução de amplos defeitos de pele após mastectomias em 86 fêmeas caninas. **Revista Científica de Medicina Veterinária - Pequenos Animais e Animais de Estimação - MedVep**, v.14, p.243-248, 2003. May. 2016. <http://medvep1.hospedagemdesites.ws/wp-content/uploads/2015/07/Mv004-01.pdf>

STEINMETZ, A. Shared rhytidectomy continued to lateral canthoplasty in a Mastiff with excessive facial folding and macroblepharon. **Tierärztliche Praxis Kleintiere**, v.43, n.1, p.40-44, 2015. May. 2016. <http://doi.org/15654/TPK-140331>.

STUHR, C. M.; STANZ, K.; MURPHY, C.J. MCANULTY, J. Stellate rhytidectomy: Superior entropion repair in dogs with excessive facial skin. **Journal of the American Animal Hospital Association**, v. 33, n. 4, p. 342-345, 1997. May. 2016. <http://doi.org/10.5326/15473317-33-4-342>

VIANA, F. A. B.; CRONEMBERGER SOBRINHO, S.; BORGES, K. D. A.; FULGÊNCIO, G. D. Aspectos clínicos do entrópio de desenvolvimento em cães da raça Shar Pei. **Arquivo Brasileiro de Medicina Veterinária e Zootecnia**, v. 58, n. 2, p. 184-189, 2006. May. 2016. <http://www.scielo.br/pdf/abmvz/v58n2/29659.pdf>

WILLIS, A. M.; MARTIN, C. L.; STILES, J.; KIRSCHNER, S. E. Brow suspension for treatment of ptosis and entropion in dogs with redundant facial skin folds. **Journal of the American Veterinary Medical Association**, v. 214, n. 5, p. 660-662, 1999. May. 2016. <https://www.ncbi.nlm.nih.gov/pubmed/10088013>