

## DILATED CARDIOMYOPATHY IN BOXER PUPPY OF 8 MONTHS OF AGE: A CASE REPORT

### *CARDIOMIOPATIA DILATADA EM CÃO DA RAÇA BOXER DE 8 MESES DE IDADE: RELATO DE CASO*

**Rosângela de Oliveira ALVES<sup>1</sup>; Andréa Cintra Bastos TORRES<sup>2</sup>;  
Matheus Matioli MANTOVANI<sup>3</sup>; Severiana Cândida de Mendonça Cunha CARNEIRO<sup>4</sup>;  
Luiz Henrique da SILVA<sup>4</sup>; Hugo Cardoso Martins PIRES<sup>5</sup>; Vivian da Costa MARCON<sup>6</sup>;  
Aline Barichello CERQUEIRA<sup>7</sup>**

1. Professora, Doutora, FAMEV, Escola de Veterinária – EV, Universidade Federal de Goiás – UFG, Goiânia, GO, Brasil. [rosangela2210@gmail.com](mailto:rosangela2210@gmail.com); 2. Doutoranda em Ciência Animal, EV – UFG, Goiânia, GO, Brasil. 3. Mestrando em Ciências Veterinárias, Universidade Federal de Lavras, Lavras, MG, Brasil; 4. Médica Veterinária, Hospital Veterinário – HV, Escola de Veterinária – EV – UFG, Goiânia, GO, Brasil; 5. Médico Veterinário Autônomo; 6. Residente em Clínica Médica de Pequenos Animais, Hospital Veterinário – HV, – EV – UFG, Goiânia, GO, Brasil; 7. Fiscal Estadual Agropecuário do Estado de Goiás, Brasil.

**ABSTRACT:** A female Boxer breed dog, at eight months of age, with 8kg, was taken care in the Veterinary Hospital of the Federal University of Goiás with emaciation and breathing difficulty. Cyanotic mucosa, ascites, pulmonary rales, arrhythmias and hypophonesis of heart sounds were observed during clinical examination. Chest X-ray, electrocardiogram and echocardiogram were performed, diagnosing dilated cardiomyopathy. The animal, young enough to manifestation of this disease, was treated and showed a survival of 8 months after the beginning of the treatment.

**KEYWORD:** Heart. Cardiology. Echocardiography. Eletrocardiography.

### INTRODUCTION

Dilated cardiomyopathy (DCM) is the terminology used to designate primary myocardial disorder, characterized by dilation of cardiac chambers, systolic dysfunction, and clinical signs of congestive cardiac insufficiency (TIDHOLM et al., 2001; MARTIN et al., 2009) and the mean incidence age is from four to six years old (WESS et al., 2010).

Its multifactorial and uncertain etiology involves genetic, metabolic, nutritional and toxic factors, besides infectious diseases. Genetic factors are important mainly for those breeds in which there is high incidence or familiar prevalence of the disease, such as Dobermans, Boxers and Cocker Spaniels (MEURS et al., 2012).

The most common transmission pattern is the autosomal dominant, characterized by the appearance of the disease in many generations, equally appearing in both genders. This

transmission pattern is described for the Boxer breed and Doberman Pinscher (PALERMO et al., 2011; O'SULLIVAN et al., 2011).

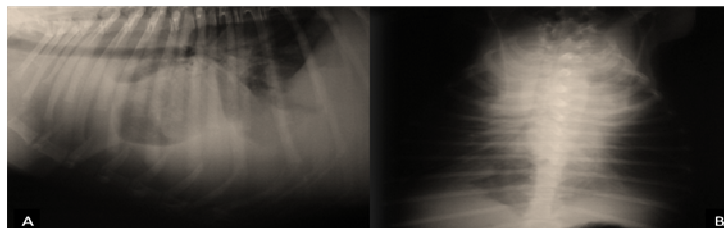
The objective of this report is to demonstrate a case of dilated cardiomyopathy in an eight-month-old Boxer puppy.

### CASE REPORT

An eight-month-old female Boxer, with 8kg, was taken care at the Veterinary Hospital of the Institution. The animal presented a case history of weight loss and breathing difficulty. The animal's parents had sudden death.

Limbs emaciation, cyanotic mucosa, dyspnea, ascites, arrhythmic cardiac auscultation, hypophonesis of heart sounds, and pulmonary crackles were observed during the clinical examination.

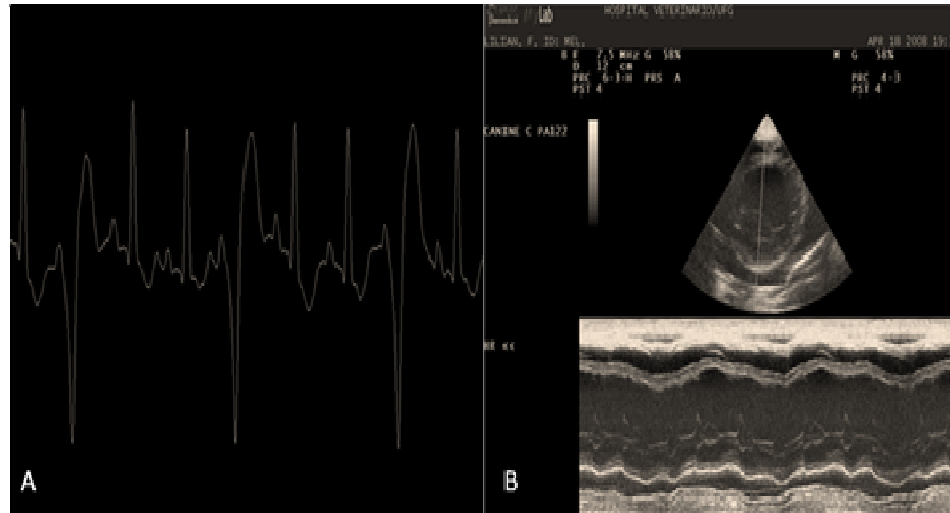
Radiographic examination of thorax showed pleural effusion, pulmonary edema and augmented cardiac silhouette (Figure 1).



**Figure 1.** Chest X-Ray, (A) Latero-lateral and (B) Ventrodorsal view. Observe pleural effusion and pulmonary edema.

Ventricular extrasystoles and increase in QRS duration were observed ECG test (Figure 2). Pericardial effusion, dilated ventricular chambers, increase of left atrium, increase of the left atrium/aorta relation (2.35), decrease of shortening

and ejection fractions (Table 1), besides mild mitral and tricuspid regurgitation due to dilation of mitral valve and tricuspid valve annulus were observed during echocardiography.



**Figure 2.** (A) Computerized electrocardiographic tracing of the patient; derivation II, velocity 50mm/s; presenting ventricular extrasystoles in pattern of bigeminy. (B) Transversal image of left ventricle, M-mode. Observe left ventricle dilation, hypokinesia of the interventricular septum and free wall of left ventricle and pericardial effusion.

**Table 1.** Echocardiographic parameters of M-mode obtained from a Boxer breed dog with dilated cardiomyopathy.

Variable <sup>a</sup>	Values
LVDs (cm)	51.2
LVDd (cm)	55.3
IVSs (cm)	7.8
IVSd (cm)	7.8
PWd (cm)	6.7
PWs (cm)	8.3
EF (%)	16
FS (%)	7
LA/Ao	2.35

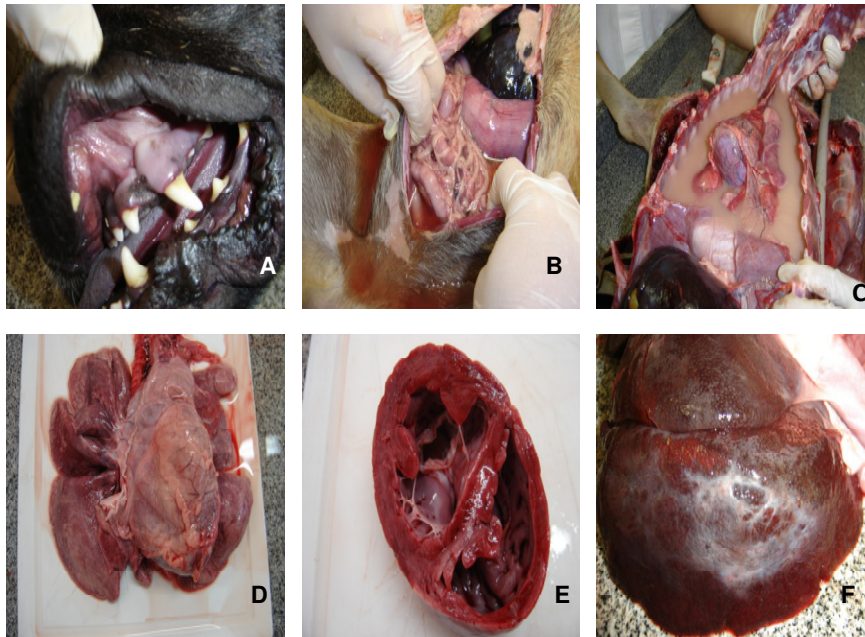
<sup>a</sup>LVSs = left ventricular diameter in systole; LVSD = left ventricular diameter in diastole; IVSs = interventricular septal thickness in systole; IVSd = interventricular septal thickness in diastole; PWd = left ventricular free wall thickness in diastole; PWs = left ventricular free wall thickness in systole; FS = fractional shortening; EF = Ejection fraction; LA/Ao = left atrial/aortic ratio.

Considering all these alterations, the animal was diagnosed with dilated cardiomyopathy, and was submitted to support therapy with furosemide (3mg/kg/q12h), benazepril (0.25mg/kg/q24h), and digoxin (0.005mg/kg/q12h). The ACE inhibitor was replaced by lisinopril (0.25mg/kg/q24h) due to dermatologic sensibility.

Examination was performed monthly for five months, for evaluating the disease evolution and monitoring the prescribed therapy. After this period, the animal presented cardiorespiratory decompensation again and, because of this, spironolactone (1mg/kg/q24h), sotalol

(1mg/kg/q12h), and Royal Canin Cardiac<sup>®</sup> food (70g/three times a day) were added to the treatment. The animal remained stable for other three months and then had sudden death.

Cyanotic mucosa, pleural effusion, ascites, eccentric biventricular dilation, lungs with pneumonic areas, and liver with fibrosis (Figure 3) were the necropsy findings. These alterations are compatible with the diagnosis of dilated cardiomyopathy.



**Figure 3.** Postmortem findings; (A) Cyanotic oral mucosa; (B) Presence of effusion in the abdominal cavity; (C) Presence of effusion in the thoracic cavity; (D) Lungs with pneumonic areas; (E) Biventricular eccentric dilatation; (F) Liver with pale areas (fibrosis).

## DISCUSSION

Based on a suggestive clinical history, breed susceptibility, cardiac signs of congestive cardiac insufficiency, and on complementary examination findings, the diagnosis of idiopathic dilated cardiomyopathy was reached.

Despite a more frequent occurrence in animals within four and ten years old, as described by SISSON (1999), some cases in young animals, as this patient, have been described.

Ventricular extrasystoles observed at the electrocardiographic examination are alterations similar to the ones found in Boxer breed dogs with DCM (YAMAKI et al., 2007).

Cardiac chambers dilation and the increase of the left atrium/aorta proportion, observed at echocardiographic examination, are a consequence of the increase of the heart internal diameters. The reduction of cardiac contractility, verified by the decrease of ejection and shortening fractions, is due to the myofibrillar degeneration and to fibrotic infiltration, which induces electric disorders and difficult the cardiac contraction (SISSON, 1999; LOBO; PEREIRA, 2002).

It is important to emphasize that the premature appearance of this disorder could have

been avoided with the diagnosis of the cardiopathy in the animal's parents, rendering them inapt to reproduction (WESS et al., 2010).

It is important to highlight that this study presented some limitations. Echocardiographic indices measured using the Teichholz method (M mode) may have been underestimated, since this method does not assess the longitudinal direction of the left ventricle (CHETBOUL; TISSIER, 2012). The pimobendan, which is the drug of choice for the treatment of CMD (FUENTES et al., 2002), was not instituted in the treatment protocol due to the financial inability of the pet owner. Failure to perform the ECG Holter monitoring for antiarrhythmic therapy instituted, because of the absence at the time of this equipment in the institution.

## CONCLUSION

Dilated cardiomyopathy is a clinical syndrome that presents high morbidity and mortality rates due to the systolic deficit caused to the patient. Its prognosis is poor considering it is a progressive pathology.

**RESUMO:** Uma cadela da raça Boxer, oito meses, 8kg, foi atendida no Hospital Veterinário da Universidade Federal de Goiás, com emaciação e dificuldade respiratória. Ao exame clínico observou-se mucosas cianóticas, ascite, estertores pulmonares, arritmias e hipofonese das bulhas cardíacas. Realizou-se radiografia de tórax, eletrocardiograma e ecocardiograma, diagnosticando-se cardiomiopatia dilatada. O animal, bastante jovem para manifestação desta enfermidade, foi tratado e obteve uma sobrevida de oito meses após início do tratamento.

**PALAVRAS-CHAVE:** Coração. Cardiologia. Ecocardiograma. Eletrocardiograma.

## REFERENCES

- CHETBOUL, V.; TISSIER, R. Echocardiographic assessment of canine degenerative mitral valve disease. **Journal of Veterinary Cardiology**, London, v. 14, n. 1, p. 127-148, 2012.
- FUENTES, V. F.; CORCORAN, B.; FRENCH, A.; SCHOBBER, K. E.; KLEEMANN, R.; JUSTUS, C. A double-blind, randomized, placebo-controlled study of pimobendan in dogs with dilated cardiomyopathy. **Journal of Veterinary Internal Medicine**, Lawrence, v. 16, n. 3, p. 255-261, 2002
- LOBO, L. L.; PEREIRA, R. Cardiomiopatia dilatada canina. **Revista portuguesa de ciências Veterinárias**, Lisboa, v. 97, n. 544, p. 153-159, 2002.
- MARTIN, M. W. S.; JOHNSON, M. J.; CELONA, B. Canine dilated cardiomyopathy: a retrospective study of signalment, presentation and clinical findings in 369 cases, **Journal of Small Animal Practice**, London, v. 50, n. 1, p. 23-29, 2009.
- MEURS, K.M.; LAHMERS, S.; KEENE, B.W.; WHITE, S.N.; OYAMA, M.A.; MAUCELI, E.; LINDBLAD-TOD, K. A splice site mutation in a gene encoding for PDK4, a mitochondrial protein, is associated with the development of dilated cardiomyopathy in the Doberman pinscher. **Human Genetics**, London, v. 131, n. 8, p. 1319-1325, 2012.
- O'SULLIVAN, M. L.; O'GRADY, M. R.; PYLE, W. G.; DAWSON, J. F. Evaluation of 10 genes encoding cardiac proteins in Doberman Pinschers with dilated cardiomyopathy, **American Journal of Veterinary Research**, Schaumburg, v. 72, n. 7, p. 932-939, 2011.
- PALERMO, V.; STAFFORD JOHNSON, M.J.; SALA, E. BRAMBILLA, P. G.; MARTIN, M. W.; Cardiomyopathy in Boxer dogs: A retrospective study of the clinical presentation, diagnostic findings and survival. **Journal of Veterinary Cardiology**, London, v. 13, n. 1, p. 45-55, 2011.
- SISSON, D. Myocardial diseases of dog. In: \_\_\_\_\_ **Textbook of canine and feline cardiology: Principles and clinical practice**, Philadelphia:Saunders, 1999. p. 581-620.
- TIDHOLM, A.; HAGGSTROM, J.; BORGARELLI, M.; TARDUCCI, A. Canine idiopathic dilated cardiomyopathy. Part I: Aetiology, clinical characteristics, epidemiology and pathology. **The Veterinary Journal**, Londres, v. 162, n. 2, p. 92-107, 2001.
- WESS, G.; SCHULZE, A.; BUTZ, V.; SIMAK, J.; KILLICH, M.; KELLER, L.J.; MAEURER, J.; HARTMANN, K. Prevalence of dilated cardiomyopathy in Doberman Pinschers in various age groups. **Journal of Veterinary Internal Medicine**, Lawrence, v. 24, n. 3, p. 533-538, 2010.
- YAMAKI, F. L.; SOARES, E. C.; PEREIRA, G. G.; OLIVEIRA, V. M. C.; LARSSON, M. H. M. A. Monitorização eletrocardiográfica ambulatorial por 24-horas em cães com cardiomiopatia dilatada idiopática. **Arquivo Brasileiro de Medicina Veterinária e Zootecnia**, Belo Horizonte, v. 59, n. 6, p. 1417-1424, 2007.