

Effect of *Annona muricata* L. Leaf Ethanol Extract in CCl₄ Hepatitis Rat Model

Kuswinarti,¹ Ilham Asrori Azka,² Dwi Prasetyo³

¹Departement of Biomedical Sciences Faculty of Medicine Universitas Padjadjaran, Indonesia, ²Faculty of Medicine Universitas Padjadjaran, Indonesia, ³Departement of Child Health Faculty of Medicine Universitas Padjadjaran/Dr. Hasan Sadikin General Hospital, Bandung, Indonesia

Abstract

Background: Liver can be damaged by various factors, including the oxidative stress mechanism. This damage can be inhibited by the application of anti-oxidant. The *Annona muricata* L. leaf is known to have antioxidant properties. This study aimed to explore the effect of *Annona muricata* L. leaf extract against hepatitis in rats.

Methods: An experimental study was performed on 25 male Wistar rats that were given *Annona muricata* L. leaf ethanol extract at 200 mg/kgBW, 400 mg/kgBW, and 600 mg/kgBW for eight days. The CCl₄ was administrated on the eighth day and the rats were laparotomized on the next day. The average number of normal hepatocytes was counted in one field of view. This study was conducted at the laboratory of Pharmacology and Therapy of the Faculty of Medicine, Universitas Padjadjaran in September–October 2012.

Results: The negative control group showed an intact cell membrane, homogenous cytoplasm, and round nucleus, whereas the positive control group showed necrosis marked by a ruptured cell membrane, vacuolated cytoplasm, and degenerated nucleus. The average number of normal hepatocytes counted in the negative control and the positive group was 404.91±34.09 cells and 23.16±7.84 cells, respectively. In the treatment group, the normal hepatocytes were 95.91±20.96 cells (200 mg/kgBW), 74.53±13.59 cells (400 mg/kgBW) and 46.84±8.46 cells (600 mg/kgBW). Statistically significant inhibition was observed (p<0.05).

Conclusions: The *Annona muricata* L. leaf ethanol extract can inhibit liver tissue damages in hepatitis model rats, possibly due to the presence of acetogenins as an anti-oxidant agent.

Keywords: *Annona muricata* L. leaf ethanol extract, CCl₄, hepatocyte

Introduction

Hepatitis is an infection or inflammation disease of the liver which is caused by toxic chemical substances, such as carbon tetrachloride (CCl₄).^{1,2} This compound has been frequently used for experimental studies to observe liver damage. The hepatotoxic effect of CCl₄ is a result of an oxidative stress process, that to some extent caused by the partial pressure of reactive oxygen in tissues. In CCl₄ induced liver injury model, oxidative stress can provoke and promote lipid peroxidation that damage the hepatocellular membrane, followed by the release of pro-inflammatory chemokines and cytokines.^{3,4} This process introduces an imbalance to the effect of

radicals outnumbering anti-oxidants.⁵ Because of its very reactive nature, free radicals tend to accrue electrons from other substances to reach stability. This chain reaction will eventually produce damages in the cellular structures such as the membranes, structural proteins, enzymes, as well as nucleic acid.⁶

Annona muricata L. leaf contains the phytochemical compound acetogenins. The presence of this compound in *Annona muricata* L. leaf has an anti-oxidant activity which may prevent the damages caused by free radicals on cells.⁷ Free radicals or reactive oxygen species (ROS) play an important role in oxidative stress and pathophysiology of various diseases, including liver disease and other functional disorders.^{8,9} The most damaging to biological

Correspondence: Kuswinarti, Departement of Biomedical Sciences Faculty of Medicine, Universitas Padjadjaran, Jalan Raya Bandung Sumedang Km. 21 Jatinangor, Sumedang, Indonesia, E-mail: wiwinsumarlan@gmail.com

systems are the reactive oxygen species (ROS), in which of importance are superoxide ($\cdot\text{O}_2^-$), hydroxyl ($\cdot\text{OH}$), and per hydroxyl ($\cdot\text{O}_2\text{H}$). Tissue damage caused by ROS is dubbed as oxidative damage and the factors which can prevent this are referred to as anti-oxidant.^{6,10}

Carbon tetrachloride is well absorbed in the digestive tract and respiratory tract of humans and animals. In liquid form, carbon tetrachloride can be absorbed via the skin, but in vapor form, its dermatological absorption is slow. Carbon tetrachloride is well distributed throughout the body with higher concentrations in the liver, brain, kidneys, muscles, fat, and blood. Its main excretion is through respiration as well as through feces and urine.¹¹

After absorption, carbon tetrachloride is metabolized by cytochrome enzyme p450 inside the smooth endoplasmic reticulum of the hepatocytes. Carbon tetrachloride is then cleaved to become trichloromethyl (CCl_3) which is a very reactive free radical ($\text{CCl}_3 + e^- \rightarrow \text{CCl}_3 + \text{Cl}^-$). Trichloromethyl can cause the formation of lipid radicals by oxidizing fatty acids contained within the phospholipid membrane. A peroxidation of lipid can occur if this lipid radical reacts with oxygen. This is an autocatalytic reaction and can, thus, cause a chain reaction. The effect of such a reaction is the damage to the structural integrity of and disturbance upon the functioning of the hepatocytes. If the damage progresses and irreversible, that will induce hepatocyte cell death.¹²

Annona muricata L. leaf is extensively used as an anti-oxidant. Furthermore, it has also been used to reduce blood sugar in diabetic patients, as anti-nociceptive, and anti-inflammation.¹³⁻¹⁵

Acetogenins are found in the family *Annonaceae*. *Acetogenins* consist of C_{35} – C_{39} carbon and have 2 hydrocarbon chains that connects the 2,4-disubstituted- γ -lactone group to variants of the tetrahydrofuran (THF) ring. The hydrocarbon chain of this compound contains oxygenating groups such as *hydroxyls*, *acetoxy*s, and/or *ketones*.¹⁶

The study aimed to explore the effect of *Annona muricata* L. leaf ethanol extract on the inhibition of liver tissue damage on hepatitis model rats.

Methods

The design of this study was an experimental study, involving 25 male rats of Wistar strain induced by the hepatotoxic material

CCl_4 were used as hepatitis model rats. The administration of CCl_4 had damaged the liver, marked by degenerative changes such as necrosis and hepatocyte swelling, and vacuole formation inside the cells. The damage was observed on the liver of the experimental rats after the induction of CCl_4 intraperitoneally.¹⁷

The Wistar rats aged 2–3 months, weight 200–250 gram each were included, and those with weight loss of more than 10% during adaption were excluded. The rats were divided into 5 groups, which were: negative control (no treatment nor induction), positive control (no treatment but with induction of CCl_4), group treated with *Annona muricata* L. leaf ethanol extract (AMEE) at 200 mg/kgBW, 400 mg/kgBW, 600 mg/kgBW.

In brief, a simplicia of *Annona muricata* L. leaf was made, which was then reduced into grains. The grains were then macerated for 3x24 hours with 95% ethanol. The *Annona muricata* L. leaf ethanol extract was then intensified with a rotary evaporator at 70°C until a viscous liquid extract was formed.

The *Annona muricata* L. leaf ethanol extract was then administered for eight days. The CCl_4 was applied on the eight-day, and on the next day, the rats were laparotomised. The histological preparation was performed using the Hematoxylin-Eosin staining method and observed on 400x magnification for qualitative observation.

Quantitatively, the average number of normal hepatocytes was counted in one field of view. Each group consisted of 5 rats. Preparations were made for each rat and viewed the normal hepatocyte cells in one field of view 15 times. Then averages of the result were counted. The average number of normal hepatocyte data in one field of view of preparation was statistically analyzed by one-way Analysis of Variance (ANOVA) test and followed by Tukey post hoc test. The result of $p < 0.05$ indicated statistical significance.

Results

The effect of *Annona muricata* L. leaf ethanol extract was qualitatively observed by histopathological images as shown in Figure 1.

Microscopical examination in the negative control group showed normal liver tissue. Hepatocytes have a round complete nucleus, homogenous unvacuolated cytoplasm, and intact cell membrane. Hepatocytes were orderly arranged around vena centralis.

The administration of CCl_4 in the group of positive control showed clear tissue necrosis

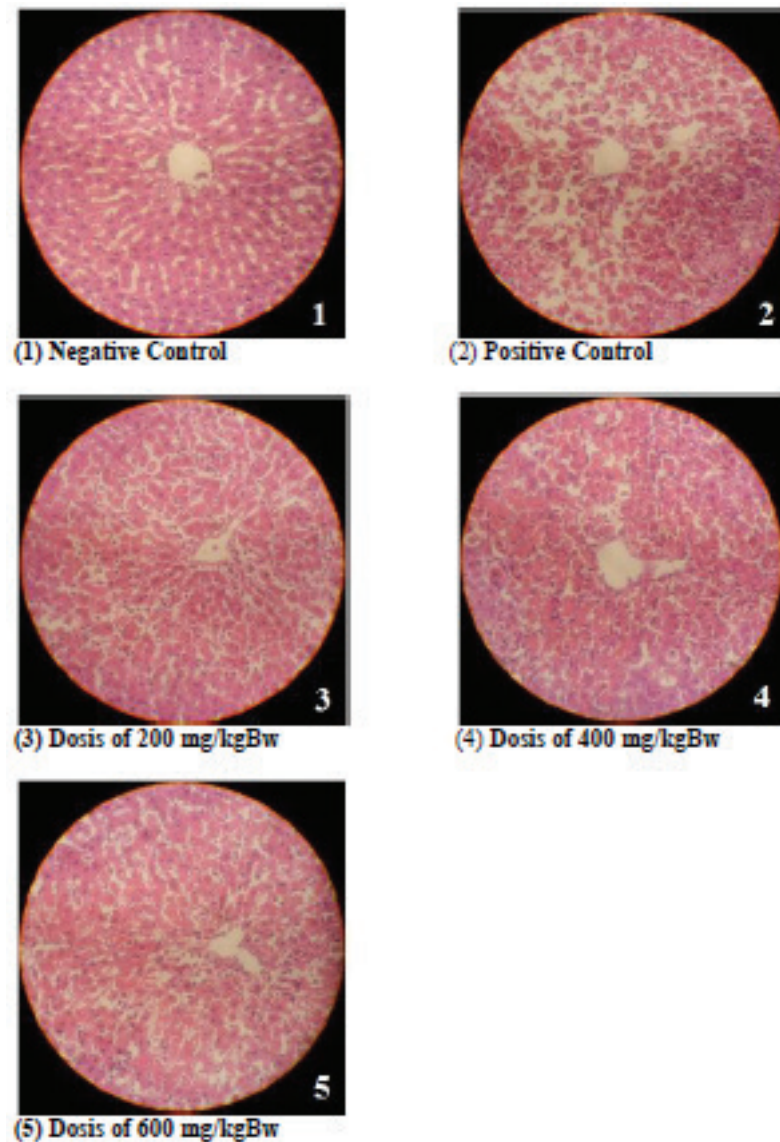


Figure 1 Effect of *Annona muricata* L. leaf Ethanol Extract Observed by Histopathological Images (Hematoxylin-Eosin staining; 400× magnification)

especially in the area surrounding vena centralis (centrilobular necrosis). On the intact hepatocytes, vacuolated cytoplasm was present (ballooning degeneration). On other hepatocytes, ruptured cell membranes were found. These conditions showed a disorganized structure of hepatic lobules.

Microscopic examination in groups treated with 200 mg/kgBW, 400 mg/kgBW, and 600 mg/kgBW of AMEE showed that some hepatocytes had necrosis with the ruptured cell membrane. The morphology of the normal hepatocytes in treated with 200 mg/kgBW AMEE group was not as clearly defined as in

the negative control group and the structure of hepatic lobules was seen as in a more orderly nature compared to the positive control group. The morphology of normal hepatocytes in the 400 mg/kgBW AMEE group was not as clearly distinct as in the negative control group and the structure of hepatic lobules was in a more disorderly manner compared to the 200 mg/kgBW AMEE group. The morphology of normal hepatocytes in the 600 mg/kgBW AMEE group was not clear as in the negative control group and the structure of hepatic lobules had virtually lost any presence of orderliness.

The group with the most amounts of

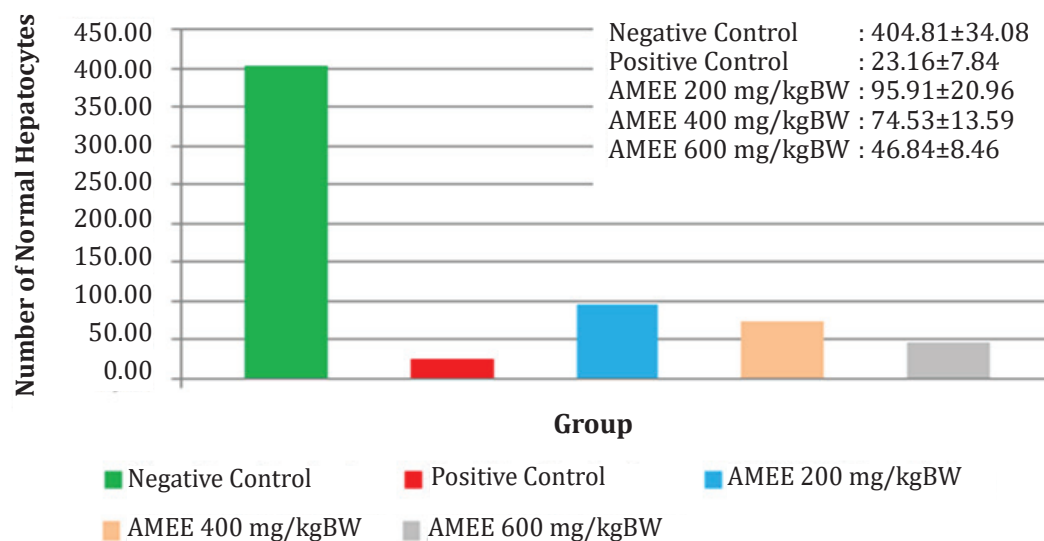


Figure 2 Average Number of Normal Hepatocytes in One Field of View

normal hepatocytes was the negative control group which was 404.91 ± 34.09 cells. The AMEE 200 mg/kgBW group had average normal hepatocytes of 95.91 ± 20.96 cells; AMEE 400 mg/kgBW group with 74.53 ± 13.59 cells; and AMEE 600 mg/kgBW group with 46.84 ± 8.46 cells. The positive control group had 23.16 ± 7.84 cells normal hepatocytes. The number of hepatocyte normal cells in the negative control group compared to the positive control group was statistically significant ($p < 0.05$), showing the success of CCl_4 induction in damaging liver cells. On the treated groups, there was an inhibition of the damage on the rats' liver by retaining more normal cells which was deemed as statistically significant ($p < 0.05$).

Discussion

Acetogenins is a phytochemical compound in *Annona muricata* L. leaf that has an antioxidant activity which might prevent the damage of the liver caused by free radicals or reactive oxygen species (ROS) on cells. ROS plays an important role in oxidative stress caused by CCl_4 . In the negative control group, normal liver tissue has been observed. In the positive control group, there is extensive damage to the rats' liver tissue. Histopathological conditions of rats' liver show that 24 hours after CCl_4 induction, apoptosis has been found in the hepatocytes of the centrilobular region with characteristics of chromatin condensation of the nucleus and ballooning of the cytoplasm.¹⁷

On the treatment groups which are the 200 mg/kgBW, 400 mg/kgBW, and 600 mg/kgBW of AMEE groups, the rats' liver preparations show better results compared to the positive control group. *Annona muricata* L. leaf has been found to have an anti-oxidant effect of the *acetogenins*,⁷ that may prevent the occurrence of subsequent bonds between the free radical and the membrane which then halted the peroxidation of the membrane, resulting in a lower rate of necrosis. As such liver damage by induction CCl_4 can be inhibited by prior administration of *Annona muricata* L. leaf ethanol extract.

On the 400 mg/kgBW and 600 mg/kgBW AMEE groups, normal cell numbers are less compared to the 200 mg/kgBW AMEE group. This shows that the dosage of 200 mg/kgBW of AMEE while being the lowest, is the most potent to prevent liver tissue damage. These results are in agreement with another research that a low dosage of aqueous extract of 50 mg/kgBW gives greater protection compared to a higher dosage against CCl_4 ,¹⁸ possibly because of maximum biological tolerance of the rats' body.¹⁹ The effect of chemical compound overload at high dosage can cause adverse effects and as such the smaller dosage can be deemed as more effective.²⁰

To conclude, the *Annona muricata* L. leaf ethanol extract can inhibit liver damage in hepatitis model rats, possibly due to the presence of acetogenins role as an anti-oxidant.

References

1. Ghany M, Hoofnagle JH. Approach to the patient with liver disease. In: Kasper D, Braunwald E, Fauci AS, Hauser SL, Longo DL, Jameson JL, editors. Harrison's principles of internal medicine. 16th ed. New York: McGraw-Hill; 2004. p. 1808–13.
2. Tanaya G, Kuswinarti K, Dewi NS. *Annona muricata* Linn Leaf Effect in inhibiting SGPT Elevation. Althea Medical Journal. 2015;2(1):86–9
3. Dutta S, Chakraborty AK, Dey P, Kar P, Guha P, Sen S, et al. Amelioration of CCl₄ induced liver injury in swiss albino mice by antioxidant rich leaf extract of *Croton bonplandianus* Baill. PLoS One. 2018;13(4):e0196411
4. Feng Y, Wang N, Ye X, Li H, Feng Y, Cheung F, et al. Hepatoprotective effect and its possible mechanism of *Coptidis* rhizome aqueous extract on carbon tetrachloride induced chronic liver hepatotoxicity in rats. J Ethnopharmacol. 2011;138(3):683–90
5. Kamel HH, Azza H, Walaa MSA, Mohamed AH. Protective effect of some antioxidants against CCl₄-induced toxicity in liver cells from BRL3A cell line. Journal of American Science. 2010;6(10):992–1003.
6. Murray RK, Bender DA, Botham KM, Kenelly PJ, Rodwell VW, Weil PA. Harper's illustrated biochemistry. 28th ed. New York: McGraw-Hill Medical; 2009.
7. Baskar R, Rajeswari V, Kumar TS. In vitro antioxidant studies in leaves of *Annona* species. Indian J Exp Biol. 2007;45(5):480–5.
8. Lestari CR, Sumarawati T, Nasihun T. The effect of CMCE propolis extract administration on interleukin-1(IL-1) levels and the hepatocyte histopathological findings of rats induced with CCl₄. Sains Medika. 2020;11(1):7–13
9. Maulina M. Pengaruh pemberian xanthone terhadap gambaran nekrosis sel hepar tikus putih (*rattus norvegicus*) jantan yang diinduksi karbon tetraklorida (CCl₄). SEL. 2015;2(1):10–21
10. Krismayogi GA, Ratnayanti IGAD, Linawati NM, Wiryawan IGNS, Sugiritama IW, Wahyuniari IAI, et al. Purple cabbage extract cream effect on erythema score of male wistar rats back skin exposed to UV-B radiation. Biomedical and Pharmacological Journal 2018;11(1):343–51
11. World Health Organization, International Programme on Chemical Safety. Carbon tetrachloride: health and safety guide. Geneva: World Health Organization; 1998.
12. Crawford JM. Cellular adaptation, cell injury, and cell death. In: Kumar V, Abbas AK, Fausto N, editors. Robbins and Cotran pathologic basis of disease. 7th ed. Philadelphia: Saunders; 2004. p. 3–46.
13. Adewole S, Caxton-Martins E. Morphological changes and hypoglycemic effects of *Annona muricata* Linn. (*Annonaceae*) leaf aqueous extract on pancreatic β -cells of streptozotocin-treated diabetic rats. Afr J Biomed Res. 2006;9:173–87.
14. DeSousa OV, Vieira GD, de Pinho JdRG, Yamamoto CH, Alves MS. Antinociceptive and anti-inflammatory activities of the ethanol extract of *Annona muricata* L. leaves in animal models. Int J Mol Sci. 2010;11(5):2067–78.
15. Kuswinarti K, Savira K, Rudiman R. The analgesic effect of ethanol extract Soursop (*Annona muricata* L.) leaves in wistar rats. Althea Medical Journal. 2018;5(4):196–200
16. Fang XP, Rieser MJ, Gu ZM, Zhao GX, McLaughlin JL. *Annonaceous acetogenins*: An updated review. Phytochemical Analysis. 1993;4(1):27–48.
17. Shi J, Aisaki K, Ikawa Y, Wake K. Evidence of hepatocyte apoptosis in rat liver after the administration of carbon tetrachloride. Am J Pathol. 1998;153(2):515–25.
18. Arthur FKN, Woode E, Terlabi EO, Larbie C. Evaluation of hepatoprotective effect of aqueous extract of *Annona muricata* (Linn.) leaf against carbon tetrachloride and acetaminophen-induced liver damage. J Nat Pharm. 2012;3(1):25–30.
19. Cone M. Low doses of hormonelike chemicals may have big effects: Scientists seek 'fundamental changes' in testing and regulation of chemicals that mimic human hormone. Environmental Health News; 2012 [Cited 2020 December 10]; Available from: <https://www.scientificamerican.com/article/low-doses-hormone-like-chemicals-may-have-big-effects/>.
20. The Society of Toxicology. Animals in research: the importance of animals in the science of Toxicology. Reston: The Society of Toxicology; 2006 [Cited 2020 December 10]; Available at: https://www.toxicology.org/pubs/docs/air/AIR_Final.pdf.