

GRAIN OVERLOAD AND SECONDARY EFFECTS AS POTENTIAL MORTALITY FACTORS OF MOOSE IN NORTH DAKOTA

Erika A. Butler¹, William F. Jensen¹, Roger E. Johnson², and Jason M. Scott³

¹North Dakota Game and Fish Department, 100 North Bismarck Expressway, Bismarck, ND, United States 58501; ²North Dakota Game and Fish Department, 7928 45th Street NE, Devils Lake, ND, United States 58301; ³North Dakota Game and Fish Department, 2305 Elm Street, Fargo, ND, United States 58102

ABSTRACT: The intent of this article is to alert biologists of a potential mortality factor of moose in agricultural areas. It has long been recognized that ruminants switching from a natural diet of browse (a cellulose-based diet) to one of more readily digestible carbohydrates (a starch-based diet), such as corn and wheat, are predisposed to developing conditions such as enterotoxemia, polioencephalomalacia, acute rumenitis, liver abscesses, laminitis, and to sudden death. These are often secondary to grain overload (acute acidosis) and are frequently documented in cattle and sheep which are moved from pasture to feedlot. Necropsies of 4 moose in North Dakota were not entirely conclusive, but suggested that grain overload occurred and was a cause of mortality. Necropsy findings that supported grain overload as a contributing factor to death included acute rumenitis, isolation of *Clostridium perfringens* coupled with hemorrhagic enteritis, chronic laminitis, and polioencephalomalacia. Four likely scenarios exist in which grain overload occurs in North Dakota moose including consumption of planted crops such as corn and wheat, access to bait piles mainly intended for deer, access to cattle feeding sites, and access to recreational feeding sites. These findings have important implications for the regulation of baiting and recreational feeding practices in North Dakota and elsewhere in moose range of similar situation.

ALCES VOL. 44: 73-79 (2008)

Key words: Agriculture, *Alces alces*, feeding, grain overload, moose, mortality, rumenitis.

Moose (*Alces alces*) in North Dakota have traditionally occupied forested areas in the northeast and north-central portions of the state. Moose were first recorded during white-tailed deer (*Odocoileus virginianus*) surveys in the winter of 1969-70. In 1979 the first modern moose hunting season allowed the harvest of 15 moose in Cavalier, Pembina, and Walsh counties. Recently, based upon winter aerial survey data for white-tailed deer, moose have expanded their range south and west into agricultural areas. Areas of the state open to moose hunting include the eastern one-third of the state south to the South Dakota border, and much of the northern one-third of the state. In 2008, 141 moose licenses were issued in North Dakota.

The Red River valley (Glacial Lake Agassiz Plain) was historically tall grass prairie.

Due to the high productivity of the soil, flat terrain, and ease of conversion to agricultural use, <2% of the surface area remains as native prairie (Jensen 2001). Common crops in these areas include corn, wheat, sugar beets, potatoes, barley, beans, sunflowers, and soybeans (Fig. 1). Reports of moose feeding in these agricultural fields, both planted and plowed, have become increasingly common over time.

Long recognized as a concern with domestic ruminants, grain overload (i.e., rumen overload, carbohydrate overload, acute overeating, ruminal acidosis) results from ingestion of toxic amounts of highly fermentable and readily digestible carbohydrates such as grain. This frequently occurs when ruminants abruptly switch from a diet of natural browse (a cellulose-based diet) to

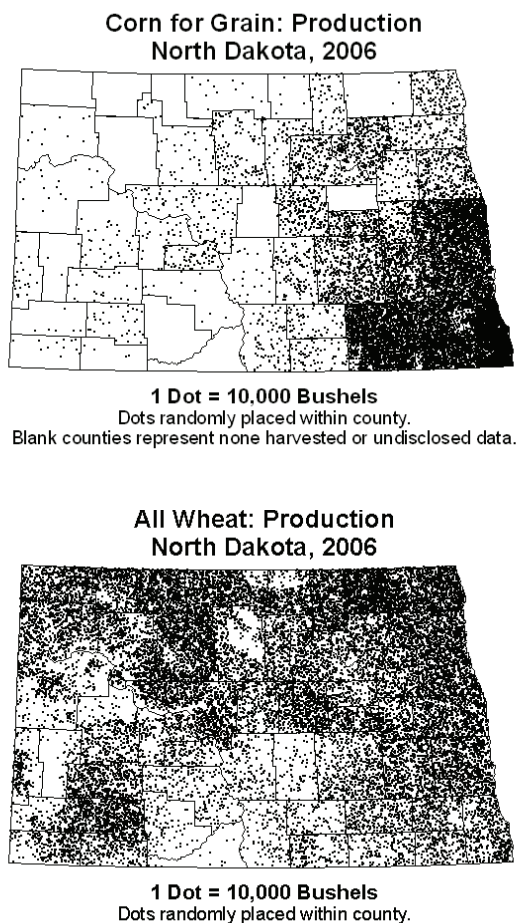


Fig. 1. Corn and wheat production throughout the state of North Dakota. Compiled and published by the USDA, National Agricultural Statistics Service, North Dakota Field Office (Source: http://www.nass.usda.gov/Statistics_by_State/North_Dakota/index.asp).

one of readily digestible carbohydrates (a starch-based diet) causing a change in the rumen microbial population; the number of gram positive bacteria increase markedly while gram negative bacteria decline. The gram positive bacteria produce excessive lactic acid which lowers the rumen pH to <5. This increase in acidity destroys protozoa, cellulolytic organisms, and lactate-utilizing organisms all of which normally inhabit the rumen, and impairs rumen motility. Clinical signs of acute overload include indigestion, rumen stasis, acute ruminitis and acidosis,

dehydration, toxemia, incoordination, collapse and recumbancy, and frequently death. If the animal survives the initial episode of grain overload, secondary effects include, but are not limited to, enterotoxemia, polioencephalomalacia, liver abscesses, and chronic laminitis (Merck Veterinary Manual 2008). However, other potential causes for these conditions also exist and are presented in the discussion.

Ruminitis and rumen scarring have been reported in a supplementary fed captive deer herd (Woolf and Kradel 1977) and grain overload has been identified as a primary diagnosis in captive elk (*Cervus elaphus*) of all ages submitted to pathology labs (Woodbury et al. 2005). Ruminitis was diagnosed in 30 of 108 free-ranging white-tailed deer examined in Saskatchewan; rumenitis and rumen overload were determined to be the causes of death of 5 of these deer (Wobeser and Runge 1975). A polioencephalomalacia-like disease, possibly secondary to grain overload, has been reported in wild pronghorn (*Antilocapra americana*) from Saskatchewan (Wobeser et al. 1983) and North Dakota (W. Jensen, North Dakota Game and Fish Department, pers. comm.), wild white-tailed deer in Minnesota (Kurtz and Karns 1969) and South Dakota (Reed et al. 1976), and a wild mule deer (*Odocoileus hemionus*) from South Dakota (Reed et al. 1976). No documentation of grain overload in moose was found, though moose might be especially vulnerable to this condition as their mean retention time for digestion is the longest documented for cervids, and is surpassed by only 1 member of the order Artiodactyla, the Asian water buffalo (*Bubalus bubalis*; Stevens 1998).

METHODS

Reports of dead or sick moose throughout the state are generally investigated by the North Dakota Game and Fish Department (NDGF) wardens or biologists. When possible, either the entire carcass is submitted to the North

Dakota State University Veterinary Diagnostic Laboratory (VDL) for necropsy, or samples of major organs and serum are collected for submission. This study is a retrospective review of necropsy reports during a period of time when the NDGF did not have a veterinarian on staff. The results of 4 necropsies performed from 1991-2006 suggested that grain overload and its secondary effects could have contributed to moose mortality in North Dakota.

Each of the 4 cases discussed below had the entire carcass delivered to the VDL for necropsy. Grain overload was not considered a differential diagnosis by NDGF employees until results of the necropsies were received. Consequently, some pertinent information is lacking, and/or difficult to interpret from the available necropsy reports. Further, the VDL may have believed that certain animals were from captive facilities.

RESULTS

The locations of the 4 moose mortalities were in areas of substantial corn and wheat production (Fig. 1 and 2). All 4 cases died or exhibited clinical signs during the North Dakota deer archery season which runs from September–January. Case C was euthanized during the deer gun season which occurs for 17 days in November. No hunting-related injuries were documented in any case.

In October 1991 the NDGF received multiple calls regarding case A, an adult cow moose east of Sheldon. Reports indicated that case A had extremely overgrown hooves (both the fore and hind limbs). On 21 October it was decided to euthanize case A as her travel had become extremely restricted. Case A was in good body condition and was presented at necropsy with moderate postmortem change. It was noted that all 4 digits had severely overgrown claws. The hind and front claws were approximately 30 cm and 20 cm longer than normal, respectively. Separation of the dorsal claw from the third phalanx was evident and proliferation of fibrous tissue was present.

Severe congestion was noted around the distal aspects of the third phalanx in both front digits. The rumen and reticulum contained large amounts of grain that appeared to be corn. Hyperemia of the ruminal mucosa was noted. Serology for both bluetongue and epizootic hemorrhagic disease virus was negative. A diagnosis of severe, chronic laminitis in all 4 feet was made. The pathologist commented that this lesion in domestic livestock is often associated with an episode of acute grain engorgement, most likely occurring several months earlier. Other causes of chronic laminitis, however, could not be ruled out.

On 6 December 2002 case B, a young bull moose, was found dead near Kelso. The reporting party stated that the moose had been seen in that area for a few days. There were no apparent gunshot wounds. Case B was in good body condition at necropsy. There were 1-2 liters of free serosanguinous fluid within the abdomen. The rumen contents included grain of unrecorded type and grass. Several feet of the jejunum were flaccid and contained a thick bloody fluid and there was extensively petechiated hemorrhage in the mesentery in this area. Histologically, sections of intestine contained multifocal congestion in mucosa and submucosa with occasional mucosal hemorrhage. Mild lymphoplasmacytic inflammation was found in the mucosa. *Clostridium perfringens* was isolated from the intestine. The pathologist indicated that these findings were consistent with a diagnosis of enterotoxemia.

On 16 November 2004 case C, a bull moose, was reported recumbent and kicking in a field near Gardner; the district warden was sent to investigate. The warden reported that he had seen this bull the previous day and it had appeared healthy, but when the moose was approached it was unable to rise. It was noted that a large amount of feces appearing to contain blood surrounded the moose. The reporting party claimed that a neighbor had been feeding the moose all summer. Case

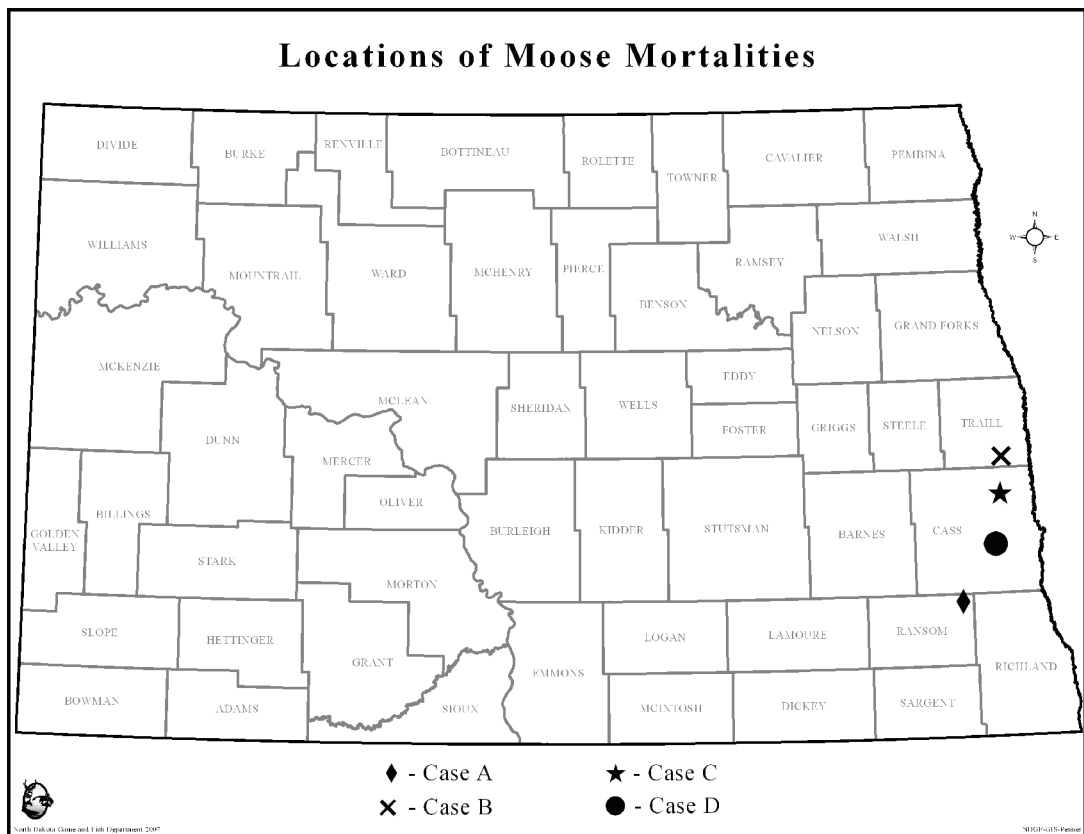


Fig. 2. Locations of moose mortalities in North Dakota which were possibly due to grain overload or its secondary effects.

C was shot and transported to the VDL. At necropsy, case C was found to be in good body condition with moderate postmortem autolysis. The contents and gross appearance of the forestomachs and abomasum were unremarkable. A large mass of hemorrhage was present within the tissue at the base of the mesentery and the small intestine contained frank blood. No mucosal lesions were present and the colon appeared normal. Congestion of the kidney and adrenal glands was noted. Histological examination revealed multifocal intraepithelial neutrophilic aggregates (microabscesses) in the ruminal epithelium and diffuse autolysis of all sections of the intestines. Fluorescent antibody examinations for bovine herpes virus 1, bovine viral diarrhea virus, bovine respiratory syncytial virus, and parainfluenza 3 virus were negative. Bacteriology isolated *Escherichia coli*, *alpha*

Streptococcus, and *Clostridium perfringens* from the liver, and *E. coli*, *alpha Streptococcus*, *Bacillus sp.*, and *C. perfringens* from the intestine. A diagnosis of hemorrhagic enteritis (with *C. perfringens*) and acute rumenitis was made. The acute rumenitis was suspected to be biochemical in origin, with grain overload a strong possibility.

On 3 January 2006 case D, an adult female moose, was seen circling and stumbling with a pronounced head tilt in Cass County, and was subsequently shot by a warden. Case D was in fair body condition at necropsy. In addition to 2 live nematodes removed from the abdominal cavity, a massive intrameningeal blood clot was seen ventral to the brain at the level of the thalamus and midbrain. The intrameningeal hemorrhages (not related to euthanasia) was associated with focally extensive polioencephalomalacia. On histopathology, a

single area of the meninges showed a massive blood clot, while the subjacent gray matter was markedly rarefied.

DISCUSSION

Laminitis, such as the severe chronic case documented in case A, is a common chronic sequel to previous grain overload in both domestic ruminants and horses. Less commonly, it can be secondary to postparturient metritis, endotoxemia, colic, enteritis (Merck Veterinary Manual 2008), copper deficiency (Flynn et al. 1977), and epizootic hemorrhagic disease (Prestwood et al. 1974). While serology for both bluetongue and epizootic hemorrhagic disease was negative, this animal did not have its copper levels tested. The large amount of corn present in the ingesta proves that large quantities were available to this animal suggesting that grain overload could have initiated laminitis several months earlier, however, other causes of laminitis cannot be ruled out.

The gross and histological intestinal lesions coupled with the isolation of *Clostridium perfringens* from the intestines of case B were highly suggestive of enterotoxemia. Enterotoxemia is a feed-related condition that often occurs in late winter when animals have not had access to grain for an extended period of time or with high intake of lush, green grasses (Merck Veterinary Manual 2008). There are multiple types of *Clostridium perfringens*, however, it is generally *Clostridium perfringens* types D and C that are responsible for enterotoxemia. PCR on the *Clostridium* isolate to determine its type was not performed. Grain overload is considered a common cause of enterotoxemia, though other less likely causes such as *E. coli* infection in swine have been identified (Merck Veterinary Manual 2008). The presence of grain in the rumen indicates that this moose also had access to grain and supports the possibility that case B suffered from fatal enterotoxemia due to grain overload.

The history of case C being observed by

the warden as healthy in a field the day prior to its euthanasia, its clinical signs of recumbancy and kicking, and the postmortem findings of acute rumenitis and hemorrhagic enteritis are highly indicative of grain overload. Like most cases of polioencephalomalacia, the pathology observed in case D was most likely due to a thiamine deficiency. Thiamine deficiencies are often secondary to ruminal acidosis, as one of the microorganisms which proliferate with grain intake produces thiaminase II, an enzyme which catalyzes the cleavage of thiamine (Merck Veterinary Manual 2008). Other causes for thiamine deficiency include water deprivation and hypernatremia (Padovan 1980), diets high in sulfate salts (Raisbeck 1982), acute lead poisoning (Merck Veterinary Manual 2008), and thiaminase toxicity, caused by the ingestion of certain plants (Evans et al. 1975). While the exact cause of case D's polioencephalomalacia remains unknown, it is possible that it was due to grain overload.

Based on these 4 cases, it appears that grain overload may be a contributing mortality factor of moose in North Dakota. Numerous scenarios which could result in grain overload exist. The 4 most likely include the consumption of planted crops such as corn and wheat, access to bait piles mainly intended for deer, access to cattle feeding sites, and access to recreational game feeding sites. Agricultural crops, especially corn and soybean, are common in the counties where the moose mortalities occurred, while cattle are less common than in other areas of the state (Fig. 1).

All 4 of these cases died in mid-fall or winter during the archery season. Case C was also found during the deer-gun season and was an acute case of rumenitis. Its euthanasia occurred in the middle of November when most crops had been harvested. This suggests that if grain overload was the cause of the rumenitis, the grain was most likely accessed at a baiting site or possibly a recreational feeding site. According to the NDGF district warden, reports of moose feeding with or harassing cattle

in this area are extremely uncommon. Case A was an extremely chronic case of laminitis, indicating that if grain overload had occurred, it was quite some time prior to its euthanasia in October. When the possible grain overload occurred in cases B and D is unknown. Polioencephalomalacia and enterotoxemia are sub-acute results of grain overload. However, few, if any crops, remained in the field at the time of their death indicating that bait or feed was the most likely source. The fact that deer hunting season was also open supports the possibility of availability and access to bait. These findings could have important implications for baiting and recreational feeding regulations in North Dakota.

If agricultural crops are contributing to grain overload and its secondary effects in moose in North Dakota, its incidence could be expected to rise given the political and economic push for increased biofuel and ethanol production. The NDGF expects a fair amount of conservation reserve program land, highly erodible land taken out of crop production, to be converted to corn fields and for corn production to increase in existing fields as the value of this commodity continues to rise.

Based on these necropsy findings, grain overload and its secondary effects should be monitored in North Dakota's moose population, as well as in other agricultural areas or regions where baiting and recreational feeding are common. It is extremely difficult to attribute the mortality of free-ranging wildlife to grain overload. Therefore, whenever possible, entire carcasses or appropriate samples, including fixed and fresh specimens of liver, rumen, abomasum, omasum, reticulum, small intestine, large intestine, and brain, and when possible, whole blood, serum, feces, and rumen contents, should be submitted to a diagnostic lab for investigation.

ACKNOWLEDGMENTS

We would like to thank the NDGF wardens and field staff for their assistance in handling

and transporting moose and other wildlife to the VDL in Fargo for necropsies. We thank the VDL for conducting these necropsies. We thank the editor and two anonymous reviewers for their comments and suggestions. Finally, we thank the citizens of North Dakota for reporting sick and dead wildlife in a timely manner so that we may learn the causes of these illnesses and diseases.

REFERENCES

- EVANS, W. G., I. A. EVANS, D.J. HUMPHREYS, B. LEWIS, W. E. J. DAVIES, and R. F. E. AXFORD. 1975. Introduction of thiamine deficiency in sheep with lesions similar to those of cerebrocortical necrosis. *Journal of Comparative Pathology* 85: 253-265.
- FLYNN, A., A.W. FRANZMANN, P.D. ARNESON, and J.L. OLDEMEYER. 1977. Indications of a copper deficiency in a subpopulation of Alaskan moose. *Journal of Nutrition* 107: 1182-1189.
- JENSEN, W.F. 2001. Lewis and Clark in North Dakota: wildlife then and now. *North Dakota Outdoors* June: 10-19.
- KURTZ, H. J., and P. D. KARNS. 1969. Polioencephalomalacia in a white-tailed deer (*Odocoileus virginianus borealis*). *Veterinary Pathology* 6: 475-480.
- MERCK VETERINARY MANUAL. April 10, 2008. Whitehouse Station, New Jersey. <<http://www.merckvetmanual.com/mvm/service/>> (accessed June 2008).
- PADOVAN, D. 1980. Polioencephalomalacia associated with water deprivation in cattle. *Cornell Veterinarian* 70: 153-159.
- PRESTWOOD, A.K, T.P. KISTNER, F.E. KELLOG, and F.A. HAYES. 1974. The 1971 outbreak of hemorrhagic disease among white-tailed deer of the southeastern United States. *Journal of Wildlife Diseases* 10: 217-224.
- RAISBECK, M. F. 1982. Is polioencephalomalacia associated with high sulfate diets? *Journal of the American Veterinary Medical Association* 180: 1303-1304.

- REED, D. E. H. SHAVE, M.E. BERGELAND, and C.E. GATES. 1976. Necropsy and laboratory findings in free-living deer in South Dakota. *Journal of the American Veterinary Medical Association* 169:975-979.
- STEVENS, C. E. 1998. *Comparative physiology of the vertebrate digestive system*. Cambridge University Press, Cambridge, New York.
- USDA, National Agricultural Statistics Service, North Dakota Field Office, Fargo, North Dakota. <http://www.nass.usda.gov/Statistics_by_State/North_Dakota/index.asp> (accessed June 2008).
- WOBESER, G., and W. RUNGE. 1975. Rumen overload and ruminitis in white-tailed deer. *Journal of Wildlife Management* 39: 596-600.
- _____, P. Y. DAoust, and H.M. HUNT. 1983. Polioencephalomalacia-like disease in pronghorns (*Antilocapra americana*). *Journal of Wildlife Diseases* 19: 248-252.
- WOODBURY, M. R., J. BEREZOSKI, and J. HAIGH. 2005. A retrospective study of the causes of morbidity and mortality in farmed elk (*Cervus elaphus*). *The Canadian Veterinary Journal* 46: 1108-1121.
- WOOLF, A., and D. KRADEL. 1977. Occurrence of rumenitis in a supplementary fed white-tailed deer herd. *Journal of Wildlife Diseases* 13: 281-285.