

Original Article

Stem cell therapy as one of temporary measures for management of heart failure and pulmonary hypertension in children

Aris Lacis^{1*}, Inguna Lubaua², Andis Lacis², Andrejs Erglis³

¹Department of Pediatric Cardiology and Cardiac Surgery, University Children Hospital, Latvia

²Riga Stradins University, Latvia

³The Latvian Institute of Cardiology, Latvia

Abstract. Favourable results of experimental studies on animals and several conditions in adult population indicate that bone marrow derived progenitor stem cell (BMPSC) transplantation may play a crucial role. Nevertheless, little is known about possible implementation of the BMPSC transplantation in children, dilated cardiomyopathy and pulmonary hypertension in particular. An increasing understanding of the nature and processes of idiopathic dilated cardiomyopathy and pulmonary arterial hypertension in children, as well as the limited treatment options have led our research towards the use of stem cell transplantation in the management of these patients. We performed intramyocardial BMPSC transplantation in 6 patients (4 months to 17 years) with dilated cardiomyopathy. All patients underwent complete detailed examination before and after the procedure. All patients demonstrated an increase in LVEF and degree of shortening of the left ventricular diameter between end-diastole and end-systole after the procedure. A decreased concentration of natriuretic peptide or LVDD on 2D and 3D echocardiography was observed in 5 and 3 of the 6 patients respectively. Intrapulmonary BMPSC transplantation was performed in two patients (9 and 15 years old) with severe pulmonary hypertension due to uncorrected large ventricular septal defects. Both patients showed improvement in lungs' vascularization. No serious periprocedural side effects were observed. If applied wisely, the stem cell therapy appears to be a safe and effective way for stabilization of critically ill patients with both severe pulmonary hypertension and idiopathic cardiomyopathy.

Keywords: Stem cells, idiopathic dilated cardiomyopathy, pulmonary arterial hypertension, intramyocardial administration

Introduction

Dilated cardiomyopathy is a serious problem in pediatric cardiology field. Despite the relatively low incidence of 0.57 to 2.6 per 100,000 children, the mortality rate is high. One third of patients die within the first year after diagnosis [1, 2]. Up to 40% of these patients are defined as idiopathic dilated cardiomyopathy (IDCM) characterized by ventricular dilatation and systolic dysfunction of unknown cause. The prognosis is poor in pediatric patients and survival appears to be related to the degree of systolic dysfunction. Conventional medical therapy often provides a short term relief of symptoms but does not improve the outcome of the disease. However, recent clinical studies [3, 4] have suggested bone marrow-derived autologous mononuclear cells or circulating progenitor cells [5, 6] as a promising therapy option for these patients. However, the most effective and safest way for delivery of these cells to the target area still needs to be established.

Pulmonary arterial hypertension (PAH) is characterized by increased pulmonary vascular resistance resulting in extensive heart structural changes, limiting patients exercise capacity and eventually leading to right heart

failure and death [7, 8].

A significant proportion of patients with congenital heart disease (CHD), in particular those with systemic-to-pulmonary shunts, will develop the most advanced form of PAH if left untreated. In these cases PAH is characterized by obstruction of small pulmonary arteries leading to progressive increase in vascular resistance. This increases right ventricular afterload and consequently results in right ventricular failure. Intima and media proliferation and its consequent pulmonary vascular obstruction are considered to be the key element in the pathogenesis of PAH. Vasoconstriction, vascular remodeling and thrombosis are factors that increase pulmonary vascular resistance in PAH [9].

We hypothesize based on the data obtained from experimental and clinical studies, that intrapulmonary implantation of bone marrow derived progenitor stem cell (BMPSC) increases the vascular bed in the pulmonary circulation leading to alleviation of PAH. Locally implanted stem cells may trigger the neovascularization process in the lung, potentially leading to a decrease of the mean pulmonary artery pressure. Justification for the use of intramyocardial and intrapulmonary stem cell implant-

* Corresponding author: Andis Lacis, MD (andis.lacis@rsu.lv).

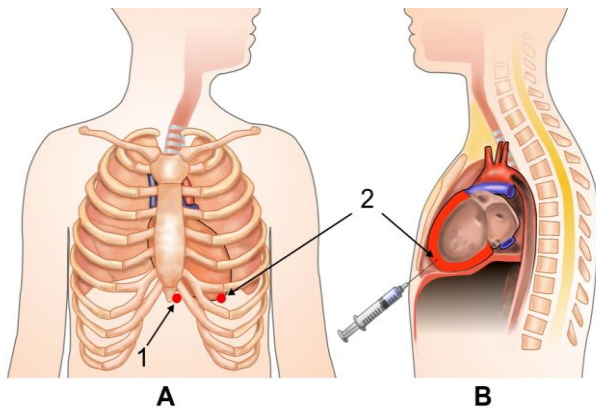


Figure 1 (A) Schematic positioning of transcutaneous (1) and intramyocardial (2) puncture. (B) Injection of cell suspension into the apex cordis.

tation was systematically discussed and planned by a team of cardiothoracic surgeons and cardiologists.

Materials and Methods

We used transdermal intramyocardial administration of BMPSC in critically ill patients with idiopathic dilated cardiomyopathy. All patients in this study gave informed consent and the study was approved by the Central Committee of Medical Ethics at the Ministry of Health.

This innovative technique if combined with ultrasound monitoring offers the possibility for delivery of stem cells right into the target area in a safe and effective way. In patients with severe pulmonary hypertension we used intrapulmonary delivery of stem cells. For assessment of treatment results we used various visual diagnostics as well as functional and laboratory tests.

Preparation of bone marrow aspirate

Bone marrow (5 to 30 ml) was aspirated from iliac crest and BMCs were isolated ranging from 17 to 122 million BMCs. Samples for flow cytometry were taken from 15 ml of mononuclear cell fraction and prepared for transplantation. Preparation of the isolated cells was carried out using Stem-kit™ reagents (Cat. Nr. IM3630; Beckman Coulter), that contained CD34-PE, CD45-FITCm isotype control, 7AAD (viability dye) and Stem-Count Fluorospheres. FACS analysis was performed on FC-500 (Beckman Coulter) and analyzed using CXP software. Each measurement contained at least 50,000 events. Maximum number of events was 100,000. The numbers of cells/μl were calculated for a total number of CD34+ cells within the transplantation material. Measurements with less than 50,000 events were excluded from the study.

Intramyocardial transplantation of stem cells

The procedure was performed under general anesthesia in the operating theatre, positioning a patient horizontally on the back. We used the 0.95 mm × 220 mm OptiMed CHIBA needle. Similar to the technique of pericardial puncture, we used the transcutaneous subxiphoid approach, poking through the skin (dot (1) in Fig. 1A) followed by gentle advancing toward the cardiac silhouette until a slight

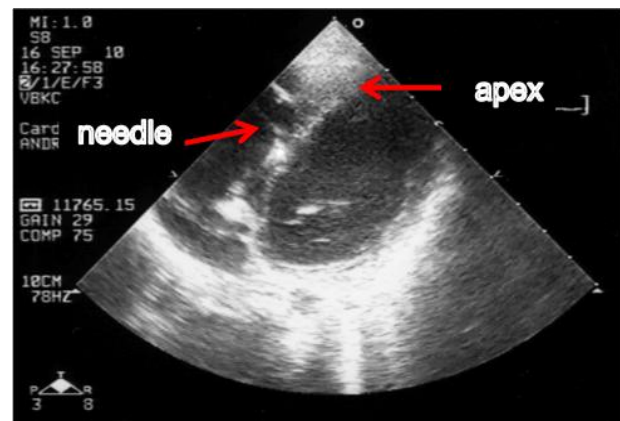


Figure 2 Echocardiographical visualization of transcutaneous intramyocardial injection of stem cells.

slight negative pressure was felt, searching for the apex cordis (dot (2) in Fig. 1B). When the apex cordis was reached, under echocardiographical control (Hewlett-Packard SONOS 4500) we performed an injection of 1 ml of cell suspension, subsequently followed by a second dose of 1 ml suspension with 1-2 min interval in between. A rationale to divide the injectable volume into two doses was based on concerns about a potential risk of barotrauma in myocardial tissues if the volume of a single dose would be too high.

Injection of cell suspension was controlled throughout the procedure via the US monitoring (Fig. 2). The most challenging step of the procedure was simultaneous movement of the US probe and the needle towards the apex cordis. A special attention has to be paid to risks related to potential penetration of the ultra-thin wall of the left ventricle.

Shortly after injection of the cell suspension, we performed an additional US control to visualize the immediate results of the procedure. In some cases we also used radiographic visualization for further control for the short-term effects of the procedure. Analgesic agent was administered as needed.

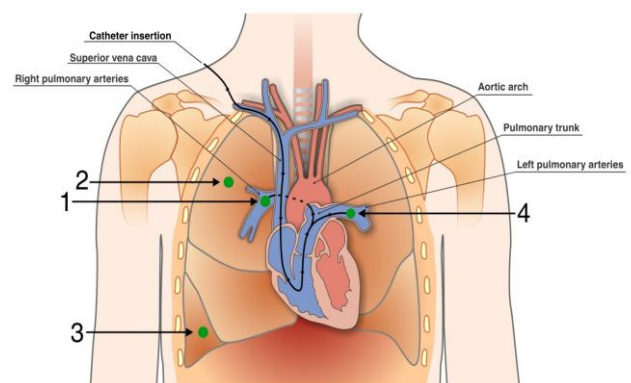


Figure 3 Intravascular injection of the stem cells was performed by catheterization of both pulmonary arteries via superior vena cava (dots 1 and 4).

Intrapulmonary transplantation of stem cells

Intravascular injection of the stem cells was performed by

TABLE 1
ECHOCARDIOGRAPHIC AND HEART FAILURE PARAMETERS OF THE PATIENTS

Factor	Patient 1		Patient 2		Patient 3		Patient 4		Patient 5		Patient 6	
	A	P	A	P	A	P	A	P	A	P	A	P
LVDD (mm.)	47	41	40	42	55	55	45	41	33	29	44	46
FS (%)	5	22	21	22	18	28	7	29	21	40	21	26
LVEF (%)	11	44	43	46	39	59	16	53	42	69	41	52
LVDEV (ml)	63	47	87	93	177	141	85	78	47	39	87	41
MVR (cm ²)	2.7	0.4	0.56	0.5	-	-	1.0	0.5	-	-	0.7	0.6
NT-proBNP (pg/ml)	1500	76	255	136	155	<20	4189	1469	1944	656	883	1784

Abbreviations: A: parameters before the procedure; P: parameters after the procedure; LVDD- left ventricular diastolic dimension; FS- fractional shortening; EF- ejection fraction; LVDEV- left ventricular end diastolic volume; MVR - mitral valve regurgitation area; NTproBNP- N-terminal of the prohormone brain natriuretic peptide

catheterization of both pulmonary arteries via superior vena cava (dots 1 and 4, Fig. 3).

For delivery of stem cells right into the tissues of the upper and lower lobes (dots 2 and 3, Fig. 5) of the right lung, we used a standard thoracocentesis technique, followed by puncture (0.95 mm × 220 mm OptiMed CHIBA needle) of respective lung structures and injection of 1 ml of cell suspension, performed under chest radiological control. No periprocedural complications were observed.

Results

We performed intramyocardial BMPSC transplantation in 6 patients (4 months to 17 years old) with dilated cardiomyopathy. All patients underwent quite detailed examination before and after the procedure. For monitoring the therapeutic response in patients with acute decompensated congestive heart failure we used clinical measures, including symptomatic relief of dyspnea, weight change, fluid balance, and resolution of S3 cardiac sounds, followed by other measurements to objectively follow up therapeutic responses, as illustrated in Table 1.

As shown in Table 1, all 6 patients demonstrated an increase in LVEF after the procedure. All patients after the procedure demonstrated an increase in the degree of shortening of the left ventricular diameter between end-diastole and end-systole. Serial natriuretic peptide measurements revealed a decreased concentration after the procedure in 5 of the 6 patients. A decrease of LVDD on 2D and 3D echocardiography was observed in 3 of the 6 patients.

We performed intrapulmonary BMPSC transplantation in two patients (9 and 15 years old) with severe pulmonary hypertension due to uncorrected large ventricular septal defects. Both patients underwent radionuclide scintigraphy before the procedure, followed by re-examination at 6, 12,

defects. Both patients under 24 and 36 months after that. Latest test results showed improvement in lungs' vascularization. No serious periprocedural side effects were observed.

For monitoring the therapeutic response, we used a lung perfusion scintigraphy (LPS) and a diagnostic imaging procedure that records the distribution of pulmonary arterial blood flow. For the LPS, we used a radiopharmaceutical Tc-99m-MAA (macro-aggregated albumin) with Siemens-ECAM 2-head &-camera after i/v injection. SPECT was used to obtain a 3-dimensional evaluation of the perfusion.

Lung scans using a SPECT technique

Examination results in both patients appeared to be very similar therefore we decided to include in this report scan series just from one patient. Scans revealed perfusion defects in the upper dorsal and lateral segments of the right lung. Slightly lower perfusion was detected also in the upper segments of the left lung (Fig. 4). The second study performed 6 months after the stem cell implantation procedure demonstrated remarkable improvement of perfusion in the upper segments of the right lung, as well as a small positive dynamics in the lateral segments of the right lung (Fig. 5). Further investigations carried out 18 and 32 months after the stem cell transplantation respectively (Figs. 6 and 7) demonstrated a trend toward improving perfusion of the right lung. the right one in particular. None of the consecutive studies performed revealed considerable changes in perfusion of the left lung after the stem cell implantation.

Discussion

Despite a considerable number of studies in respective fields, the role of stem cell transplantation in restoration of myocardial and pulmonary tissues remains to be clarified.

There is ample extensive research data available on

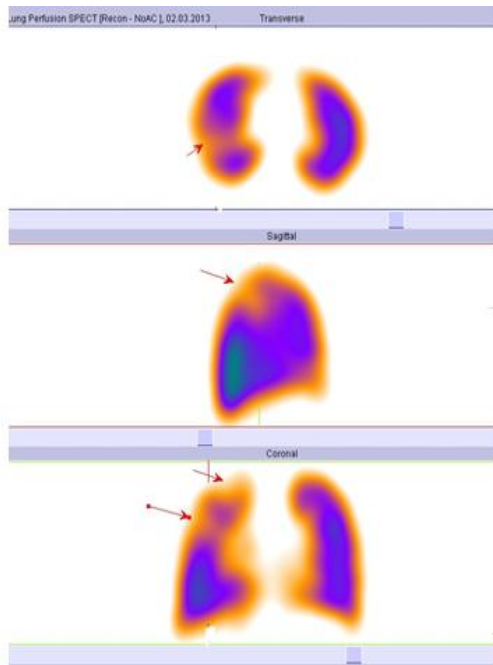


Figure 4 Lung perfusion before the stem cell transplantation. Arrows (in red) indicate the areas with decreased lung perfusion.

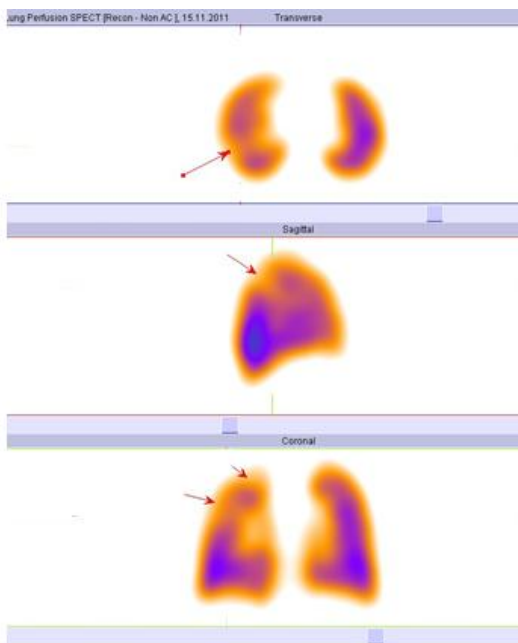


Figure 5 Lung perfusion 6 months after the stem cell transplantation. Arrows (in red) indicate the areas with decreased lung perfusion.

potential role of stem and progenitor cells in the management of ischemic heart disease. Some investigators report the potential role of bone marrow cells to promote paracrine effects in the ischemic tissues (e.g. secretion of angiogenic factors), and suggest that paracrine signaling, rather than cell incorporation, promotes functional recovery [10, 11]. Others conclude that progenitor cells

have the capability to home myocardium in response to ischemia. Cell adhesion markers, in particular integrins, play an important role in the trafficking of stem cells to myocardium [12]. In addition, damaged myocardium secretes several chemokines and growth factors that recruit these precursor cells to the heart. Several studies have shown the role of different growth factors involved in the homing of stem cells to ischemic myocardium including stem cell factor [13], vascular endothelial growth factor [14], neural growth factor [15], granulocyte-colony stimulating factor [16], insulin-like growth factor [17], hepatocyte growth factor [18], and fibroblast growth factor [19]. Several experimental studies have established a role of endothelial nitric oxide (eNOS) synthase as an essential component for neovascularization [20]. Evidently, eNOS influences recruitment of stem and progenitor cells which may be considered contributing to impaired regeneration processes in ischemic heart disease patients, who are characterized by a reduced systemic nitric oxide bioactivity.

Erythropoietin has also been shown to improve cardiac function by inducing neovascularization. Investigators suggest that this neovascularization appears to be related to increased mobilization and incorporation of bone marrow derived endothelial progenitor cells. Erythropoietin has been shown to lead to preferential homing of endothelial progenitor cells to the ischemic border zone of myocardial infarcts resulting in improved microvascularization of ischemic cardiac tissue [21].

It still remains to be clarified which route of administration of stem cells is the safest and most effective. As reported by Schächinger et al., in patients after myocardial infarction undergoing intracoronary infusion of ^{111}In -oxine-labeled proangiogenic progenitor cells, a substantial amount of radioactivity is detected for several days in the heart, indicating homing of progenitor cells to the myocardium. Yet the amount of proangiogenic progenitor cells retained in the heart decreased progressively with time after the acute myocardial infarction. The study data suggest that proangiogenic progenitor cells preferentially home to extensive acute myocardial infarcts characterized by low viability and reduced coronary flow reserve [22]. Schots et al. reported on rapidly diminishing concentration of intracoronary-injected CD133+ peripheral blood progenitor cells in two patients, where detailed analysis showed 6.9% to 8.0% (after 2 hours) and 2.3% to 3.2% (after 12 hours) residual radioactivity at the heart [23]. This data may raise concerns whether intravascular injection of stem cells secures sufficient concentration in target tissues causing expected favorable effects. Nevertheless it is equally true that there is no established relationship between exposure time and documented clinical efficacy of injected stem cells.

Another concern regarding intracoronary infusion of stem cells regards possible risks related to the procedure. De Rosa et al., based on their study results concluded that intracoronary infusion of progenitor cells can be performed with adequate safety in patients with acute myocardial infarction or chronic heart failure, though cell-based therapies require intracoronary or intracardiac instrumentation, potentially associated with periprocedural

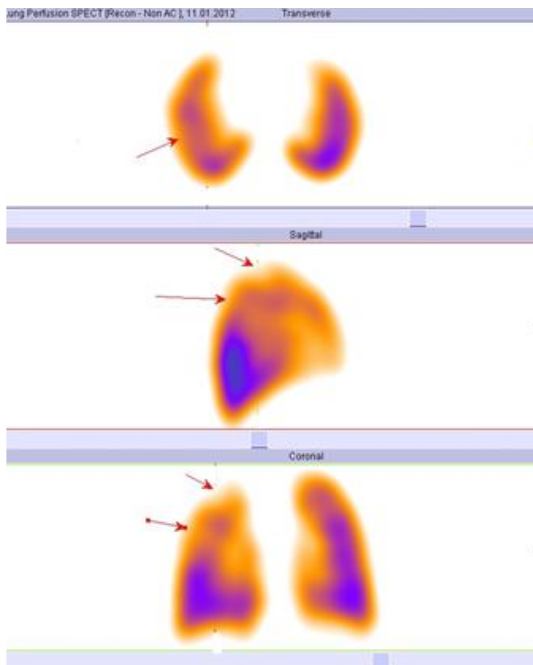


Figure 6 Lung perfusion 18 months after the stem cell transplantation. Arrows (in red) indicates the areas with decreased lung perfusion.

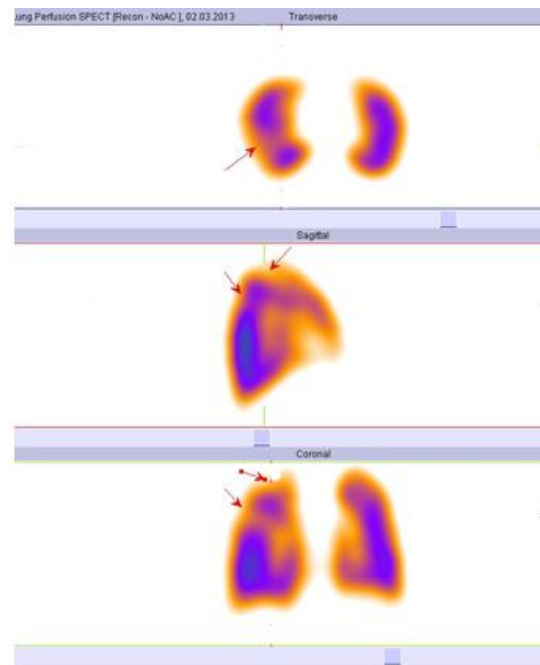


Figure 7 Lung perfusion 30 months after the stem cell transplantation. Arrows (in red) indicate the areas with decreased lung perfusion.

ral risks such as vessel injury in the access site and coronary complications [24].

It is still not clear what do stem cells have to do with pulmonary hypertension but it is an area of great interest and much ongoing research. There are numerous publications showing remarkable benefits using various kinds of stem or progenitor cells in experimental models of PAH. However, as humans are concerned, there is quite limited clinical experience with progenitor cell therapy in patients with PAH, because very few definitive and rigorously designed trials have been performed so far. Thus, it would be fair to say that the potential benefits and risks of progenitor cell therapy for PAH are largely unknown. Therefore, it has been widely recognized that this type of therapy may be offered only in the context of a research study that will help provide these answers. Prior to the stem cell treatment it is necessary to assess possible advantages of available conventional treatment, evaluating expected benefits and risks, as well as to assess the possible ethical problems.

Although important advances in symptomatic treatments have occurred, many lung diseases including emphysema, pulmonary fibrosis, cystic fibrosis, and others have no cure [7]. A conventional therapy of PAH consists of non-specific drugs including oral anticoagulation and diuretics as well as PAH specific therapy, including prostanoids (epoprostenol, treprostenil, iloprost), endothelin receptor antagonists (bosentan, ambrisentan) and phosphodiesterase type 5 inhibitors (sildenafil, tadalafil) [8].

One of the most commonly used non-medical treatment strategies is atrioseptostomy, creating an artificial communication to decrease the right heart volume. The surgical creation of a right-left shunt decreases right auricular

pressure and increases systemic blood flow, followed by reduction in right ventricular wall tension. However, atrioseptostomy has never been studied in controlled clinical trials and its role on long term survival has not been established. Based on the data published by several investigators, it can be concluded that immediate mortality is high, reaching 14% during the first week, particularly in the case of severe desaturation and right heart failure [25-27].

Lung transplantation was historically the treatment of choice for severe PAH and remains as such if medical treatments are insufficient [28]. However, this particularly heavy surgery can be proposed only to a minority of patients suffering from PAH. Moreover, long-term benefits remain disappointing, partly due to complications by acute and chronic rejection requiring lifelong immunosuppression with approximately 50% survival at 5 years, partly due to the donor graft induced antigenicity and extremely common infections, owing to the immunological and anatomical features of the lungs [29, 30]. Besides, there is a critical shortage of donor lungs. All the above-mentioned points suggest that new approaches for lung diseases, including PAH are desperately needed.

There have been convincing results obtained from experimental studies with regeneration of damaged pulmonary vasculature by exogenously administered stem cells in dogs [30]. According to the researchers, neovascularization in the lung could increase the volume of the vascular bed in the pulmonary circulation and thus reduce the development of PH, presuming that EPCs might be a potential cell source for neovascularization. The results obtained led the investigators suggest that EPC transplantation into the lung is effective at preventing the progression of dehydromonocrotaline-induced PH in dogs,

posing a new therapeutic option for PH. Similar results have been obtained from studies with rats. Using a similar model of PAH (monocrotaline-induced), the authors achieved restoration of the microvasculature structures and function of the artificially damaged lungs. The authors conclude that the regeneration of lung vascular endothelium by injection of progenitor cells may represent a novel treatment paradigm for patients with PAH [31]. Similar conclusions have been made based of results obtained from many other studies [32-34].

The latest data show that paracrine effects and secretion of growth factors are mainly responsible for stimulation of native angiogenesis, not just the EPCs as was suggested by earlier studies. Anyway, whatever mechanism(s) is behind these alterations, both anatomic and physiologic improvement in pulmonary hypertension has been clearly documented in animal models. It has been established that autologous implantation of bone marrow derived progenitor or stem cells leads to structural repair and regeneration of the lung.

Furthermore, currently very few studies on effects of autologous stem cell administration to PH in humans have been performed [35]. However, preliminary clinical trials using EPC-based therapies in patients with pulmonary hypertension show benefit of this approach, thus revealing EPCs as potential therapeutic targets [36-38]. In addition, information is available on two ongoing trials of cell therapy in PAH patients, which are being conducted in China and Canada, the results of which will be available in the coming years.

Therefore, many questions still have to be answered. For instance, the question about the best route of administration of the stem cells in patients with PH still remains controversial. It is not yet established whether these cells can engraft and acquire phenotype of structural lung cells following either systematic or intratracheal or local injection. It is also not clear which is the best cell source (bone marrow versus peripheral blood) and the best cell type (endothelial or haematopoietic progenitor cells or MSC) to be used. It is still not established whether cell therapy is effective in idiopathic PAH alone or in association with PH as well, and which is the best disease stage for cell therapy to be applied.

Data from experimental studies suggest that bone marrow cell transplantation reduces the development of PH by increasing vascular beds in pulmonary circulation [33, 38]. Although the underlying mechanism is not yet determined, several factors are expected to contribute to cellular differentiation, transdifferentiation, paracrine and cell-cell effects [39].

These results led to human studies of pro-angiogenic cell transplantation, demonstrating significant clinical improvement in patients with PAH [37, 38]. However, the trial design was limited by the fact that it included only a single 12-week follow-up, lack of sham treatment, and lack of blinding. These studies have now spurred a randomized controlled trial investigating eNOS transfected pro-angiogenic cells as a therapy for pulmonary hypertension (ClinicalTrials.gov Identifier: NCT00469027). The above studies demonstrate a possible role for autologous

angiogenic cell transplant in the treatment of PAH and suggest that subsets of pro-angiogenic cells may have a protective application in PAH. However, since pro-angiogenic hematopoietic cells do not permanently incorporate into the endothelium, the long-term effects of such treatment are unknown.

Cell therapies using various stem cells have been extensively evaluated. Available research data indicate possible reparative roles of exogenously administered stem cells, demonstrating potential for structural repair for damaged lungs, notably repair of damaged lung vasculature through paracrine effects of circulating endothelial progenitor cells (EPCs). These studies have also demonstrated potent immunomodulatory effects of adult bone marrow-derived mesenchymal stromal cells (MSCs) in a variety of inflammatory and immune lung diseases. These initial observations have led to a cautious initial but growing exploration of EPCs and MSCs in clinical trials of pulmonary hypertension.

Mesenchymal stem cells (MSCs) are the most extensively evaluated candidates for clinical cell-based therapy. Many clinical trials using MSCs have been registered and are ongoing. Autologous MSCs are easily isolated from the bone marrow and other tissues. MSCs are expected to reduce inflammation and promote the repair process. These beneficial effects are thought to be based on the ability of MSCs to modulate the immune system and their capacity to produce growth factors and cytokines, such as keratinocyte growth factor, HGF, and prostaglandin E2 [40].

Since their discovery about a decade ago, EPCs also have been subjected to intensive investigation [41]. However, as research opened deeper insights into EPCs biology, the enthusiasm of the pioneer era has been damped in favor of a more critical view. Recent studies are focused on three major questions: The fact that the number of EPCs in peripheral blood is exceedingly low has consistently raised suspicion whether these cells can plausibly have an impact on physiological or pathophysiological processes. Secondly, whereas the key role of EPCs in tumorigenesis has been strongly emphasized by various groups in the past, recent publications are challenging this hypothesis. Thirdly, the lack of consensus on EPC-defining markers and standardized protocols for their detection has repeatedly led to problems related to comparability among papers.

Although there is sufficient evidence supporting the endobronchial [42] and intravenous [22, 23] administration routes, we suppose they are not optimal. As recognized by the investigators themselves, an assumption that endobronchial infusion of stem cells may lead to morphological alterations in the vascular bed of the lung is highly speculative and needs further exploration before to apply in critically ill patients suffering from chronic lung disorder [42]. We support an argument, that an acceptable safety profile is very important criteria when thinking about innovative treatment options. However, a safety profile should not be the main or only criteria to consider in case of rapidly deteriorating PH when available conventional treatment strategies have failed.

In fact, available scientific data from both experimental and clinical studies suggest that concentration of implanted stem cells in the target tissues rapidly decreases shortly after the intravascular injection. Poor uptake of stem cells is explained by recirculation of the implanted cells by the blood flow [43, 44].

Substantial experimental evidence points to the role of the circulating progenitor cells in vascular pathology, which characterizes chronic PH. However, it is widely recognized that more study is needed to determine the types of progenitor cells involved in vascular remodeling and their specific functions, once they take up residence in the vessel wall. Much study is needed to determine the factors involved in their recruitment and retention [45-47].

It has been reported, that the hemodynamic alterations occurring with single-lung transplantation, that is, normalization of pressure and blood flow preferentially directed to the transplanted lung, may result in regression of the characteristic findings of PH in the native lung for primary PH patients [48]. We hypothesize that clinical and radiographical improvement of PAH after intrapulmonary implantation of stem cells can be caused by improvement of lung perfusion due to neovascularization of lung tissues.

As demonstrated by the case presented in this article, intrapulmonary injections directly into the lung parenchyma may cause even better results if compared with injection into the lung arteries. These results may be explained by higher concentration of the injected stem cells in the target tissues. As the mechanism of action is still not clear, we also speculate that injected cells trigger a neovascularization process in the lung, affecting much larger areas than those directly exposed to the implanted cells. The results achieved might be explained by the upregulation of hypoxia-inducible factor in vascular cells, leading to the production of bone marrow-mobilizing factors that recruit pro-angiogenic progenitor cells to the pulmonary circulation where they contribute to angiogenic remodeling of the vessel wall in PAH [49]. It still remains to be explored, if and why the effects of intrapulmonary injection of stem cells are not extended to the contralateral lung.

In summary, it has to be recognized that the optimal route of administration of stem cells is not known. The optimal dosage regimen, including the lower effective doses, is also unclear. The true potential for different types of stem cells (MSCs, ESCs) is not clear either. Issues also remain regarding what group of PH patients are most likely to benefit from treatment, at what point in the disease is treatment most likely to be successful [50,51]. No long term benefits have been established as well. All the mentioned above suggest that more studies are necessary to answer at least the most important questions. Until the prognosis for PAH remains unsatisfactory, stem cell therapy poses a new promising therapeutic option, requiring deeper understanding of underlying processes and long term effects caused by it.

Conclusions

If applied wisely, the stem cell therapy appears to be a safe and effective way for stabilization of critically ill

patients with both severe pulmonary hypertension and idiopathic cardiomyopathy. This method provides additional opportunities for symptomatic treatment and serves as a bridge for potential heart or lung transplantation. Potential benefits provided by the stem cell therapy should encourage multidisciplinary teams to think beyond the conventional and develop newer innovative strategies to obtain control of deteriorating clinical situations.

Conflicts of Interest

The authors declare no conflict of interest.

References

1. Alvarez J, Wilkinson JD, Lipshultz SE. The Pediatric Cardiomyopathy Registry Study Group. Outcome predictors for pediatric dilated cardiomyopathy: A systemic review. *Prog Pediatr Cardiol* 25-32, 2007.
2. Arola A, Tuominen J, Ruuskanen O, Jokinen E. Idiopathic dilated cardiomyopathy in children: prognostic indicators and outcome. *Pediatrics* 101:369-376, 1998.
3. Rupp S, Bauer J, Tonn T, et al. Intracoronary administration of autologous bone marrow-derived progenitor cells in a critically ill two-yr-old child with dilated cardiomyopathy. *Pediatr Transplant* 13:620-623, 2009.
4. Limsuwan A, Hongeng S, Khowsathit P, et al. Transcoronary bone marrow-derived mononuclear progenitor cells. *Cardiol Young* 20:336, 2010.
5. Olguntürk R, Kula S, Sucak GT, et al. A. Peripheral stem cell transplantation in children with dilated cardiomyopathy: preliminary report of first two cases. *Pediatr Transplant* 14:257-260, 2010.
6. Rivas J, Menedez JJ, Arrieta R, et al. Usefulness of intracoronary therapy with progenitor cells in patients with dilated cardiomyopathy: Bridge or alternative to heart transplantation. *Anales de pediatria* 74:218-225, 2011.
7. Lau AN, Goodwin M, Kim CF, Weiss DJ. Stem cells and regenerative medicine in lung biology and diseases. *Mol Ther* 20:1116-1130, 2012.
8. Montani D, Gunter S, Dorfmueller P, et al. Pulmonary arterial hypertension. *Orphanet J Rare Dis* 8:97, 2013.
9. O'Callaghan DS, Savale L, Montani D, et al. Treatment of pulmonary arterial hypertension with targeted therapies. *Nat Rev Cardiol* 8:526-538, 2011.
10. Murry CE, Soonpaa MH, Reinecke H, et al. Haematopoietic stem cells do not transdifferentiate into cardiac myocytes in myocardial infarcts. *Nature* 428:664-668, 2004.
11. Heil M, Ziegelhoeffer T, Mees B, Schaper W. A different outlook on the role of bone marrow stem cells in vascular growth: bone marrow delivers software not hardware. *Circ Res* 94:573-574, 2004.
12. Taghavi S, George JC. Homing of stem cells to ischemic myocardium. *Am J Transl Res* 5:404-411, 2013.
13. Bodine D, Seidel N, Gale M, et al. Efficient retrovirus transduction of mouse pluripotent hematopoietic stem cells mobilized into the peripheral blood by treatment with granulocyte colony-stimulating factor and stem cell factor. *Blood* 84:1482-1491, 1994.

14. Shintani S, Murohara T, Ikeda H, et al. Mobilization of endothelial progenitor cells in patients with acute myocardial infarction. *Circulation* 103:2776-2779, 2001.
15. Meloni M, Caporali A, Graiani G., et al. Nerve growth factor promotes cardiac repair following myocardial infarction. *Circ Res* 106:1275-1284, 2010.
16. Zohnhofer D, Ott I, Mehilli J, et al. Stem cell mobilization by granulocyte colony-stimulating factor in patients with acute myocardial infarction. *JAMA* 295:1003-1010, 2006.
17. Rota M, Padin-Iruegas ME, Misao Y, et al. Local activation or implantation of cardiac progenitor cells rescues scarred infarcted myocardium improving cardiac function. *Circ Res* 103:107-116, 2008.
18. Urbanek K, Rota M, Cascapera S, et al. Cardiac stem cells possess growth factor-receptor systems that after activation regenerate the infarcted myocardium, improving ventricular function and long-term survival. *Circ Res* 97:663-673, 2005.
19. Wang Y, Johnsen HE, Mortensen S, et al. Changes in circulating mesenchymal stem cells, stem cell homing factor, and vascular growth factors in patients with acute ST elevation myocardial infarction treated with primary percutaneous coronary intervention. *Heart* 92:768-774, 2006.
20. Aicher A, Heeschen C, Mildner-Rihm C, et al. Essential role of endothelial nitric oxide synthase for mobilization of stem and progenitor cells. *Nat Med* 9:1370-1376, 2003.
21. Westenbrink BD Lipsic E, Van der Meer P, et al. Erythropoietin improves cardiac function through endothelial progenitor cell and vascular endothelial growth factor mediated neovascularization. *Eur Heart J* 28:2018-2027, 2007.
22. Schächinger V, Aicher A, Döbert N, et al. Pilot trial on determinants of progenitor cell recruitment to the infarcted human myocardium. *Circulation* 118:1425-1432, 2008.
23. Schots R, De Keulenaer G, Schoors D, et al. Evidence that intracoronary-injected CD133+ peripheral blood progenitor cells home to the myocardium in chronic postinfarction heart failure. *Exp Hematol* 35:1884-1890, 2007.
24. De Rosa S, Seeger FH, Honold J, et al. Procedural safety and predictors of acute outcome of intracoronary administration of progenitor cells in 775 consecutive procedures performed for acute myocardial infarction or chronic heart failure. *Circ Cardiovasc Interv* 6:44-51, 2013.
25. Sandoval J, Gaspar J, Pulido T, et al. Graded balloon dilation atrial septostomy in severe primary pulmonary hypertension. A therapeutic alternative for patients nonresponsive to vasodilator treatment. *J Am Coll Cardiol* 8:297-304, 1998.
26. Rothman A, Sklansky MS, Lucas VW, et al. Atrial septostomy as a bridge to lung transplantation in patients with severe pulmonary hypertension. *Am J Cardiol* 8:682-686, 1999.
27. Kurzyna M, Dabrowski M, Bielecki D, et al. Atrial septostomy in treatment of end-stage right heart failure in patients with pulmonary hypertension. *Chest* 8:977-983, 2007.
28. Sitbon O, Humbert M, Simonneau G. Primary pulmonary hypertension: Current therapy. *Prog Cardiovasc Dis* 8:115-128, 2002.
29. Hosenpud JD, Bennett LE, Keck BM, et al. The Registry of the International Society for Heart and Lung Transplantation: eighteenth Official Report-2001. *J Heart Lung Transplant* 8:805-815, 2001.
30. Takahashi M, Nakamura T, Toba T, et al. Transplantation of endothelial progenitor cells into the lung to alleviate pulmonary hypertension in dogs. *Tissue Eng* 10:771-779, 2004.
31. Zhao YD, Courtman DW, Deng Y, et al. Rescue of monocrotaline-induced pulmonary arterial hypertension using bone marrow-derived endothelial-like progenitor cells: efficacy of combined cell and eNOS gene therapy in established disease. *Circ Res* 96:442-450, 2005.
32. Lam CF, Liu YC, Hsu JK, et al. Autologous transplantation of endothelial progenitor cells attenuates acute lung injury in rabbits. *Anesthesiology* 108:392-401, 2008.
33. Yoshida H, Kitaichi T, Urata M et al. Syngeneic bone marrow mononuclear cells improve pulmonary arterial hypertension through vascular endothelial growth factor upregulation. *Ann Thorac Surg* 88:418-424, 2009.
34. Kanki-Horimoto S, Horimoto H, Mieno S, et al. Implantation of mesenchymal stem cells overexpressing endothelial nitric oxide synthase improves right ventricular impairments caused by pulmonary hypertension. *Circulation* 114:181-185, 2006.
35. Farkas L, Kolb M. Vascular repair and regeneration as a therapeutic target for pulmonary arterial hypertension. *Respiration* 85:355-364, 2013.
36. Fadini GP, Avogaro A, Ferraccioli G, Agostini C. Endothelial progenitors in pulmonary hypertension: new pathophysiology and therapeutic implications. *Eur Respir J* 35:418-425, 2010.
37. Wang XX, Zhang FR, Shang YP, et al. Transplantation of autologous endothelial progenitor cells may be beneficial in patients with idiopathic pulmonary arterial hypertension: a pilot randomized controlled trial. *J Am Coll Cardiol* 49:1566-1571, 2007.
38. Zhu JH, Wang XX, Zhang FR, et al. Safety and efficacy of autologous endothelial progenitor cells transplantation in children with idiopathic pulmonary arterial hypertension: open-label pilot study. *Pediatr Transplant* 12:650-655, 2008.
39. Hayes M, Curley G, Ansari B, Laffey JG. Clinical review: Stem cell therapies for acute lung injury/acute respiratory distress syndrome - hope or hype? *Crit Care* 16:205, 2012.
40. Kubo H. Concise Review: Clinical Prospects for Treating Chronic Obstructive Pulmonary Disease with Regenerative Approaches. *Stem Cells Transl Med* 1:627-631, 2012.

41. Resch T, Pircher A, Kahler CM, et al. Endothelial Progenitor Cells: Current Issues on Characterization and Challenging Clinical Applications. *Stem Cell Rev* 8:926-939, 2012.
42. Tzouveleakis A, Paspaliaris V, Koliakos G, et al. A prospective, non-randomized, no placebo-controlled, phase Ib clinical trial to study the safety of the adipose derived stromal cells-stromal vascular fraction in idiopathic pulmonary fibrosis. *J Transl Med* 11: 171, 2013.
43. Lacis A, Lubaua I, Erglis A, et al. Management of idiopathic dilated cardiomyopathy with intramyocardial stem cell transplantation in children: a retrospective study of 7 patients. *Science J of Clin Med* 2:129-133, 2013.
44. Barbash IM, Chouraqui P, Baron J, et al. Systemic delivery of bone marrow-derived mesenchymal stem cells to the infarcted myocardium: feasibility, cell migration, and body distribution. *Circulation* 11:863-868, 2003.
45. Peinado VI, Ramirez J, Roca J, et al. Identification of vascular progenitor cells in pulmonary arteries of patients with chronic obstructive pulmonary disease. *Am J Respir Cell Mol Biol* 34:257-263, 2006.
46. Firth AL, Yao W, Ogawa A, et al. Multipotent mesenchymal progenitor cells are present in endarterectomized tissues from patients with chronic thromboembolic pulmonary hypertension. *Am J Physiol Cell Physiol* 298:1217-1225, 2010.
47. Yeager ME, Frid MA, Stenmark KR. Progenitor cells in pulmonary vascular remodeling. *Pulm Circ* 1:3-16, 2011.
48. Levy NT, Liapis H, Eisenberg PR, et al. Pathologic regression of primary pulmonary hypertension in left native lung following right single-lung transplantation. *J Heart Lung Transplant* 20:382-384, 2001.
49. Duong H, Erzurum S, Asosingh K. Pro-angiogenic Hematopoietic Progenitor Cells and Endothelial Colony Forming Cells in Pathological Angiogenesis of Bronchial and Pulmonary Circulation. *Angiogenesis* 14:411-422, 2011.
50. Majka S, Burnham E, Stenmark KR. Cell-based therapies in pulmonary hypertension: who, what, and when? *Am J Physiol Lung Cell Mol Physiol* 301: 9-11, 2011.
51. Warburton D, Perin L, DeFilippo R, et al. Stem/Progenitor Cells in Lung Development, Injury Repair, and Regeneration. *Proc Am Thorac Soc* 5:703-706, 2008.