

Prostatic abscess: Case report and review of the literature

Orestis Porfyris, Paraskevas Kalomoiris

Urology Department, General Hospital of Sparta, Sparta, Greece.

Summary

We report a case of prostatic abscess in a 52 year old male with a history of diabetes mellitus. The abscess was treated successfully with surgical drainage by transurethral unroofing of the cavity of the abscess.

The use of transrectal ultrasound is valuable in the diagnosis, treatment and follow up of the abscess, while drainage is usually necessary for the treatment, which can be done by transrectal, transperineal and transurethral route.

KEY WORDS: Abscess; Prostate; Drainage.

Submitted 2 April 2013; Accepted 31 May 2013

No conflict of interest declared

INTRODUCTION

Prostatic abscess is uncommon and difficult to diagnose because initial clinical presentation may mimic several other diseases of the lower urinary tract. The incidence of prostatic abscess has markedly decreased because of the widespread use of antibiotics and the decreased incidence of gonococcal urethritis. In the forties, mortality ranged from 6% to 30%, and major microorganism involved was *Neisseria gonorrhoea* (1). More recent data suggests a mortality rate from 3% to 16% (2), *Enterobacteriaceae* being the most common agents. Among these, *Escherichia coli* has the highest prevalence, in about 70% of the cases (3). In this paper we report a case of prostatic abscess treated in our department and review the literature as far as the clinical presentation, diagnostic modalities and management is concerned.

CASE REPORT

A 52-year-old male presented at the emergency department of our hospital with dysuria, high fever, chills, perineal pain and poor general condition. A few days before he visited a private urologist who diagnosed acute prostatitis with urine culture positive for *E. coli*. He received ciprofloxacin and although there was an improvement at the beginning, the symptoms recurred. He was a known diabetic patient.

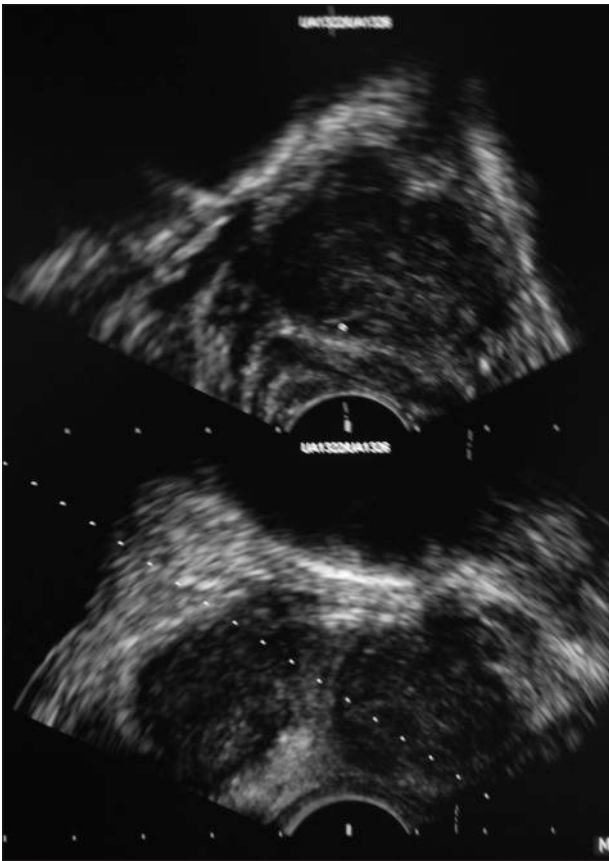
On physical examination, his blood pressure, pulse rate

and temperature were 130/80mmHg, 95 per minute and 39° C, respectively. At rectal examination, the prostate was tender and enlarged with a fluctuating area between the two lobes.

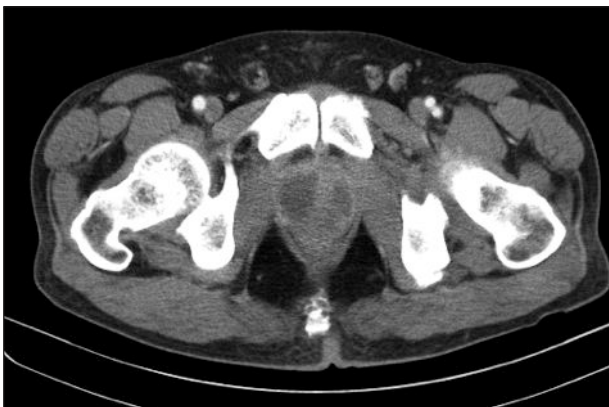Urine and blood cultures were obtained prior to starting antibiotic therapy. Transabdominal ultrasonography of the prostate showed a hypoechoic area. Transrectal ultrasonography showed two hypoechoic areas, one in the right and one in the left lobe (Figure 1). Computed tomography scan revealed two hypodense, homogenous areas with size 3 x 3,5 cm, in the same region of the prostate (Figure 2). The patient was treated with ciprofloxacin, amikacin and metronidazole intravenously. Under ultrasonography guidance the abscess was drained transrectally. About 7 ml of pus were obtained and its culture showed *Klebsiella pneumoniae*. The same agent was found in blood cultures as well. During follow up the same procedure was repeated due to incomplete emptying of the abscess cavities. Finally it was decided that the patient should have a transurethral drainage of the abscess. The simultaneous use of transrectal ultrasound confirmed the complete drainage of the abscess. The postoperative recovery of the patient was normal and on the 6th day after the TUR the patient was discharged. One month later, the patient was symptom free, the urine culture was negative and the transrectal ultrasound appeared normal (Figure 3).

Figure 1.

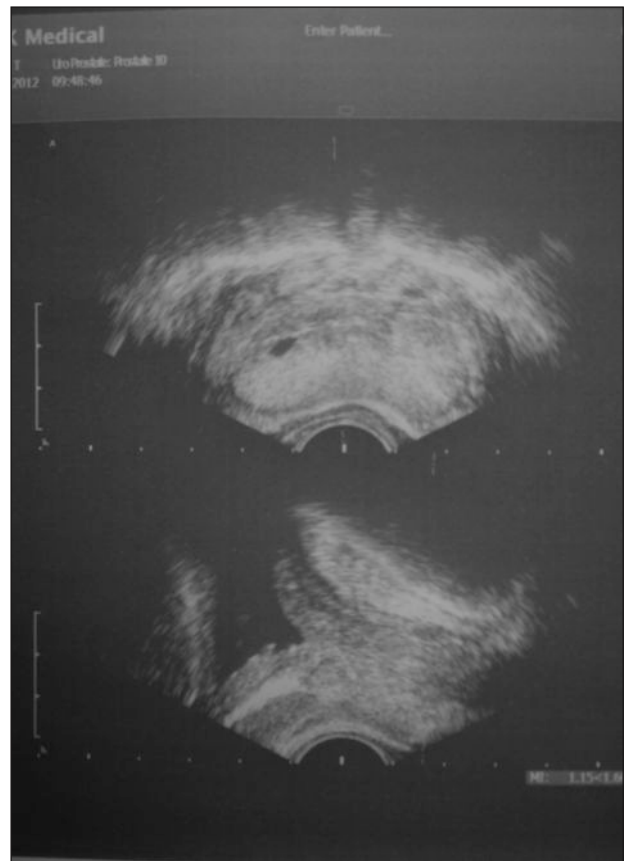
Transrectal ultrasound showing prostatic abscess with two cavities.

**Figure 2.**

CT scan depicting the prostatic abscess.

**Figure 3.**

Transrectal ultrasound 1 month after transurethral resection.



DISCUSSION

Prostatic abscess is an infrequent condition in the modern antibiotic era with an incidence of 0.5% to 2.5% of diseases accompanying prostatic symptoms (4). It can occur in patients of any age (including neonates) but is mainly found in men in their 5th and 6th decade of life (2). Predisposing factors for the development of prostat-

ic abscess are diabetes mellitus, bladder outlet obstruction, indwelling catheter, biopsy of prostate, chronic renal failure, haemodialysis, chronic liver disease and HIV infection (5,6). As far as pathogenesis is concerned, it is the retrograde flow of contaminated urine during micturition into prostatic ducts that promotes the formation of microabscesses that coalesce and form prostatic abscesses (3).

It is already mentioned that *E. coli* and *Enterobacteriaceae* are the most prevalent bacteria in prostatic abscess. Nevertheless, as the number of immunocompromised patients increase, atypical pathogens may be found, like mycobacteria, fungi, anaerobes and in case of haematogenous spread from distant foci, *Staphylococcus aureus* (7).

Clinical manifestation of the disease includes dysuria, urgency and frequency in 96% of the cases, fever in 30% to 72% of the cases, perineal pain in 20% of the cases and urinary retention in 1/3 of the cases (1, 2, 4). The most typical sign of prostatic abscess is a fluctuating area in the prostate palpated by digital examination, although this finding is observed in 16% to 88% of the patients (1,2). In case of improper treatment or delayed diagnosis possible complications are the spontaneous rupture of the abscess and fistula formation towards the urethra, bladder, perineum and rectum and also septicemia with mortality rate between 3% and 16% (4).

The diagnostic study of choice to assist the treatment and follow up of patients with prostatic abscess is transrectal ultrasonography. The most common finding is one or more hypoechoic lesions, of different sizes, located in the transitional or central zone of the prostate and surrounded by a hyperechoic halo, that can cause distortion of the anatomy of prostate gland (8). Color and power Doppler sonography show a high perilesional vascularity. Differential diagnosis includes neoplasias, cystic lesions, granulomas and acute prostatitis. CT scan and MRI scan usually add few information as far as diagnosis is concerned.

They are useful at the estimation of the extent of the abscess in the periprostatic tissues, at the detection of gas in the fluid of abscess and when extensive types of procedures are being planned after patient diagnosis (8).

The treatment consists of parenteral broad-spectrum antibiotic administration and abscess drainage. Due to the rareness of the disease there are no specific guidelines for the treatment of prostatic abscess. The administration of antibiotic agents by itself is effective in limited cases, such as monofocal abscess less than 1 cm in diameter. Usually surgical intervention is required, which can be done under ultrasound guidance by transrectal (9, 10) or transperineal route (11, 12).

These procedures are easy to perform under local anaesthesia, have low morbidity and can be repeated in case of failure. The culture of pus that is aspirated is important because pathogens isolated are often different from those found in urine culture.

This can result in modification of antibiotic treatment. Several authors recommend the insertion of drainage tubes (e.g. nephrostomy tubes) in the abscess cavity for achieving better drainage (10, 12). When the abscess recurs or cannot be completely evacuated, transurethral unroofing is a more appropriate approach, leading to better drainage of the abscess cavity with early recovery of the patient (7, 9). Although there is a theoretical danger of haematogenous spread of the pathogen during transurethral resection, the use of preoperative broad-spectrum antibiotics prevents the occurrence of septicemia.

Finally, in very few cases, open surgical drainage may be indicated mainly in those patients with extraprostatic involvement (7).

CONCLUSION

Prostatic abscess should be suspected in patients presenting with fever and persistent voiding symptoms despite proper antibiotic treatment, in diabetics and those with a disease that causes immunodeficiency. It is important to rapidly establish a definitive diagnosis because mortality rate remains high. Surgical drainage is usually required, even with minimal invasive techniques, but the optimal therapeutic modality for each patient should be individualized, aiming to prompt control of symptoms and early recovery.

REFERENCES

- Weinberger M, Cytron S, Servadio C, et al. Prostatic abscess in the antibiotic era. *Rev Infect Dis*. 1988; 10:239-49.
- Granados EA, Caffaratti J, Farina L, Hocsman H. Prostatic abscess drainage: Clinical-sonography correlation. *Urol Int*. 1992; 48:358-61.
- Meares EM, Jr. Prostatic abscess. *J Urol*. 1996; 129:1281-2.
- Granados EA, Riley G, Salvador J, Vincente J. Prostatic abscess: diagnosis and treatment. *J Urol*. 1992; 148:80-2.
- Oliveira P, Andrade JA, Porto HC, et al. Diagnosis and treatment of prostatic abscess. *Int Braz J Urol*. 2003; 29:30-34.
- Trauzzi SJ, Kay CJ, Kaufman DG, Lowe FC. Management of prostatic abscess in patients with human immunodeficiency syndrome. *Urology*. 1994; 43:629-33.
- Ludwig M, Schroeder-Printzen I, Schiefer HG, Weidner W. Diagnosis and therapeutic management of 18 patients with prostatic abscess. *Urology*. 1999; 53:340-5.
- Barozzi L, Pavlica P, Menchi I, et al. Prostatic abscess: diagnosis and treatment. *AJR*. 1998; 170:753-757.
- Collado A, Palou J, Garcia-Penit J, et al. Ultrasound-guided needle aspiration in prostatic abscess. *Urology*. 1999; 53:548-52.
- Aravantinos E, Kalogeras N, Zygoulakis N, et al. Ultrasound-guided transrectal placement of a drainage tube as therapeutic management of patients with prostatic abscess. *J Endourol*. 2008; 22:1751-4.
- Bachor R, Gottfried HW, Hautmann R. Minimal invasive therapy of prostatic abscess by transrectal ultrasound-guided perineal drainage. *Eur Urol*. 1995; 28:320-4.
- Basiri A, Javaherforooshzadeh A. Percutaneous drainage for treatment of prostate abscess. *Urol J*. 2010; 7:278-80.

Correspondence

Orestis Porfyrus, MD (Corresponding Author)
orestisporfyrus@yahoo.gr

Epia Thourias - 24009 Kalamatan, Greece

Paraskevas Kalomoiris, MD
diy@hospspa.gr

Vrasidou 156 - 23100 Sparta, Greece