

Use of Basilic vein in arteriovenous fistulas construction for hemodialysis access. Is it a good option alternative to prosthetic arteriovenous grafts?

Ehab M. Abdo¹, Tamer A. Abouelgreed², Waleed E. Elshinawy¹, Nehal Farouk¹, Mohamed A. Abdelaal², Hassan Ismail², Amal H. Ibrahim³, Samar A. Kasem³, Ahmed A. Aboomar⁴

¹ Department of Vascular Surgery, Faculty of Medicine, Al-Azhar University, Cairo, Egypt;

² Department of Urology, Faculty of Medicine, Al-Azhar University, Cairo, Egypt;

³ Department of Internal Medicine, Nephrology Unit, Faculty Medicine, Al-Azhar University, Cairo, Egypt;

⁴ Department of Internal Medicine, Nephrology Unit, Faculty Medicine, Tanta University, Tanta, Egypt.

Summary

Purpose: For patients with a failed forearm autogenous fistula (AF) and an exhausted cephalic vein, there is controversy about whether a brachial basilic AF with transposition or an arteriovenous prosthetic bridging graft (BG) must be the second vascular access option. This work measured and compared these two modalities according to patency rates, complications, and revisions.

Patients and methods: A retrospective study of 104 cases that had either a brachial basilic AF (72) or an Arteriovenous BG (32). Technical success, operative complications, procedure-related mortality, maturation time, functional primary, secondary, and overall patency rates were all assessed.

Results: Technical success was obtained in all participants.

No procedure-linked mortality. Maturation time for BGs was significantly shorter than AFs. The complication rate was significantly higher in BGs than in AFs. The most prevalent complication was access thrombosis. The functional primary patency rate was significantly higher in AF than in BG at 12-month follow-up: 77.7% vs 53.1% ($p < 0.012$). Secondary patency rate was higher in AF than in BG at 1-year follow-up 62.5% vs 42.8% ($p = 0.063$), respectively. In addition, BGs required more interventions to preserve patency.

Conclusions: AF had higher primary, secondary and overall functional patency rates and needed fewer procedures to keep patency than BGs. Cases that need early vascular access as a result of central venous catheter complications or who have a reduced life expectancy may benefit from BGs.

KEY WORDS: Hemodialysis; Basilic vein superficialization; Arteriovenous fistula.

Submitted 6 May 2023; Accepted 8 June 2023

INTRODUCTION

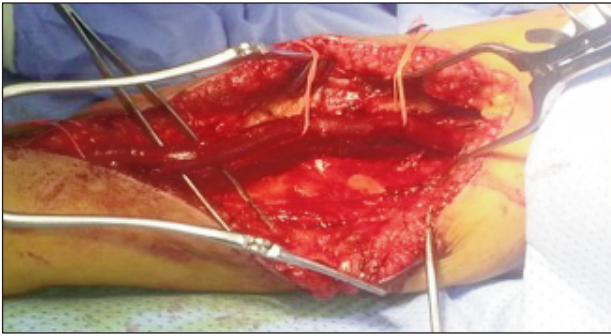
End-stage renal disease (ESRD) impacts over 1500 people per million populations in high-prevalence countries like Taiwan, Japan, and the United States. Nearly two-thirds of ESRD patients receive hemodialysis (HD), one-quarter receive kidney transplants, and one-tenth require peritoneal dialysis (1). Three types of procedures are commonly performed for HD, an indwelling central venous catheter, an AF, and prosthetic BGs. The ideal access

should deliver a flow rate sufficient for performing effective dialysis, durable, easily punctured, and has a low complication rate (2). AF comes closest to fulfilling these criteria, but AF use depends on the identification of a suitable artery and vein (3). Autogenous arteriovenous radial cephalic or brachial cephalic fistulas were recommended as 1st-line choices for vascular access by the *Kidney Disease Outcome Quality Initiative* (KDOQI) (4). However, not all HD patients can have a distal forearm fistula due to the small size of the vessel, diseased or exhausted peripheral veins, and arteries. Additionally, around 30% of the fistulas fail within 3 years and need alternative vascular access. Alternative access options are brachiocephalic AF in the forearm or brachial basilic AF in the arm or forearm or an arteriovenous BG in the arm. Brachiocephalic AF is the second option if a radial cephalic or forearm AF fails or is unsuitable (5, 6). However, when the cephalic vein in the arm cannot be utilized, a brachial basilic AF could be constructed. This study highlights our clinical surgical results for all types of basilic vein-based fistulas comparable to the results of prosthetic BG-based fistulas performed in the same period.

PATIENTS AND METHODS

Between March 2018 and February 2020, 72 patients were included in this retrospective study whose basilic vein was used for brachial-basilic AF at our hospital, and their surgical results were compared to the results of arm prosthetic BG constructed for hemodialysis. Patients included in this study had either previously failed radial-cephalic and brachial-cephalic AF operations or the diameter or quality of the arteries and cephalic veins are not suitable for AF construction. The most frequently linked diseases were recorded and analyzed. Additionally, the patient's demographics including age and gender were collected and analyzed. All cases were preoperatively examined using Doppler ultrasonography (USG) for assessment of basilic and cephalic veins. Furthermore, central veins (jugular and subclavian veins) were examined for occlusion and stenosis. Because the procedures necessitated long incisions and basilic vein dissection, they were carried out under region-

Figure 1.
Mobilization of the matured basilic vein
(retracted with red vessel loop).



al or general anesthesia. The basilic vein arises from the dorsal venous network of the hand and travels the medial aspect of the upper limb. The vein travels deep into the arm towards the teres major boundary. It joins the brachial veins of the deep venous system creating the axillary vein. Different techniques were used to construct brachial basilic AF: two stages of basilic vein elevation and transposition without anastomosis, two stages of arm basilic vein transposition and re-anastomosis, and forearm basilic vein loop transposition. The first stage consists of creating an end-to-

Figure 2.
Schematic diagram showing the normal anatomy (A) and the procedure.
The basilic vein is anastomosed to the brachial artery (B).
The arterialized basilic vein is superficialized and re-anastomosed (C).

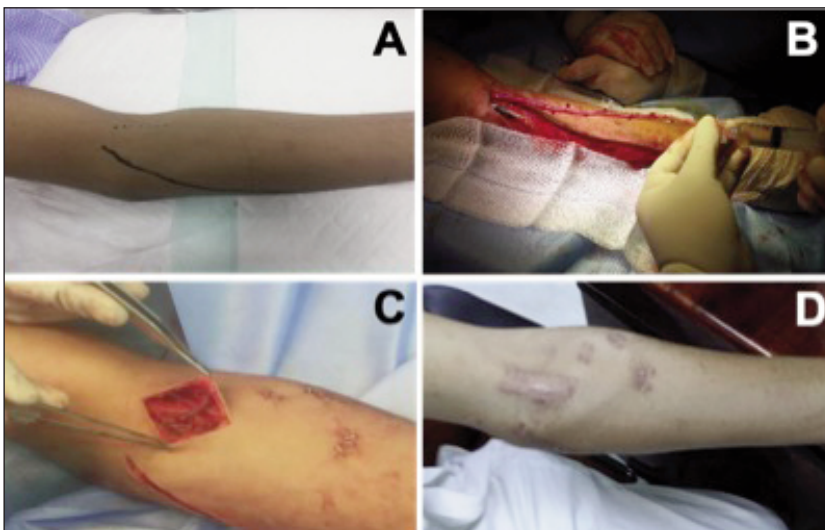
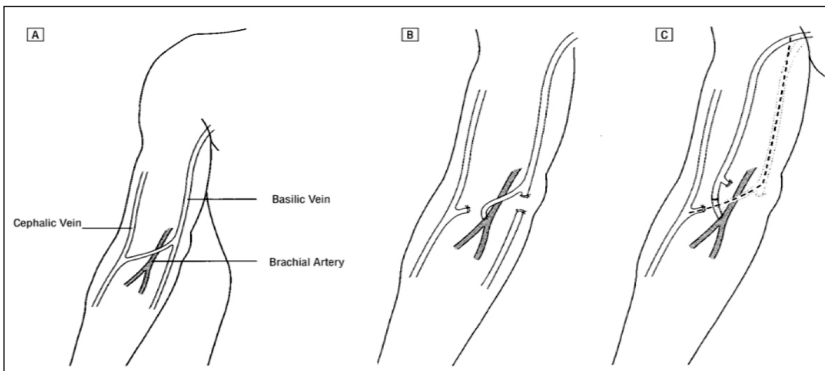


Figure 3.
(A) Ultrasound-guided marking of basilic vein.
(B) Augmentation of a mobilized basilic vein after ligation of its branches.
(C) The looped basilic vein was anastomosed to the brachial artery.
(D) Two weeks postoperative.

side basilic vein to the brachial artery fistula at the elbow level with 6/0 polypropylene sutures. The second stage is scheduled to begin in 6-8 weeks. First, a small incision was made in the antecubital region to locate both the basilic vein and brachial artery. Then the incision was extended proximally to expose the proximal portion of the basilic vein. To prevent injury, the median antebrachial cutaneous nerve was carefully separated from the vein. After isolating the basilic vein, a subcutaneous flap was performed, and the vein was transposed without being transected (Figure 1). The subcutaneous flap was then sutured in place between the nerve and the transposed vein on the ventral surface of the arm. If the nerve had crossed the basilic vein and could not be spared without causing injury, or if the vein length was sufficient, the basilic vein was transected at the level of the antecubital fossa and transported through a tunnel created over the deep fascia beneath the skin. Then, the vein was gently augmented with heparinized saline and anastomosed to the basilic vein stump (Figure 2). If the basilic vein diameter in the forearm is appropriate but the forearm arteries are not, the vein was exposed along its course in the forearm and its tributaries were tied before the vein was transected distally and mobilized through a subcutaneous forearm tunnel to be anastomosed to the brachial artery (end-to-side technique with

6/0 polypropylene sutures) (Figure 3). Thirty-two patients had prosthetic BG fistulas during the same study period. All grafts are made of *Polytetrafluoroethylene* (PTFE) material. The cases were discharged the day after the surgery. Postoperatively, the cases were followed up for twelve months and any procedure-linked complication or mortality was recorded. If not related to the procedure, death with a properly working fistula was regarded as a failure to follow-up. For short segment thrombosed brachial basilic AF, thrombectomy was performed with or without balloon angioplasty (PTA). But for long segment thrombosis, the fistula was abandoned. Technical success was described as the occurrence of a bruit or thrill on the arteriovenous fistula. Primary patency was described as the time at which the fistulas were functioning for hemodialysis until the time when an intervention was performed to reestablish or maintain access patency. Secondary patency was described as the time from successful access cannulation until access aban-

donment, or the patient has demised regardless of how often interventions are required to maintain patency. Overall patency was described as the patency of all HD accesses involved in this project.

Statistical analysis

Statistical analysis was performed with the SPSS for Windows version 23.0 (SPSS Inc., Chicago, IL, USA). Data were explored for normality utilizing Kolmogorov-Smirnov and Shapiro-Wilk tests. The following tests were done: independent-samples t-test of significance was utilized when comparing between two means. A chi-square (χ^2) test was also used to compare qualitative parameters' proportions. The influence of the different variables on the specific access type was analyzed using the log-rank test. P-value < 0.05 was regarded as statistically significant.

Ethical approval and consent for participation

All procedures performed in this study complied with institutional and/or national research council ethical standards as well as the 1964 Declaration of Helsinki and its subsequent amendments or similar ethical standards. Protocols and written informed consent for all participants were approved by the *Research Ethics Committee of the Faculty of Medicine for Girls, Al-Azhar University (FMG-IRB)* (approval Number: 1403/22).

RESULTS

Seventy-two patients were offered 72 AFs (47 males, 25 females), while another 32 cases (22 males, 10 females) received upper arm prosthetic BG during the same period. The mean age of the cases who received AF and upper arm AV grafts was 55 (37 to 74) and 54 (37 to 75) years, respectively. Table I displays demographic information for patients. Nondominant left upper extremities were preferred in 55 patients who received AFs (76.3%) and 22 patients who received prosthetic BG (68.7%). Different techniques were used to construct brachial cephalic AF: two-stages basilic vein elevation and transposition without re-anastomosis (22 patients), two-stages arm basilic vein

Table 1.
Patient's characteristics.

Patient's characteristics	AF group (n = 72)	Prosthetic BG fistulas (n = 32)	Test value	p-value
Age (years)				
Mean \pm SD	55.15 \pm 10.96	54.19 \pm 10.98	t = 0.414	0.680
Range	37-74	37-75		
Gender				
Female	25 (34.7%)	10 (31.3%)	$\chi^2 = 0.120$	0.729
Male	47 (65.3%)	22 (68.8%)		
Comorbidities				
IHD	25 (34.7%)	12 (37.5%)	0.075	0.785
DM	50 (69.4%)	20 (62.5%)	0.486	0.486
HTN	43 (59.7%)	16 (50.0%)	0.853	0.356

IHD: ischemic heart disease; DM: diabetes mellitus; HTN: hypertension.

transposition with re-anastomosis (28 patients), and forearm basilic vein loop transposition (22 patients). No procedure-linked mortality. Technical success was obtained in all cases (100%) (Table 1). The complication rate for AFs was (13.9%) while the complication rate for the BG-based fistulas was (34.4%). Complications of AFs requiring additional procedures to maintain patency developed in 6 patients (8.3%), including 2 patients who revealed prolonged arm swelling because of subclavian vein occlusion for which balloon angioplasty was successful to dilate one lesion and failed to treat the other because of failure of the guidewire to cross the lesion and 2 fistulas necessitating surgical thrombectomy for acute short segment thrombosis. In addition, the brachial basilic fistula was banded in 1 case with hand ischemia, and 1 case required re-exploration for postoperative bleeding. Complications of prosthetic BG-based fistulas requiring additional procedures developed in 8 cases (25%), involving 5 patients that were treated by surgical thrombectomy for acute graft thrombosis. PTA was used to dilate proximal subclavian vein stenosis in 1 patient who revealed arm swelling. Two patients who presented with postoperative bleeding were explored for control of bleeding. Access-related complications are described in Figure 4.

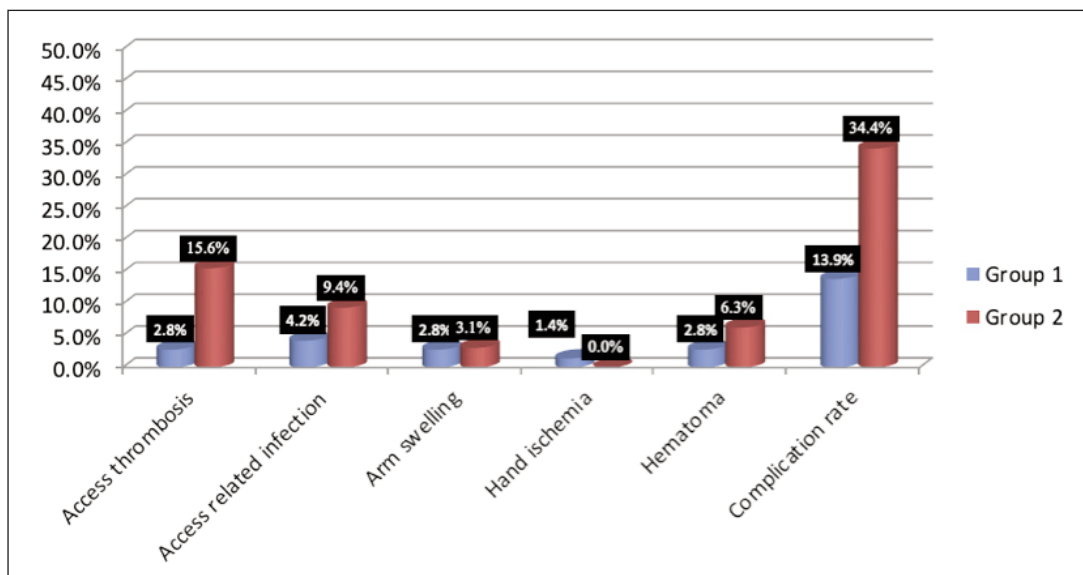


Figure 4.
Access-related complications. Group 1 represents AF patients and group 2 represents Prosthetic BG patients.

Cannulation of AF started at an average of 59 (range, 40 to 85) days after the first surgery. While cannulation of prosthetic bridging grafts started at an average of 15 (range, 14 to 20) days post-surgery. A statistically significantly higher primary patency rate was noticed for the AF in comparison to the BG-based fistulas, with a 12-months primary patency rate of 77.7% and 53.1% for AF and BG-based fistulas groups, respectively ($p < 0.012$). A similar pattern was noticed for secondary patency rates as well, with a 12-months secondary patency rate of 62.5% and 42.8% for AF and BG-based fistulas, respectively ($p = 0.063$). The AF group had a superior overall patency rate in comparison to the BG-based fistulas (84.7% and 59.3% respectively).

All patients completed 1-year follow-up.

DISCUSSION

The *Kidney Disease Outcome Quality Initiative (KDOQI)* guidelines recommended native fistulas over graft fistulas (7). The radial-cephalic fistula at the wrist was first described in 1966 and is still considered the procedure of choice because it is easy to construct, has good long-term results, and low blood flow rate so distal steal is uncommon, and nearly never results in high output cardiac failure. It also preserves the upper arm vessels for future use (8). Proximal accesses are required in some situations like patients with prior forearm AF dysfunction, and patients with a sclerosed vascular system, furthermore, if the distal veins have been subjected to repeated trauma from punctures and indwelling catheters, the radial artery, and forearm veins are deemed inappropriate for AF. Proximal accesses are easier to cannulate, have a longer vein or graft length for cannulation, have a higher blood flow with an increased chance for steal syndrome, and may result in high output cardiac failure (9). After the cephalic vein-based AF has exhausted as primary vascular access choice, the available options are a brachial basilic AF or a forearm or arm prosthetic BG-based fistula. Upper-extremity access with PTFE has been found effective, but complication rates are higher and patency rates are lower than with autologous fistulas (10). Several studies have recommended AFs over prosthetic BG-based techniques based on improved patency rates and fewer interventions (11). Furthermore, clinical practice guidelines from the USA, Australia, Canada, and the UK all recommend an AF over a prosthetic graft for chronic HD access (12). The majority of participants in this review were of working age (37-75 years old) (65%). Diabetic nephropathy was the most frequent cause of ESRD in both groups. Males are more affected by ESRD than females. These previous results are echoic to the results of other studies performed in KSA to study the prevalence of ESRD and related risk factors (13). In regards to patient demographic variables, no significant differences were detected between the two groups. Technical success was achieved in all cases. In our study, the procedure-related complication rate after AF (13.9%) was statistically significantly lower than for the upper arm prosthetic BG (34.4%). Reported results of AF showed a complication rate lower than BG because a native vein fistula is more resistant to infection than a prosthetic graft, the large-caliber basilic vein offers a high

flow rate because AF only needs one anastomosis and venous outlet stenosis can be reduced, limiting the most common problem encountered with PTFE (14, 15). The most prevalent complication in this review was access thrombosis, which was significantly more common in BG (15.6%) than in AF (2.8%) ($p = 0.062$). Early graft thrombosis was caused by a technical error, but late graft thrombosis was caused by anastomotic stenosis caused by intimal hyperplasia. More procedures were required to keep the patency of the BG-based fistulas compared to AF echoing previous results from other reports (16). Wound-related infection was not statistically significant for both groups but some studies reported an increased incidence of infection with AF as it requires longer incisions. Minimally invasive approaches like video-assisted basilic vein transposition have been used to minimize wound complications (17). Cannulation of the AF began on average 59 days after the first surgery, while cannulation of the BG began on average at 15 days, which was consistent with the *Dialysis Outcomes Quality Initiative (DOQI)* guidelines for access maturation, which state that a dialysis AV graft should not be used until 14 days after it has been placed (19). When deciding on AF, the anticipated time for maturation and cannulation should be balanced against the elevated risk of complications associated with prolonged central venous catheterization and the reduced quality of life linked with the tunneled catheter. Prosthetic BG was considered for cases with a short life expectancy and those who could not tolerate tunneled central venous catheters in place. The tunneled forearm basilic vein loop technique has the advantages of earlier cannulation, being easily accessible, and preserving the proximal portion of the basilic vein for future use. When compared to BG, AF procedures had higher primary, secondary, and overall patency rates. Previous studies reported higher primary patency rates of AF, ranging from 65 to 70% at one year and 49 to 51% at two years (19). A limitation of the article is the small sample size and also a smaller representation of the forearm BB AVG group.

CONCLUSIONS

Brachial basilic AF is a technically successful procedure with higher patency rates and lower operative complication rates than prosthetic BG. Furthermore, if the AF fails and the venous outflow is open, there is a chance that BG could be used in the future at the same site. We suggested that for patients with failed forearm dialysis fistulas and no adequate cephalic vein, a brachial basilic fistula be regarded as an alternative to prosthetic graft insertion. Patients with a short life expectancy or those who are unable to tolerate tunneled central venous catheters should consider prosthetic BG.

REFERENCES

1. Maaz Abbasi, Glenn M Chertow, and Yoshio N Hall. End-stage renal disease. *BMJ*. 2010; 7:1-16.
2. Michael B. Silva, JR and Brajesh K.LAL. Decision making in vascular surgery by Jack L. Cronenwett, and Robert B. Rutherford. Copyright 2001. Chapter 72:354-359.

3. Kherlakian GM, Roedersheimer LR, Arbaugh JJ, et al. Comparison of autogenous fistula versus expanded polytetrafluoroethylene graft fistula for angioaccess in hemodialysis. *Am J Surg.* 1986; 152:238-243.
4. Vascular Access Work Group, "Clinical practice guidelines for vascular access," *Am J Kidney Dis.* 2006; 48:248-273.
5. Oliver MJ, McCann RL, Indridason OS, Butterly DW. Comparison of transposed brachio basilic fistulas to upper arm grafts and brachiocephalic fistulas. *Kidney Int.* 2001; 60:1532-1539.
6. Hakaim AG, Nalbandian M, Scott T. Superior maturation and patency of primary brachiocephalic and transposed basilic vein arteriovenous fistulae in patients with diabetes. *J. Vasc. Surg.* 1998; 27:154-157.
7. Oliver MJ, McCann RL, Indridason OS, et al. Comparison of a transposed brachio basilic fistula to upper arm grafts and brachiocephalic fistulas. *Kidney Int* 2001; 60:1532-1539.
8. Brescia MJ, Cimino JE, Apple K, Hurwich BJ. Chronic hemodialysis using venipuncture and a surgically created arteriovenous fistula. *N Engl J Med.* 1966; 275:1089-1092.
9. Bender MHM, Bruyninckx CMA, Gerlag PGG. The brachiocephalic elbow fistula: a useful alternative angioaccess for permanent hemodialysis. *J Vasc Surg.* 1994; 20:808-813.
10. Kherlakian GM, Roedersheimer LR, Arbaugh JJ, et al. Comparison of autogenous fistula versus expanded polytetrafluoroethylene graft fistula for angioaccess in hemodialysis. *Am J Surg.* 1986; 152:238-2343.
11. Benedetto BJ, Madden RL, Kurbanov A, Lipkowitz GS. Transposed basilic vein fistula: a superior alternative to prosthetic grafts? *Curr Surg.* 2000; 57:503-504.
12. M.A. Frances D, Yufan LU, Amanda J. Robertson, Robert J. Millar and Jayne Amy. Two-stage brachio basilic arteriovenous fistula for chronic hemodialysis access. *ANZ J. Surg.* 2007; 77:150-151.
13. Hussain Gadelkarim Ahmed, Tahani Altamimi. Survey for potential risk factors for susceptibility to chronic kidney disease in Hail region, in KSA. *Management in health XVII/122013*; pp. 31-36.
14. Kumar A, Sinha S, Sharma AK. Long-term results of arteriovenous fistulas using transposed autologous basilic vein. *Br J Surg.* 2000; 87:1735-1736.
15. Taghizadeh A, Dasgupta P, Khan MS, et al. Long-term outcomes of brachio basilic transposition fistula for hemodialysis. *Eur J Vasc Endovasc Surg.* 2003; 26:670-672.
16. Sgroi MD, Patel MS, Wilson SE, et al. The optimal initial choice for permanent arteriovenous hemodialysis access. *J Vasc Surg.* 2013; 58:539-548.
17. Hayakawa K, Tsuha M, Aoyagi T, et al. New method to create a vascular arteriovenous fistula in the arm with an endoscopic technique. *J Vasc Surg.* 2002; 36:635-638.
18. Chieh-Hung Lee, Po-Jen Ko, Yun-Hen Liu, et al. Brachio basilic Fistula as a Secondary Access Procedure: An Alternative to a Dialysis Prosthetic Graft. *Chang Gung Med J.* 2004; 27:816-23.
19. Murphy GJ, White SA, Knight AJ, et al. Long-term results of arteriovenous fistulas using transposed autologous basilic vein. *Br J Surg.* 2000; 87:819-23.

Correspondence

Ehab M. Abdo, MD
ehababdo48@yahoo.com

Waleed E. Elshinawy, MD
waleed.elshinay82@gmail.com

Nehal Farouk, MD
dr.nehalfarouk@yahoo.com

Department of Vascular Surgery, Faculty of Medicine, Al-Azhar University, Cairo, Egypt

Tamer A. Abouelgreed, MD (Corresponding Author)
dr_tamer_ali@yahoo.com

tamerali.8@azhar.edu.eg

Mohamed A. Abdelaal, MD

maal_uro@yahoo.com

Hassan Ismail, MD
drhassan_ismail@yahoo.com

Department of Urology, Faculty of medicine, Al-Azhar University, Cairo, Egypt

Amal H. Ibrahim, MD

mkellany@yahoo.com

Samar A. Kasem, MD
summerahmed1983@yahoo.com

Department of Internal Medicine, Nephrology Unit, Faculty Medicine, Al-Azhar University, Cairo, Egypt

Ahmed A. Aboomar, MD

ahmed_abo_omar12@yahoo.com

Department of Internal Medicine, Nephrology Unit, Faculty Medicine, Tanta University, Tanta, Egypt

Conflict of interest: The authors declare no potential conflict of interest.