

Frequency of agenesis of Palmaris Longus muscle in medical students of Faisalabad

Quddus Ur Rehman, Usman Latif, Faiqa Haris, Faiza Liaqat

ABSTRACT

Objective: To find out frequency of agenesis of palmaris longus (PL) of medical students of Faisalabad.

Methodology: This cross-sectional study was conducted from 1st to 31st October 2019 at the anatomy department of a private medical college of Faisalabad. Two hundred and two medical students of age ranging from 18-22 years were evaluated for agenesis of PL by standard Schaeffer's test. Findings were confirmed by Thompson's test, Pushpakumar's "two-finger sign" method, Mishra's test I, and Mishra's II test. Data was analyzed by SPSS version 21. Frequencies and percentages for PL agenesis were obtained and compared by chi square test. p value ≤ 0.05 was considered to be significant.

Results: The PL muscle was present in 155 students (76.3%). The frequency of agenesis was noted in 47 students (23.6%). Bilateral agenesis was seen in 16 students (7.9%) while 31 subjects (15 %) had unilateral agenesis.

Twenty-nine (29.5%) male students had agenesis of palmaris longus. Out of which bilateral and unilateral agenesis found in 7 (6.8%) and 22 (21%) male students respectively. In comparison to this 18 (17.3%) female students had agenesis of palmaris longus. Out of which bilateral and unilateral agenesis found in 9(8.6%) and 9(8.6%) female students respectively.

Conclusion: Unilateral agenesis of PL is more common than bilateral agenesis. Agenesis of PL is more frequent in males as compared to females.

KEYWORDS: Palmaris longus muscle, Agenesis, Schaeffer's test.

INTRODUCTION

The palmaris longus (PL) is a slender, most variable fusiform superficial flexor muscle of the anterior compartment of forearm. It originates at the medial epicondyle of the humerus and inserts into the palmar aponeurosis through its long tendon.¹ Palmaris longus is considered to be a tensor of palm's subcutaneous tissue. It serves as an anchor of skin and fascia and tenses palmar aponeurosis to resist horizontal shearing forces. PL is supplied by median nerve and branches of ulnar artery.² Various studies show structural variations in palmaris longus from unilateral or bilateral agenesis, merging with other muscles, presence of an accessory muscle belly to multiple insertion points etc. Different

common reason for median and ulnar nerve compression due to its relationship with these nerves. Developmental pathways of the PL might be responsible for morphological variation of the muscle in adults.³ The anatomical variation in morphology in Multiple studies show that its abnormal positioning causes Carpel Tunnel syndrome.^{4,5} When palmaris longus enters in Guyon's canal, it causes compression of ulnar artery and nerve leading to Guyon Canal syndrome.⁶ The tendon of palmaris longus is an important landmark for palm access in treatment of Carpal Tunnel syndrome. It is also an important landmark for distal radial fracture.⁶ Furthermore, It is a perfect choice for grafts in reconstructive, plastic and cosmetic surgeries due to its retrogressive characteristics having short belly and long tendon.⁷ The graft of the tendon has no effect on the functionality of the upper limb⁷, as people with absence of this muscle reported no functional disability. However, its presence plays a noteworthy role in reconstructive plastic surgery as a donor tendon for grafting.^{7,8}

Objectives: To find out frequency of agenesis of palmaris longus (PL) of medical students of Faisalabad.

METHODOLOGY

This cross-sectional study was conducted in the Anatomy department of Faisalabad based private

Dr. Quddus Ur Rehman, MBBS, FCPS
Professor Anatomy
Aziz Fatimah Medical and Dental College, Fsd
Dr. Usman Latif, MBBS, FCPS
Professor Anatomy
Aziz Fatimah Medical and Dental College, Fsd
Dr. Faiqa Haris, MBBS
Demonstrator Anatomy
Aziz Fatimah Medical and Dental College, Fsd
Dr. Faiza Liaqat, MBBS
Demonstrator Pharmacology
Independent Medical College, Fsd

Correspondence:

Dr. Faiqa Haris
Email: drfqharis@gmail.com

Medical & Dental College. The study was conducted from 1st to 31st October 2019 after taking ethical approval from institutional ethical committee (IEC/774-19). The male and female students of age ranging 18-22 years were included in the study. Two hundred and two participants were recruited by convenient sampling technique. Students who had history of any injury to hand & forearm, contracture of forearm muscles, any disability of hand or forearm and any surgery on forearm or hand were excluded from the study. After explaining the objective of study and taking informed consent, medical students were examined for presence or absence of PL tendon initially by the Schaeffer's Test (standard technique) and later on the findings were confirmed by four additional tests explained below and the results were recorded.

Schaeffer's test : was performed by asking the subject to oppose his/her thumb against the little finger and then flexing his/her wrist against resistance⁹.

Thompson's test was performed by asking the subject to make his/her hand fist and then flexing the wrist and then finally the thumb is opposed and flexed over the fingers.¹⁰

Mishra's test I test, all metacarpophalangeal joints are passively hyperextended by the examiner then the subject is asked to actively flex his wrist.

Mishra's test II was performed by asking the subject to abduct the thumb against resistance while keeping the wrist in slight palmar flexion.¹¹

Pushpakumar's "two-finger sign" method was done by asking the subject to fully extend the index and middle finger, then wrist and other fingers were asked to flexed and finally the thumb was asked to fully opposed and flexed.¹¹ All above mentioned tests are based on making the tendon taut by eliciting its weak flexor action and making PL prominent, leading to its recognition visually and by palpation.⁹

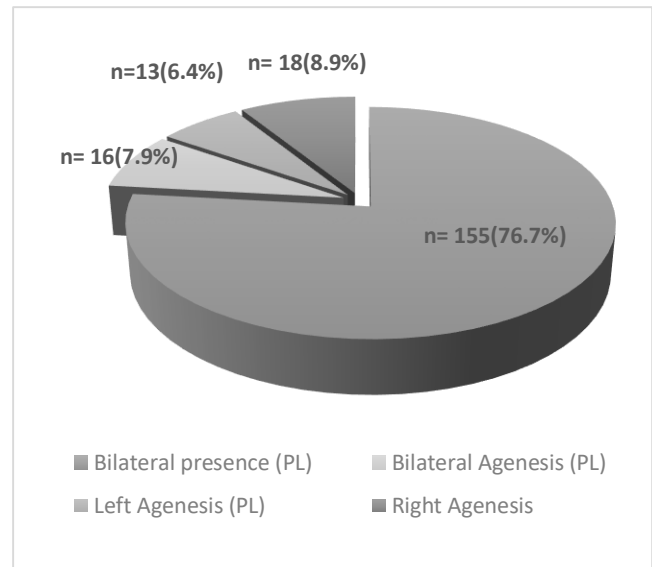
Statistical analysis was done using SPSS version 21. The frequencies and percentages of unilateral or bilateral PL agenesis were presented with a 95% confidence interval. The association between absence of the palmaris longus, body side and sex were assessed using chi-square test. Statistical significance was set at $P < 0.05$.

RESULTS

The study involved 202 subjects. There were 98 males and 104 females with age range of 18-22 years. Out of a total 202 students examined, PL of both sides were present in 155 subjects (76.7%) while 47 (23.3%) had PL agenesis. Out of these 47 subjects, bilateral agenesis was found in 16 (7.9%) while 31 (15%) had unilateral agenesis. On further analysis of unilateral agenesis, 13

(6.4%) had left sided agenesis while 18 (8.9%) had right sided agenesis (Figure 1).

Figure 1: Morphological Variation of Palmaris Longus Muscle in study population (n=202).



Hence, agenesis was more common on the right side as compared to the left, and difference was statistically significant ($p = 0.05$) (Table 1). Overall, male subjects had frequency of agenesis of palmaris longus tendon (unilateral & bilateral combined) of 29 out of 98 (29.5%), while in female subjects, frequency was 18 out of 104 (17.3%). The pattern for absence of PL was different in both genders. Males had 22 (21.5%) unilateral agenesis and only 7 (7.1%) had bilateral agenesis. While 9 (8.6%) females had unilateral agenesis and similarly 9 (8.6%) had bilateral agenesis of PL (Table 1).

DISCUSSION

The palmaris longus (PL) is one of the most variable muscles in the human body and its agenesis among different populations have been reported by various previous studies.⁹ PL is clinically important for the surgeons. It is required as a tendon graft for reconstructive surgery including correction of ptosis, lip augmentation, management of facial nerve palsy.¹² It is also used as a tendon transfer for opponensplasty in restoring the intrinsic functions in cases of recurrent median nerve injury.¹³ In present study, overall agenesis of PL muscle in both genders was 23.3%. Our results are justified by a study conducted on multiracial medical students including Chinese, Indians and Malays at the University of

Table 1. Frequencies of Palmaris Longus Agenesis Muscle according to Gender and laterality (n=202)

Palmaris Longus Muscle	Gender		Total (%) (n=202)	P value
	Male (%) (n=98)	Female (%) (n=104)		
Left Agenesis	10 (10.2%)	3 (2.9%)	13 (6.4%)	0.05*
Right Agenesis	12 (12.2%)	6 (5.8%)	18 (8.9%)	
Bilateral Agenesis	7 (7.1%)	9 (8.6%)	16 (7.9%)	
Bilateral presence	69 (70.4%)	86 (82.7%)	155 (76.7%)	

Malaya, Malaysia that reported a diversity in the ranges of incidence of absence of PL among various races. Aforementioned study has reported a higher incidence of unilateral and bilateral PL absence in medical students from India than any other races.¹⁴ Contrary to the current results numerous previous studies reported lower prevalence of 3.4-4.6% in other Asian population including Japanese and Chinese.¹¹ 6.7% of PL agenesis was documented in Yoruba ethnic population that is the largest ethnic groups in Africa.¹¹ Another Malaysian study reported 11.7% of agenesis of PL in Malay Population.¹⁵ Highest prevalence of 50% agenesis of PL was reported in Egyptian population, that is highest rates of absence of PL than any other ethnic groups in the world.¹⁶ Contradictory to current results lowest percentage of 1.5% was reported in Zimbabwean population.¹² Large variability in documentation concerning PL agenesis by all abovementioned studies proved that the prevalence of agenesis is ethnically determined. Present study found that the unilateral agenesis of PL was more common than bilateral agenesis in our study population (15% Vs 7.9%). PL was frequently absent in the right limb in our study participants. Contradictory to our findings Osonuga et al reported absence of PL in left side that is non dominant hand, on the other hand some researchers have documented bilateral agenesis being more common.^{12,13} Our findings showed significantly higher frequency of agenesis of palmaris longus in men than

in women (29.5 % vs 17.3%). On comparison of laterality of agenesis of PL among the gender, we noted that unilateral agenesis of right-side PL is more common than bilateral PL agenesis in male. In females unilateral and bilateral agenesis was found in equal proportions. Our results are not in line with other previous studies that reported frequent absence of PL in females than males. Recent Past study conducted in Kashmir reported prevalence of absence of PL in 12.1% in females and 6.7% in males, furthermore this Kashmiri study found that bilateral agenesis was common than unilateral PL agenesis.¹⁷ An Indian study also documented higher prevalence of PL agenesis in females as compared to male population (40.2% vs 14.7%) and unilateral being more common than bilateral PL agenesis.¹⁸ Results of current study add to the literature and reaffirm the previous studies that the absence of PL depends on race and ethnicity. Epidemiological studies on a broader scale should be conducted for evaluation of ethnically based anatomic variation in PL tendon, which has a clinical and surgical importance.

Limitations: Agenesis of PL is only determined by clinical examination rather than by CT or MRI. Results cannot be generalized to the whole population due to small sample size and single center study.

CONCLUSION

Unilateral agenesis is more common than bilateral agenesis. Agenesis of PL is more frequent in males as compared to females.

Suggestion: To confirm the correct anatomic facts, further studies on wider scale are required.

Funding Source: None.

Conflicts of Interest: None.

REFERENCES

1. Dąbrowski K, Stankiewicz-Jóźwicka H, Kowalczyk A, Markuszewski M, Cizek B. The sonographic morphology of musculus palmaris longus in humans. *Folia Morphol (Warsz)*.2018;77(3):509-513. doi:10.5603/FM.a2017.0116.
2. Longhurst G, Stone D, Mahony N Bilateral reversed palmaris longus muscle: a case report and systematic literature review. *SurgRadiol Anat*. 2020 Mar;42(3):289-295. doi: 10.1007/s00276-019-02363-z. Review
3. Olewnik Ł, Waśniewska A, Polgaj M, Podgórski M, Łabętowicz P, Ruzik K, et al Morphological variability of the palmaris longus muscle in human fetuses. *Surg Radiol Anat*.2018 (11):1283-1291. doi:10.1007/s00276-018-2069-2

4. Olewnik Ł, Wysiadecki G, Polguy M, Podgórski M, Jezierski H, Topol M. Anatomical variations of the palmaris longus muscle including its relation to the median nerve - a proposal for a new classification. *BMC Musculoskelet Disord.* 2017 ;18(1):539. doi:10.1186/s1289-017-1901-x.
5. Kumar N, Patil J, Swamy RS, Shetty SD, Abhinitha P, Rao MK, et al. Presence of multiple tendinous insertions of palmaris longus: a unique variation of a retrogressive muscle. *Ethiop J Health Sci.* 2014 Apr;24(2):175-8.
6. Sunil V, Rajanna S, Gitanjali KJ. Variation in the insertion of the palmaris longus tendon. *Singap Med J.*2015;56:e7 – <https://sma.org.sg/UploadedImg/files/SMJ/5601/5601cr3.pdf> (date of access 9 May2020).
7. Mathew AJ, Sukumaran TT, Joseph S Versatile but temperamental: a morphological study of palmaris longus in the cadaver. *J Clin Diagn Res.* 2015 Feb;9(2):AC01-3. doi: 10.7860/JCDR/2015/11212.5542.
8. Cetin A, Genc M, Sevil S, Coban YK. Prevalence of the palmaris longus muscle and its relationship with grip and pinch strength: a study in a Turkish pediatric population. *Hand. Hand (N Y).* 2013;8(2):215-20. doi:10.1007/s11552-013-9509-6.
9. Shenoy RM. Two new clinical tests for palmaris longus. *Indian J Plast Surg.* 2018;51(3):321-323. doi:10.4103/ijps.IJPS_105_18.
10. Dimitriou I, Katsourakis A, Natsis K, Kostretzis L, Noussios G Palmaris Longus Muscle's Prevalence in Different Nations and Interesting Anatomical Variations: Review of the Literature. *J Clin Med Res.* 2015;7(11):825-830. doi:10.14740/jocmr2243w. Review. Erratum in: *J Clin Med Res.* 2016 Jan;8(1):62.
11. Mbaka GO, Ejiwunmi AB Prevalence of palmaris longus absence--a study in the Yoruba population. *Ulster Med J.* 2009;78(2):90-93.
12. OsonugaA , Mahama HM, Brown AA, Osonuga OA, Serbeh G, Harding AN, et al. The prevalence of palmaris longus agenesis among the Ghanaian population. *Asian Pac J Trop Dis.* 2012;2(Supplement 2):S887-89.
13. Ali M. Soltani,1 Mirna Peric,1 Cameron S. Francis,1 Thien-Trang J. Nguyen,1 Linda S. etal. The Variation in the Absence of the Palmaris Longus in a Multiethnic Population of the United States: An epidemiological Study. *Plast Surg Int.*2012;2012:282959. doi:10.11555/2012/282959.
14. Kassim, N.M., Zulkafli, I.S., Zamin, R.M. et al. The Incidence of Agenesis of Palmaris Longus Muscle Among Multiracial Medical Students of University Malaya, Malaysia. *Indian J Surg.* 2019. <https://doi.org/10.1007/s12262-019-02026-8> (date of access: 2nd May2020).
15. Yong MW, Yusof N, Rampal L, Arumugam M. Prevalence of Absence of Palmaris Longus and Its Association with Gender, Hand Dominance and Absence of FDS Tendon to Little Finger Among Malay Population. *J Hand Surg Asian Pac Vol.* 2017 Dec;22(4):484-489. doi:10.1142/S021881041750054X.
16. Raouf HA, Kader GA, Jaradat A, Dharap A, Fadel R, Salem AH. Frequency of palmaris longus absence and its association with other anatomical variations in the Egyptian population. *Clin Anat.* 2013 ;26(5):572-7. doi: 10.1002/ca.22186
17. Kkhan MJ , Shafi MS, Shoukat A, Ahmed KA, Azad S, Ayub MZ et al. Prevalence of Absence of Palmaris Longus Muscle in Kashmiri Population. *JRMC.* 2016; 20(2):124-128.
18. Sankar KD, Bhanu PS, John SP. Incidence of agenesis of palmaris longus in the Andhra population of India. *Indian J Plast Surg.*2011;44(1): 134-138. doi: 10.4103/0970-0358.81448.

Author's Contribution:

Dr. Quddus Ur Rehman	Study design and data collection, manuscript writing, and accountable for research work.
Dr. Usman Latif	Study design and data collection, critically revision of the manuscript and approve the final version. Accountable for research work.
Dr. Faiqa Haris	Data collection, manuscript writing, revision and approval of final version.
Dr. Faiza Liaqat	Statistical analysis, interpretation of results, critically revise and approve the manuscript

All authors are equally accountable for material provided.

Received: 10 Nov 2019, Revised received: 20 Dec 2019, Accepted: 1 Jan, 2020.