

CASE REPORT

Simultaneous Occurrence of Dysrhythmia and Seizure as a Diagnostic Difficulty; a Case Report

Forod Salehi¹, Hamidreza Riasi², Hamideh Riasi³, Arvin Mirshahi^{4*}

1. Cardiovascular Diseases Research Center, Department of Pediatrics, Vali-e-Asr Hospital, Birjand University of Medical Sciences, Birjand, Iran.

2. Department of Neurology, Vali-e-Asr Hospital, Birjand University of Medical Sciences, Birjand, Iran.

3. Vali-e-Asr Hospital, Birjand University of Medical Sciences, Birjand, Iran.

4. Student Research Committee, Birjand University of Medical Sciences, Birjand, Iran.

Received: June 2018; Accepted: July 2018; Published online: 8 August 2018

Abstract: Torsades de pointes (TdP) is a rare but hazardous ventricular dysrhythmia caused by an increase in the QT interval of the heart rhythm and is categorized into congenital or acquired types. Signs and symptoms of TdP include syncope, seizure, ventricular fibrillation, and even sudden death. According to statistics, among these symptoms, syncope and the seizure can be considered as signs that make the TdP diagnosis difficult. Here, we present an infant referring to Vali-e-Asr Hospital in Birjand with frequent seizures and aspiration pneumonia. She was diagnosed with Torsades de Pointes and a medium-sized patent ductus arteriosus, and subsequently underwent a patent ductus arteriosus ligation.

Keywords: Torsade de Pointes; seizures; ductus arteriosus, patent; infant

© Copyright (2018) Shahid Beheshti University of Medical Sciences

Cite this article as: Salehi F, Riasi H, Riasi H, Mirshahi A. Simultaneous Occurrence of Dysrhythmia and Seizure as a Diagnostic Difficulty; a Case Report. *Emergency*. 2018; 6 (1): e49.

1. Introduction:

Torsades de Pointes (TdP) is polymorphic ventricular tachycardia (VT) that occurs in the setting of a long-QT interval (QT > 440 ms) and is characterized by a waxing and waning QRS amplitude(1). Among the factors that can contribute to increased QT interval and TdP incidence in patients are female sex, electrolyte disorders such as hypokalemia, hypomagnesaemia and hypocalcaemia, digitalis consumption, congestive heart failure and heart diseases, excessive or unbalanced consumption of some cardiovascular and non-cardiac drugs, cocaine abuse, as well as genetic problems such as abnormalities in cardiac ion channels such as sodium and potassium channels(2-6). In these patients, certain genetic tests are performed on the patient and his/her family to diagnose the cause of this dysrhythmia. Several clinical panels, in addition to electrocardiogram

examination, can be found in patients with TdP, which can include heart palpitation, syncope, and seizure (7, 8). In the following case, we study an infant who was referred to Vali-e-Asr Hospital in Birjand with frequent seizures and aspirations and was diagnosed with TdP and a medium-sized patent ductus arteriosus (PDA) and subsequently underwent a reconstructive surgery.

2. Case presentation:

The case was a 15-month-old infant girl weighing 10 kg who was referred to Vali-e-Asr Hospital, Birjand, Iran, as a result of severe respiratory distress and seizure. At the time of visiting the residency hospital, the infant had an apnea and a heart attack, for which a cardiac massage was performed and the patient was referred to Birjand city due to an aspiration pneumonia and seizure. Physical examination of the height and weight indicated normal development and head circumference.

According to the statements of the patient's companion, the infant had suffered from seizures several times, one of which occurred at the emergency room and was characterized by

*Corresponding Author: Arvin Mirshahi; Student Research Committee, Birjand University of Medical Sciences, Birjand, Iran. Email: mirshahi-arvin13750@gmail.com Tel: 00989394212442



cyanosis in the face and lips. Considering the examinations performed in the emergency department showing 50% O₂ saturation without oxygen therapy, reduced consciousness in the patient, and the information from history, the patient was diagnosed with seizure and was accordingly transferred to pediatric intensive care unit (PICU) with cardiac monitoring.

After a few hours of monitoring, the patient suffered repeated VT attacks (Fig 1). Therefore, medication was infused within 20 minutes, including 500 mg magnesium sulfate and 10 mg lidocaine, and VT was discontinued. Furthermore, conduction of a 24-hour Holter electrocardiography (ECG) and echocardiography were put on the agenda. Contrary to expectations, after taking antiarrhythmic drugs two days after the first arrhythmia and VT, the patient again suffered arrhythmia as repeated PVC followed by VT; therefore, lidocaine and magnesium sulfate were administered. However, even despite the 20-minute infusion of these two drugs, VT did not stop. Finally, 50 mg of amiodarone was administered in 30 minutes with a D2 long check before and after the infusion.

After a 24-hour Holter ECG monitoring, long QT intervals (QT = 490 ms) and VT were observed (Fig 2). Given the indication of the occurrence of TdP in the patient, treatment with beta-blockers (propranolol) was initiated and all other anti-arrhythmic drugs were discontinued. Ultimately, arrhythmia of the patient was completely controlled. Furthermore, the patient's echocardiography showed left atrial enlargement, left ventricular enlargement, left-to-right shunt, and PDA with a mean diameter of 4 mm.

Also, all values were within the normal range in terms of patient-requested tests, including CBC (Complete Blood Count), sodium, potassium, calcium, magnesium, Blood Urea nitrogen (BUN), creatinine, Free T₄, thyroid-stimulating hormone (TSH), and Venous Blood Gas (VBG). Given the size of the PDA, surgery was subsequently proposed for the infant, and the patient underwent thoracotomy and PDA ligation whereby the patient's PDA was closed. Propranolol was discontinued and not used over the course of 6-month, one-year, and two-year periodic follow-ups, and the patient was asymptomatic. Also, a list of the drugs that contributed to the arrhythmia was given to the patient to avoid consumption.

3. Discussion

In some heart diseases, loss of consciousness has movements similar to seizures that can be indicated in clinical examinations. It is believed that the appearance of these symptoms, due to the transient cerebral hypoxia in these patients, results from a temporary reduction of the cardiac output (9, 10). According to recent studies, the probability of misdiag-

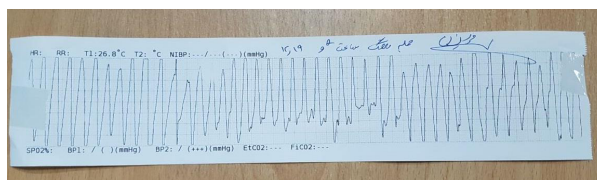


Figure 1: Electrocardiogram trace of the patient when dysrhythmia occurred (Torsade de Pointes).

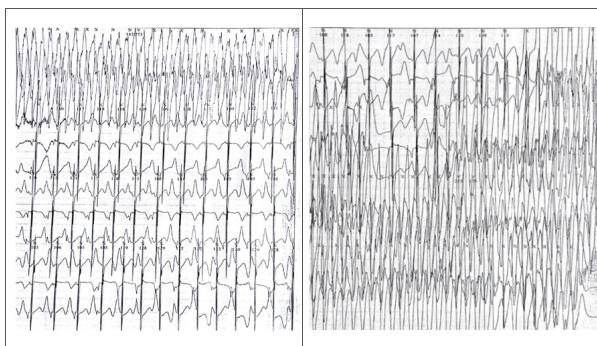


Figure 2: 24-hour-ECG Holter monitoring with long QTC showing polymorphic ventricular tachycardia (Torsade de Pointes).

nosis of seizure for a patient is 20%, and cardiovascular factors including syncope and arrhythmias are often neglected in these cases, indicating the difficulty of differential diagnosis of seizure and TdP in clinical examinations (11-14). Therefore, ECG and cardiac monitoring are advisable in people who have had seizures for the first time. Also, taking a precise history of the patient, a family history of premature death under 30 years of age, observation and clinical examination, and the use of ECG can be helpful in the differential diagnosis of seizures and seizure-induced cardiovascular diseases (13).

Moreover, since many drugs are involved in TdP incidence, it is therefore necessary to be mindful of prescribing drugs for individuals with a possibility of misdiagnosis. It is also necessary to check the history of TdP stimulant drugs in this group. In case of unavoidable use of TdP stimulant drugs, it will provide a more accurate assessment if a set of measures are taken, including a baseline assessment and a 12-lead ECG, detailed examination at different times of the day, and/or Holter monitoring in cases with high possibility of TdP incidence. It will be helpful for the patient to provide a list of precautionary measures and risk factors (including QT interval prolongers) and to prohibit him/her from using similar drugs that can increase the QT interval. Moreover, preventing other contributors to increased QT interval such as electrolyte disorders in these patients is very important (5, 15).

Given the fact that our case was a candidate for PDA closure, careful consideration was given to use of medications dur-

ing surgery. The anesthesiologist and the surgical team were provided with information to prevent the use of prolonged QT medications and recurrent VT attacks during surgery. Moreover, regarding the results of genetic tests in patients, it should be noted that in 80% of the trials, those having matched clinical features have a confirmed genetic disorder. Despite recommendations given to the parents of our case, these tests were not performed on the patient. Moreover, if mutations are confirmed in the series of genes examined in this regard, it is necessary to perform these tests on other family members of the patient, who are asymptomatic. Should the tests be positive, the family members should take precautions in terms of taking medications and paying more attention to certain signs, such as seizures and syncope (8).

4. Conclusion:

The incidence of arrhythmias in children is uncommon, and when occurring, they may present with misleading signs. Therefore, the familiarity and mental preparedness of general practitioners and pediatricians with these diseases seem necessary in order to prevent fatal consequences with rapid diagnosis and timely treatment.

5. Appendix

5.1. Acknowledgements

We express our gratitude to colleagues in the pediatric ward of Vali-e-Asr Hospital and the patient's parents who collaborated with us in data collection.

5.2. Author's contribution

ES managed the patient. H.R and H.R followed the patient and wrote the draft. AM completed, revised and approved the article.

5.3. Conflict of interest

Authors have no conflict of interest.

5.4. Funding

None.

References

1. Al-Khatib SM, Stevenson WG, Ackerman MJ, Bryant WJ, Callans DJ, Curtis AB, et al. 2017 AHA/ACC/HRS Guideline for Management of Patients With Ventricular Arrhythmias and the Prevention of Sudden Cardiac Death: A Report of the American College of Cardiology/American Heart Association Task Force on Clinical Practice Guidelines and the Heart Rhythm Society. *Journal of the American College of Cardiology*. 2017;24390.
2. Makkar RR, Fromm BS, Steinman RT, Meissner MD, Lehmann MH. Female Gender as a Risk Factor for Torsades de Pointes Associated With Cardiovascular Drugs. *JAMA: The Journal of the American Medical Association*. 1993;270(21):2590-7.
3. Roden DM. Drug-Induced Prolongation of the QT Interval. *New England Journal of Medicine*. 2004;350(10):1013-22.
4. Salehi F, Taheri MMH, Riasi H, Mehrpour O. Recurrent syncope following substance abuse; a case report. *Emergency*. 2017;5(1).
5. Yap YG, Camm J. Risk of torsades de pointes with non-cardiac drugs. *British Medical Journal*. 2000;320(7243):1158-9.
6. Gowda RM, Khan IA, Wilbur SL, Vasavada BC, Sacchi TJ. Torsade de pointes: The clinical considerations. *International Journal of Cardiology*. 2004;96(1):1-6.
7. Itoh H, Crotti L, Aiba T, Spazzolini C, Denjoy I, Fressart V, et al. The genetics underlying acquired long QT syndrome: Impact for genetic screening. *European Heart Journal*. 2016;37(18):1456-64.
8. Kliegman R, Stanton B, St Geme JW, Schor NF, Behrman RE. *Nelson textbook of pediatrics* Edition 20 ed: Philadelphia, PA : Elsevier, [2016]; 2016.
9. Lempert T, Bauer M, Schmidt D. Syncope: a videometric analysis of 56 episodes of transient cerebral hypoxia. *Annals of neurology*. 1994;36(2):233-7.
10. Baratloo A, Rouhipour A, Forouzanfar M, Rahmati F, Hashemi B. Hypokalemia-induced abnormal movements: case report. *Trauma monthly*. 2013;18(3):141-4.
11. Sabu J, Regeti K, Mallappallil M, Kassotis J, Islam H, Zafar S, et al. Convulsive syncope induced by ventricular arrhythmia masquerading as epileptic seizures: case report and literature review. *Journal of clinical medicine research*. 2016;8(8):610.
12. Scheepers B, Clough P, Pickles C. The misdiagnosis of epilepsy: findings of a population study. *Seizure*. 1998;7(5):403-6.
13. Smith D, Defalla B, Chadwick D. The misdiagnosis of epilepsy and the management of refractory epilepsy in a specialist clinic. *Qjm*. 1999;92(1):15-23.
14. Angus-Leppan H. First seizures in adults. *BMJ*. 2014;348:g2470.
15. Isbister GK. Risk assessment of drug-induced QT prolongation. *Australian prescriber*. 2015;38(1):20.

