

## PHOTO QUIZ

## An 88-Year-Old Man with Sudden Onset Abdominal Pain

Mohammad Manouchehrifar, Soheil Soltani\*, Sona Ziaei

Department of Emergency Medicine, Loghmane Hakim Hospital, Shahid Beheshti University of Medical Sciences, Tehran, Iran.

\*Corresponding Author: Soheil Soltani; Department of Emergency Medicine, Loghmane Hakim Hospital, Shahid Beheshti University of Medical Sciences, Tehran, Iran. Tel: +989122196632; Email: Soheil\_soltani@yahoo.com

Received: February 2015; Accepted: March 2015

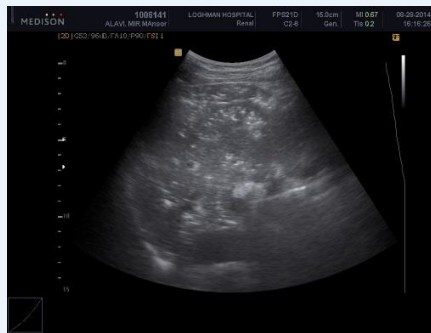

Figure 1: US imaging of patient's liver.

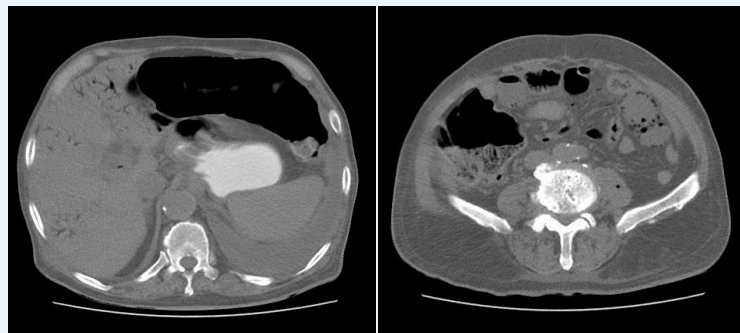


Figure 2: Axial abdominal CT scan of patients.

US: Ultrasonography; CT: Computed tomography

**Cite this article as:** Manouchehrifar M, Soltani S, Ziaei S. An 88-year-old man with sudden onset abdominal pain. *Emergency*. 2015;3(3):125-6.

**Case presentation:**

An 88-year-old man presented to the emergency department with sudden onset of abdominal pain since 6 hours before. He described his pain as an epigastric pain that had become generalized without any radiation. The pain was persistent and aggravated by meal. It was associated with nausea but not with vomiting, diarrhea, hematochezia, hematemesis or dysuria. He was a known case of chronic renal failure that underwent hemodialysis three times a week. He also suffered from hypertension and benign prostatic hyperplasia. The patient was under treatment with aspirin, atorvastatin, furosemide, finasteride, and tamsulosin. He did not use cigarette, opium or alcohol. The patients' on-arrival vital signs were as follows: systolic blood pressure: 100/60 mmHg, pulse rate: 88/minute, respiratory rate: 25/minute, oral temperature: 36°C, oxygen saturation 93% in room air. He had severely ill appearance on admission. Lungs and heart auscultation was normal. Distended abdomen was considerable but had normal bowel sound and

clearly, pain was disproportionate to physical examination. Rectal examination was unremarkable. Pitting edema was observable on his lower limbs; however, symmetric peripheral pulses were detected. His electrocardiogram showed sinus rhythm and venous blood gas analysis revealed the following: pH=6.96, PaCO<sub>2</sub>=49 mmHg, HCO<sub>3</sub>=11 mEq/L, Base excess= -20. By reviewing the biochemistry profile only urea=180 mg/dL and creatinine=4.8 mg/dL were notable and all others such as amylase, lipase, and liver function tests were reported in normal range. The bedside ultrasonography showed echogenic particles in hepatic parenchyma and same findings that were passing through the portal vein (Figure 1). Chest and abdominal X-rays were reported as normal. The patient underwent abdominal and pelvic computed tomography (CT) scan with oral contrast that showed in Figure 2.

**What is your diagnosis?**

**Diagnosis:**

Air in portal vein and its branches combined with air in intestinal wall that all are consistent with diagnosis of mesenteric ischemia and pneumatosis intestinalis.

**Case fate:**

The patient admitted to the intensive care unit because of severe acidosis and worsening hemodynamic, but died after 3 days.

**Discussion:**

Abdominal pain is among the most frequent problems of patients referred to emergency department (1). Hepatic portal venous gas (HPVG) is a rare condition that is associated with accumulation of gas in the portal venous circulation. This condition was historically linked to high morbidity and mortality in patients with acute abdomen (2, 3). Case series have shown that overall mortality rate of HPVG is between 29-39%, depending on the underlying etiology (4, 5). Most fatal cases with HPVG are secondary to development of mesenteric ischemia with extended bowel necrosis. However, there are some reports that have indicated the presence of HPVG in certain non-ischemic conditions with good prognosis (4). Despite the fact that finding air in the portal vein is not a diagnosis by itself, HPVG may give clinicians some hints for the diagnosis of underlying medical conditions. Without using advanced radiological techniques, detecting air in the portal vein is not an easy for clinicians, since abdominal plain x-ray does not detect portal air in 80% of cases (2, 6). Air in the portal vein is visible as echogenic bubbles in ultrasound imaging (7). Abdominal CT scan is another imaging modality, which is more sensitive and maybe used in referral centres. Abdominal CT scan and ultrasonography can also be used to investigate underlying conditions in such patients. Based on published manuscripts, chronic renal failure might have a role in pathogenesis of HPVG (8-10). HPVG in patients with chronic renal failure might be linked with non-occlusive mesenteric ischemia (9). Chronic kidney disease is a known cause of vascular calcification and mesenteric vascular complications (11). Therefore, there is controversy regarding whether chronic renal failure cases are more vulnerable to present mesenteric ischemia accompa-

nied with HPVG or not. This relationship needs further investigation in future studies.

**Acknowledgment:**

We acknowledge all staff of emergency department of Lohmane Hakim Hospital, Tehran, Iran.

**Conflict of interest:**

There was no conflict of interest.

**Author's contribution:**

All the authors have contributed to drafting/ revising the manuscript, study concept, or design, as well as data interpretation.

**References:**

1. Forouzanfar M, Hatamabadi H, Hashemi B, et al. Outcome of nonspecific abdominal pain in the discharged patients from the emergency department. *J Gorgan Uni Med Sci.* 2014;16(2):62-8. [Persian].
2. Kesarwani V, Ghelani DR, Reece G. Hepatic portal venous gas: A case report and review of literature. *Indian J Crit Care Med.* 2009;13(2):99-101.
3. Baratloo A, Rahmati F, Rouhipour A, et al. Correlation of Blood Gas Parameters with Central Venous Pressure in Patients with Septic Shock; a Pilot Study. *Bull Emerg Trauma.* 2014;2(2):77-81.
4. Kinoshita H, Shinozaki M, Tanimura H, et al. Clinical features and management of hepatic portal venous gas: four case reports and cumulative review of the literature. *Arch Surg.* 2001;136(12):1410-4.
5. Faberman RS, Mayo-Smith WW. Outcome of 17 patients with portal venous gas detected by CT. *Am J Roentgenol.* 1997;169(6):1535-8.
6. YIP C, Ng V, MAN D, Metreweli C. Sonographic Recognition of Pneumatosis Intestinalis and Portal Gas in an 11-months-old Infant—Case Report. *Australas Radiol.* 1990;34(2):169-71.
7. Lafortune M, Trinh B, Burns P, et al. Air in the portal vein: sonographic and Doppler manifestations. *Radiology.* 1991;180(3):667-70.
8. Morimoto Y, Yamakawa T, Tanaka Y, Hiranaka T, Kim M. Recurrent hepatic portal venous gas in a patient with hemodialysis-dependent chronic renal failure. *J Hepatobiliary Pancreat Surg.* 2001;8(3):274-8.
9. Iguchi S, Alchi B, Safar F, et al. Hepatic portal venous gas associated with nonocclusive mesenteric ischemia in a hemodialysis patient. *Clin Nephrol.* 2005;63(4):310-2.
10. Chang C-J, Shun H-C, Chuang C-C. Hepatic portal venous gas induced by emphysematous pyelonephritis: a rare case in hemodialytic women. *Am J Emerg Med.* 2009;27(9):1171.e1-. e3.
11. Soriano S, Carmona A, Triviño F, et al. Endothelial damage and vascular calcification in patients with chronic kidney disease. *Am J Physiol Renal Physiol.* 2014;307(11):F1302-F11.

