

## CASE REPORT

## A Young Man with Myocardial Infarction due to Trenbolone Acetate; a Case Report

Kavous Shahsavari nia<sup>1</sup>, Farzad Rahmani<sup>2\*</sup>, Hanieh Ebrahimi Bakhtavar<sup>3</sup>, Yashar Hashemi Aghdam<sup>4</sup>, Moloud Balafar<sup>1</sup>

1. Road Traffic Injury Research Center, Tabriz University of Medical Sciences, Tabriz, Iran
2. Department of Emergency medicine, Tabriz University of Medical Sciences, Tabriz, Iran
3. Department of Emergency Medicine, Ardabil University of Medical Sciences, Ardabil, Iran
4. Young Researchers Club, Islamic Azad University, Tabriz, Iran

### Abstract

Over the four decades, a significant decrease has been observed in age-related mortality caused by cardiovascular disease. People in developing countries suffer from CAD at a relatively younger age and about half of MI occurs under the age of fifty years. Abuse of anabolic steroids is one of the less common causes of atherosclerosis. In this report, a 23-year-old body builder male referred to emergency department (ED) with myocardial infarction (MI) following chronic Trenbolone acetate consumption. It seems that a comprehensive history of steroid consumption in young patients referred to ED with the chief complaint of chest pain or its equivalents is necessary in adjunct to other cardiac risk factors.

**Key words:** Chest pain; anabolic agents; myocardial infarction; young adult

**Cite this article as:** Shahsavari nia K, Rahmani F, Ebrahimi Bakhtavar F, Hashemi Aghdam Y, Balafar M. A young man with myocardial infarction due to trenbolone acetate; a case report. *Emergency*. 2014;2(1):43-5.

### Introduction:

Coronary Artery Disease (CAD) is a leading cause of death throughout the world (1). Over the four decades, a significant decrease has been observed in age-related mortality caused by cardiovascular disease (2). People in developing countries suffer from CAD at a relatively younger age and about half of MI occurs under the age of fifty years (3). Inadequate perfusion due to atherosclerosis is a common cause of coronary artery stenosis (2). Ischemic chest pain in young adults is usually related to hypertrophic cardiomyopathy, congenital coronary abnormalities, tachyarrhythmia, myocarditis, aortic stenosis, dissection, or coarctation (4). Age, male sex, hypertension, smoking, diabetes, dyslipidemia, and obesity are considered as established risk factors for cardiovascular diseases and atherosclerosis (5, 6). Abuse of anabolic steroids is one of the less common causes of atherosclerosis. These agents are used currently to increase protein synthesis and muscle growth in athletes (7). Since the use of anabolic steroids has been increased, different types of them produced (8). Mostly people start using the anabolic steroids in school time (9). According to the statistics, 0.9% of men and 0.1% of women use these agents during their lifetime (10). In this review, a 23-year-old male body builder was reported, with myocardial infarction (MI) following use of Trenbolone Acetate.

### Case report:

A 23-year-old man was referred to the emergency room with epigastric pain since the last day. He was an athlete and his previous medical history was negative. Due to the absence of risk factors for heart disease, symptomatic treatment was done for him and his pain decreased so that the patient was discharged from the emergency department. But, after 3 days the patient presented again to ED with the same complaint. The pain radiated to the left arm accompanied by nausea. After obtaining the accurate history of the patient, it was elucidated that he has been using the Trenbolone Acetate in his daily diet since last year. The patient's vital signs were included blood pressure 130/80 mmHg, heart rate 105 per minute, respiratory rate 25 per minute, O<sub>2</sub> sat 98% (on room air). In physical examination, the patient had sweated and the lungs were clear on auscultation. S1 and S2 sounds of heart were normal and S3 sound was heard, too. The abdomen was soft but not tender.

According to the examination and history of the patient, electrocardiogram (ECG) was obtained and showed that ST elevation on V1-V6 leads ([Figure 1](#)). His portable chest radiograph was normal. Cardiac markers (Creatine kinase MB and troponin I) were elevated. Due to the unavailability of a heart center for doing an emergency Percutaneous Coronary Intervention (PCI), the patient was treated with fibrinolysis (streptokinase). Then, the patient was transferred to the cardiac center. He was admitted to the cardiology ward and after a week, angiography was done for him. The patient's angiography showed the stenosis of the Left Anterior De-

\*Corresponding Author: Farzad Rahmani, MD. Emergency Medicine Department, Imam Reza Hospital, Tabriz University of Medical Sciences, Golgasht Avenue, Tabriz, Iran. Postal code: 5166614756. Fax Number: 00984113352078. Email: Farzadrhn88@gmail.com.

Received: 12 January 2013; Accepted: 13 January 2014



scending (LAD) and Left Circumflex (LCX) arteries (Figure 2).

#### Discussion:

Anabolic steroids can cause many problems such as cardiovascular which includes hypertension, left ventricular hypertrophy, impaired diastolic filling, polycythemia and thrombosis (7). The effects of steroids on lipid profile include decreasing in High Density Lipoprotein (HDL), increasing in Low Density Lipoprotein (LDL) and total cholesterol. These changes are led to increase the risk of atherosclerosis in the coronary arteries (11-13). Indirectly, increasing the concentrations of LDL due to the abuse of anabolic steroids may lead to an increase in sensitivity of platelets (14). Long-term effects of these agents can be observed in the cardiovascular system, mental health, and increasing the risk of neoplasm (15). The mortality rate is higher in abusers of these agents (7).

Trenbolone acetate is a synthetic anabolic steroid (16) often referred to as "Fina" by users, because the injectable Trenbolone acetate was originally adapted for use by bodybuilders from the dissolution of Finaplix H pellets; it is an ear implant used by cattle ranchers to maintain the weight of cattle during shipping to slaughter. Trenbolone is a steroid used by veterinarians on livestock to increase muscle growth and appetite (17, 18). Because these drugs have remarkable effects on bulking muscle mass and burning fats, illicit use of them have been increased among bodybuilders(18). Therefore, it seems to be necessary that a comprehensive history of steroid consumption in young patients present to the emergency department with the chief complaint of chest pain or its equivalents should adjunct to other cardiac risk factors.

#### Conclusion:

When young athletes with a history of anabolic drugs refer to the emergency department with complaints of chest pain, ischemic heart issues must be considered. Without the necessary symptoms to exclude ischemic heart problems, lower age is not an enough criterion for such an exclusion.

#### Acknowledgments:

The authors would like to express our sincere appreciation to Mrs. Farnoosh Rahmani for scientific editing of this manuscript.

#### Conflict of interest:

None

#### Funding support:

None

#### Authors' contributions:

All authors passed four criteria for authorship contribution based on recommendations of the International Committee of Medical Journal Editors.

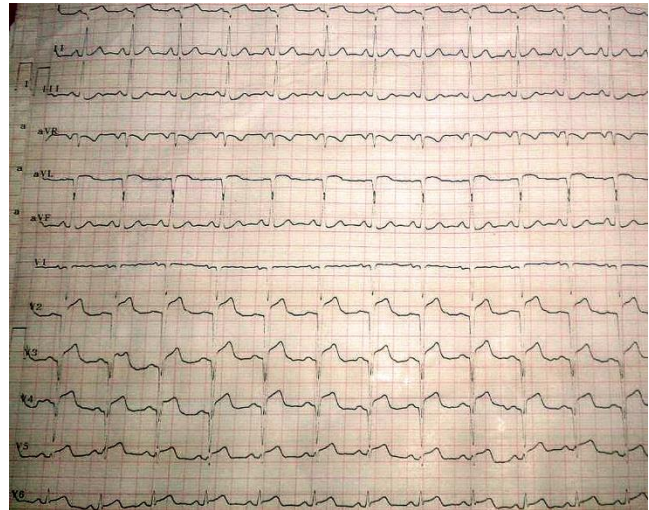


Figure 1: The 12-lead patient's Electrocardiogram. [↑](#)

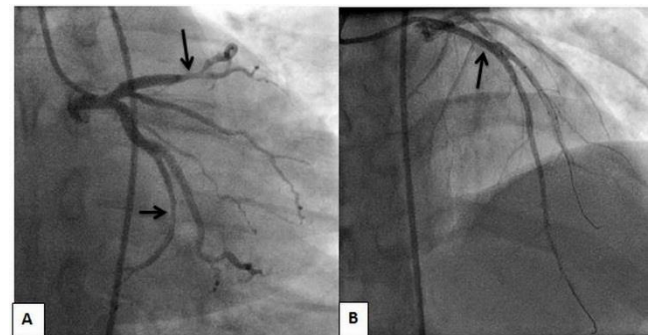


Figure 2: Patient's angiography views. A) Upper arrow: left anterior descending artery (LAD), Lower arrow: left circumflex artery (LCX); B) after percutaneous coronary intervention (PCI) and stent placement in LAD. [↑](#)

#### References:

- Murray CJ, Lopez AD. Mortality by cause for eight regions of the world: Global Burden of Disease Study. *The Lancet*. 1997; 349(9061):1269-76.
- Marx JA, Hockberger RS, Walls RM, Adams GA. Concepts and clinical practice. *Rosen's emergency medicine*. 8ed. Philadelphia, PA: Elsevier Saunders; 2014. p. 997-1033.
- Enas EA, Senthilkumar A. Coronary artery disease in Asian Indians: an update and review. *Coron Artery Dis*. 2005;3:21-57.
- Maron BJ. The young competitive athlete with cardiovascular abnormalities: causes of sudden death, detection by preparticipation screening, and standards for disqualification. *Card Electrophysiol rev*. 2002;6(1):100-3.
- Balogopal PB, de Ferranti SD, Cook S, et al. Nontraditional risk factors and biomarkers for cardiovascular disease: mechanistic, research, and clinical considerations for youth a scientific statement from the American Heart Association. *Circulation*. 2011;123(23):2749-69.
- Libby P, Theroux P. Pathophysiology of coronary artery disease. *Circulation*. 2005;111(25):3481-8.
- Kam P, Yarrow M. Anabolic steroid abuse: physiological and anaesthetic considerations. *Anaesthesia*. 2005;60(7):685-92.
- Korkia P. Use of anabolic steroids has been reported by 9%



- of men attending gymnasiums. *Brit Med J.* 1996;313(7063):1009-14.
9. Buckley WE, Yesalis III CE, Friedl KE, Anderson WA, Streit AL, Wright JE. Estimated prevalence of anabolic steroid use among male high school seniors. *JAMA.* 1988;260(23):3441-5.
10. Dawson R. Drugs in sport-the role of the physician. *J Endocrinol.* 2001;170(1):55-61.
11. Dickerman RD, McConathy WJ, Zachariah NY. Testosterone, sex hormone-binding globulin, lipoproteins, and vascular disease risk. *J Cardiovasc Risk.* 1997;4(5-6):363-6.
12. Glazer G. Atherogenic effects of anabolic steroids on serum lipid levels: a literature review. *Arch Intern Med.* 1991;151(10):1925-31.
13. Hartgens F, Rietjens G, Keizer H, Kuipers H, Wolffenbuttel B. Effects of androgenic-anabolic steroids on apolipoproteins and lipoprotein (a). *Brit J Sports Med.* 2004;38(3):253-9.
14. Rockhold R. Cardiovascular toxicity of anabolic steroids. *Annu Rev Pharmacol Toxicol.* 1993;33(1):497-520.
15. Pärssinen M, Seppälä T. Steroid use and long-term health risks in former athletes. *Sports Med.* 2002;32(2):83-94.
16. Zarkawi M, Galbraith H, Hutchinson J. The action of trenbolone acetate, a synthetic anabolic steroid, on ovarian function in the guineapig. *Lab Anim.* 1991;25(2):117-21.
17. Skarberg K, Nyberg F, Engstrom I. Multisubstance use as a feature of addiction to anabolic-androgenic steroids. *Eur Addict Res.* 2009;15(2):99-106.
18. Wilson VS, Lambright C, Ostby J, Gray LE, Jr. In vitro and in vivo effects of 17beta-trenbolone: a feedlot effluent contaminant. *Toxicol Sci.* 2002;70(2):202-11.

