

REVIEW ARTICLE

Clinical Characteristics, Course, and Outcomes of Vertebral Artery Dissections in the Postpartum Period; a Pooled Analysis of Published Case Reports

Rehab Adel Diab^{1,6*}, Nour Shaheen², Abdelrahman Mohamed², Mahmoud Tarek Hefnawy^{3,6}, Dilawer Chofan Charo^{4,6}, Mostafa Meshref^{5,6}

1. Faculty of Medicine, Al-Azhar University, Cairo, Egypt.
2. Faculty of Medicine, Alexandria University, Alexandria, Egypt.
3. Faculty of Medicine, Zagazig University, Medical Research Group of Egypt, Cairo, Egypt.
4. General Surgery Department, National Hospital in Latakia, Latakia, Syria.
5. Neurology Department, Faculty of Medicine, Al-Azhar University, Cairo, Egypt.
6. Medical research Group of Egypt (MRGE), Research Department, Cairo, Egypt.

Received: December 2022; Accepted: January 2023; Published online: 4 March 2023

Abstract: **Introduction:** Vertebral artery dissection (VAD) is a rare, but life-threatening condition. Compared to the general population, pregnant and postpartum women are more likely to develop VAD. Spontaneous arterial dissections have an ambiguous pathophysiology and may be difficult to manage. This study aimed to pool and analyze the data of published cases in this regard. **Methods:** We conducted a literature search on February 24, 2022, using MeSH terms of interest in PubMed, Google Scholar, Ovid, Web of Science, and Scopus databases to find studies on VAD following childbirth. **Results:** A total of 28 studies were included in this review based on a database search. In the studies, 44 postpartum VAD (PPVAD) patients with a mean age of 34.26 ± 3.5 years were included. It took an average of 24.37 ± 13.7 days from delivery to dissection. 64% of the patients had developed unilateral dissection and 36% had developed bilateral dissection; 70% reported full recovery, and 9% did not achieve full recovery. The most common symptoms were headaches (89%), neck pain (64%), and hypertension (52%). The most common methods of diagnosis were magnetic resonance imaging (MRI) (64%) and computed tomography (CT) angiography (CTA) scan (66%). Only 8 (18%) cases reported the use of electrocardiography (ECG). The recorded outcomes of the patients with unilateral and bilateral postpartum VAD showed no statistical difference. Most of the included studies recommend early suspension and management for a better prognosis and prevention of complications. **Conclusion:** PPVAD is a severe medical condition but most cases were fully recovered after an early and proper antithrombotic plan for each case scenario.

Keywords: Vertebral artery; vertebrobasilar insufficiency; postpartum period; vertebral artery dissection

Cite this article as: Adel Diab R, Shaheen N, Mohamed A, Tarek Hefnawy M, Chofan Charo D, Meshref M. Clinical Characteristics, Course, and Outcomes of Vertebral Artery Dissections in the Postpartum Period; a Pooled Analysis of Published Case Reports. Arch Acad Emerg Med. 2023; 11(1): e26. <https://doi.org/10.22037/aaem.v11i1.1814>.

1. Introduction

Vertebral artery dissection (VAD) can be extracranial or intracranial and unilateral or bilateral with different prognoses ranging from complete healing to serious neurological sequelae (1). Dissection of cervical, vertebral, or carotid arter-

ies is rare, but once occurring, it can be fatal. VADs commonly occur in young poststroke patients but rarely affect patients in the postpartum period (2, 3). The postpartum period is a distressing period associated with headaches and other symptoms that make the diagnosis of postpartum vertebral artery dissection (PPVAD) challenging due to common symptoms between both. The incidence of headache reporting in the postpartum period is ranging from 11% to 80% (4). So the vertebral artery dissection should be considered in differential diagnosis for patients suffering from headaches in the postpartum period for early diagnosis and better out-

*Corresponding Author: Rehab Adel Diab; Faculty of Medicine, Al-Azhar University, Cairo, Egypt. Postal code: 44718 Email: rehab_diab97research@outlook.com. Tel: +20 127 245 1274, ORCID: <https://orcid.org/0000-0002-6552-4900>.

come. The incidence of spontaneous vertebral artery dissection ranges from 1 to 1.5 per 100.00, annually (5). 2.4% of symptomatic spontaneous VAD cases presented in the postpartum period and women are 2.5 times more likely than men to get VAD (3, 6). VAD can lead to stroke with an estimated incidence of one per 100,000 individuals annually (7), and stroke can lead to VAD (7, 8).

The etiology of spontaneous postpartum vertebral artery dissection is still unknown, but there are potential risk factors that can be considered to predispose it in the postpartum period, like hormonal and hemodynamic changes occurring during pregnancy and Valsalva maneuver (9). Due to the lack of literature about the clinical picture and management of PPVAD, our study aimed to pool and analyze the most frequent symptoms, signs, complications, and the strategies that are widely used in management of these cases.

2. Methods

2.1. Search strategy

The literature review was conducted on Feb 24, 2022, using the terms (("Vertebral Artery"[Mesh]) OR ("Vertebral Artery Dissection"[Mesh] OR "Vertebrobasilar Insufficiency"[Mesh] OR "PICA syndrome" [Supplementary Concept]) AND ("Postpartum*" [Mesh])). Using PubMed, Google Scholar, Ovid, Web of Science, and Scopus databases, we searched for case series and case reports on VAD following childbirth. Researchers independently conducted the search to find the studies matching the keywords. All studies reporting cases of vertebral artery dissection after childbirth were included in the search (Figure 1). The analysis did not include review articles or consensus statements. Preferred Reporting Items for Systematic Reviews and Meta-Analyses (PRISMA) was used to present inclusions and exclusions (10).

2.2. Study Selection, Data Extraction, and Data Analysis

Articles were selected based on predetermined criteria after title and abstract screening by two independent reviewers. The inclusion criteria were clinical case reports or series that reported the clinical characteristics, treatment protocol, and outcomes of PPVAD. Based on the following exclusion criteria, several steps were taken to select included studies. 1) Studies that are not tailored for humans (such as in vitro or animal studies), 2) Research not collecting original primary data (review, protocol, editorial, letter, etc.), 3) No full text of the research results was provided (i.e., abstracts of conference posters), and 4) Studies in a language other than English.

2.3. Quality assessment

The overall quality of the case series and the case reports was assessed. The Joanna Briggs Institute (JBI) Critical Appraisal checklist was used in the quality assessment of Case Reports (11), while the NIH Quality Assessment Tool was used for Case Series (12) (Appendix 1 & 2).

2.4. Data Analysis

Python 3.0 was used for data management and cleaning as well as statistical analysis. A comparison was made between patients that suffered from unilateral dissection and patients that faced a bilateral dissection. Other variables were investigated as well, like whether having multiple previous pregnancies affected the final outcome or time to dissection. The Mann-Whitney test was used for numerical data, and Fisher's Exact test was used for categorical data.

3. Results

3.1. Characteristics of included studies

In total, 163 studies were found in PubMed, Google Scholar, Ovid, Web of Science, and Scopus using our search criteria. A total of 74 full-text articles were reviewed after excluding duplicate studies, studies lacking clinical data, review articles, and articles unrelated to our study objective. Based on the review, 32 studies met our inclusion criteria; therefore, 32 studies about vertebral artery dissection after birth were reviewed and analyzed (Figure 1). Characteristics of included studies are summarized in tables 1 and 2. Studies most commonly reported diagnosis via MRI with 28 (64%) and CT-angiography with 29 (66%) case. Only 8 (18%) cases reported the use of ECG as a diagnostic tool for VAD alongside one or more of the main modalities mentioned. Based on the reported data, most studies used anticoagulant and antiplatelet drugs to treat VAD, including warfarin, aspirin, and enoxaparin as well as antihypertensive drugs.

3.2. Pooled analysis of reported cases

Pooled analysis of cases is presented in table 3. The studies included a total of 44 patients who suffered from postpartum vertebral dissection with a mean age of 34.26 ± 3.50 years. The average time between delivery and dissection was 24.37 ± 13.7 days. 28 (64%) of the patients developed unilateral dissection, whereas the remaining 16 (36%) developed bilateral dissection. 20 (45%) of the patients reported delivering via vaginal delivery, 16 (36%) reported delivering via C-sections, whereas the remaining 8 (19%) did not report a specific delivery type.

The most frequent signs and symptoms were headache 39 (89%) and neck pain 28 (64%). 23 (52%) of the patients had high blood pressure after pregnancy, whereas only 4 (9%) pa-

Table 1: Summary of the included studies; number of patients, mean age (years), obstetric code, delivery type, and vessels affected

Study ID	No.	Mean Age (years)	Obstetric Code	Delivery type	Affected vessels (side)
Azad, 2021(19)	12	31.8	NA	9 Vaginal 3 Cesarean	2 Vertebral (R), 4 Vertebral (L),6 Vertebral (Both)
Borelli, 2012(31)	1	32	G2P2	Cesarean	Vertebral (L)
Brantley, 2012(14)	1	32	G3P3	Vaginal	Vertebral (L), LAD, IM(L)
Cenkowski, 2012(36)	1	35	G2P2	NA	Vertebral (R), obtuse marginal coronary artery
Drazin, 2012(24)	1	37	PG	Vaginal	Vertebral (Both)
Drăghici, 2021(6)	1	37	G3P3	Cesarean	Vertebral (R), Basilar
Feldman, 2019(19)	1	41	G5P4	Cesarean	Vertebral (R), RSCA
Finley, 2015(9)	1	35	G5P5	Cesarean	Vertebral (R)
Gasecki,1999(42)	4	32.5	G6P4	3 Vaginal 1 Cesarean	One vertebral, three internal carotids
Gomez-Rojas, 2020(44)	1	37	NA	NA	Vertebral (Both)
Jeannie, 2014(41)	5	33.4	NA	4 Vaginal 1 Cesarean	1 Vertebral (R), 3 vertebral (Both), 2 Internal carotid (L)
Kaplan, 1993(38)	1	41	G4P4	Vaginal	Vertebral (L)
Keane, 2019(26)	1	30	G2P2	Cesarean	vertebral (L), internal carotid (L), PICA
Kelft, 1992(27)	1	31	PG	Vaginal delivery	vertebral (R) Basilar artery
Levy, 2011(32)	1	32	G2P3	Vaginal	Vertebral, transverse, and sigmoid sinuses (L)
Manasewitsch, 2020(25)	1	31	NA	Cesarean	Vertebral (L)
McKinney, 2010(34)	1	41	NA	Cesarean	Vertebral (Both), Basilar, PCA
Mikeal levey 2011(32)	1	32	P3G3	Vaginal	Vertebral (R), transverse and sigmoid sinus (L)
Mitchell, LA. 2014(39)	1	NA	NA	NA	Vertebral (Both)
Monari,2021(45)	1	39	NA	Cesarean	Vertebral (R)
Nehme, 2020(23)	1	36	G2P2	Cesarean	Vertebral (both)
Nishimura, 2015(29)	1	35	G1P1	NA	Vertebral (R)
Pires, 2011(33)	1	31	G1P1	Cesarean	Vertebral (Both)
Previtra, 2012(37)	1	34	NA	NA	Vertebral (R)
Sano, K. 2021(40)	1	38	G2P2	Vaginal	Vertebral (L), MCA (Both), PCA (both)
Shanmugalingam, 2016(43)	4	31.25	G2P2	Cesarean	1 Vertebral (R), 3 vertebral intramural thrombus
Simon, 2015(30)	1	31	G4P4	Vaginal	Vertebral (L), Internal carotid (Both)
Spence, 2016(35)	1	33	G2P2	NA	Vertebral (Both), LAD, LCX, Celiac, SMA, IMA

Not applicable (NA), Right (R), Left (L), Gravida 2 /Para 2 (G2P2), PG: Primigravida, LAD: left anterior descending artery; IMA: Internal Mary artery; RSCA: right subclavian artery; PICA: Posterior inferior cerebellar artery; PCA: Posterior cerebral artery; MCA: Posterior cerebral artery; LCX: left circumflex artery ; SMA: Superior mesenteric artery.

tients reported hypertension during pregnancy as well. Additionally, 14 (32%) of the patients had associated syndromes including Opal ski Syndrome, HELP syndrome, Horner Syndrome, and postpartum angiopathy.

Based on the reported data, 2 (5%) patients had at least one failed pregnancy, 5 (11%) patients had trauma injury, 7 (16%) patients had surgical history (3 caesareans, 1 vacuum-assisted vaginal delivery, 1 thyroidectomy, and 2 diagnostic laparoscopies. As for the final outcome, 31 (70%) reported being fully recovered, 4 (9%) did not undergo full recovery and the remaining 9 (21%) did not provide data for follow-up final outcomes.

There was no statistical difference between unilateral and bilateral cases and also gravid 1 or >1 regarding age distribu-

tion, time from delivery to dissection, and final outcomes (Table 4).

4. Discussion

VAD is a rare and serious condition in the postpartum period. According to literature, cervical dissection represents 6% of spontaneous dissections in females under 50 years of age (8). Using our results, we found that the mean age of the patients was 34.26 ± 3.50 years. Cervical dissections in the postpartum period mainly include vertebral and carotid artery dissections; both are reported to occur unilaterally or bilaterally (9, 13). Our study showed that 64% of the included patients developed unilateral vertebral artery dissection while

Table 2: Summary of the included studies; time from delivery (days), clinical presentation, comorbidities, investigation, treatment, and final outcome

Study ID	Time from delivery (days)	Clinical presentation	Comorbidities	Investigation	Treatment	Outcome
Azad, 2021(19)	12	Headache was reported in all cases and some reported neck pain, weakness, and stroke, and a single case reported SAH	HTN of pregnancy in all cases, some reported HELLP syndrome, Loeyes-Dietz syndrome, Factor V Ledin syndrome, Reversible vasoconstriction syndrome and MTHFR mutation	MRI showed the affected arteries in each patient	Anticoagulants and endovascular surgery	Full recovery
Borelli, 2012(31)	10	Headache, hypertension, dizziness, and mild right-side weakness	HELLP syndrome and preeclampsia	MRI Showed bilateral left predominant thalamic infarction, and CT angiogram showed left Vertebral artery dissection at V3 and V4 segments	Antiplatelet (Aspirin)	NA
Brantley, 2012(14)	7	Hypertension and neck pain	ACS	ECG with cardiac Biomarkers: suggestive for NSTEMI MRI: not done CT-angiogram: dissection of the left vertebral artery at the level of C6 to C7 and dissection involving the LAD, not the main coronary ECHO 6 days later: no motion, valvular abnormalities with the normal system, IC function	Anticoagulant therapy (Heparin), Antiplatelets (Aspirin, clopidogrel) and CABG for coronary dissection	Full recovery
Cenkowski 2012(36)	210	Nausea, vomiting, chest pain with elevated cardiac enzymes, and one month later presented with numbness in her left arm and face.	NA	ECG: inferior STEMI CT angiogram: dissection of r.t vertebral v1 segment with aneurysmal dilatation and Obtuse marginal coronary artery. ECHO: EF= 50-55%.	Antiplatelet (warfarin) and Antiplatelet (aspirin, clopidogrel), statins, metoprolol, ramipril, nitroglycerin	NA
Drazin, 2012(24)	immediately	Headache, neck pain, Hypertension, photophobia and SAH	NA	MRI: beaded appearance along cervical segments of both vertebral arteries. CT-angiogram: narrowed vertebral arteries.	Anticoagulants therapy	Full recovery
Drăghici, 2021(6)	56	Headache, neck pain dizziness, palsies, stroke, dysphagia, and extracranial stroke	Autoimmune thyroiditis	MRI: Bilateral infarction of the pons. CT-angiogram: filling defect of the basilar artery with narrowing of the right vertebral artery suggesting dissection	Anticoagulant therapy (Heparin with enoxaparin) and Antiplatelets (Aspirin)	NA
Feldman, 2019(28)	3	Visual symptoms, sensory deficit, intracranial stroke	NA	MRI: restricted diffusion in r.t cerebellum, right pons, and midbrain CT-angiogram: Areas of narrowing and dilatation artery vertebral artery	Aspirin	Full recovery
Finley, 2015(9)	21	Headache, hypertension, dizziness, vertigo, nausea, vomiting, and visual symptoms	NA	MRI: diffusion defect within the cerebellar hemispheres bilateral more in the r.t CT-angiogram: R.t VAD with variations in the l.t vertebral artery at the junction with the proximal aorta.	Anticoagulant therapy (oral warfarin)	Full recovery

Table 2: Summary of the included studies; time from delivery (days), clinical presentation, comorbidities, investigation, treatment, and final outcome

Study ID	Time from delivery (days)	Clinical presentation	Comorbidities	Investigation	Treatment	Outcome
Gasecki, 1999(42)	14	Headache, vertigo, visual symptoms, cranial nerves palsies, Horner, right side ataxia, sensory deficit, and speech abnormalities	NA	MRI: some cases show no brain abnormalities, and the others show diffusion defect at areas supplied by the occluded artery CT-angiogram: suggestive of dissection of either vertebral or carotid artery	Anticoagulant therapy (Heparin)	3 Full recoveries and one death
Gomez-Rojas, 2020(44)	NA	Headache, dizziness, vertigo, hypertension, nausea, vomiting, sensory deficit, and neck pain	NA	MRI: showed a large area of ischemia at PICA territory and smaller areas at the left superior parasagittal cerebellum CT-angiogram: narrowing of the caliber diameter suggesting dissection of both vertebral arteries	Anticoagulants (warfarin and solitary case used heparin)	Full recovery
Jeannie, 2014(41)	23	Headache, hypertension, neck pain, visual symptoms, intracranial SAH	NA	MRI, MRA and CT-angiogram: suggesting dissection of vertebral and carotid arteries for each corresponding case	Anticoagulant therapy (oral or heparin) and dual antiplatelets	Full recovery
Kaplan, 1993(38)	17	Headache, hypertension, nausea, neck pain, visual symptoms, extracranial stroke	NA	MRI: infarction in the left medulla and cerebellar hemisphere. CT-angiogram: dissection of the left vertebral and left PICA	Antiplatelet (Aspirin), statins and amlodipine	Not Fully recovered
Keane, 2019(26)	3	Hypertension, headache, neck pain and subarachnoid hemorrhage	NA	MRI: NA CT-angiogram left vertebral artery dissection with pseudoaneurysm	Balloon occlusion of the vertebral artery with Anticoagulant (warfarin)	NA
Kelft, 1992(27)	1	Headache, confusion, Ataxia, Horner sign, confusion, ipsilateral ataxia, nystagmus, hpa glesia on right side of face and left side of the body.	NA	MRI: r.t thalamic, post limb of internal capsule and occipital lobe ischemia. CT-angiogram: normal Vertebral artery -angiogram: dissection of the basilar artery with right vertebral affection with proximal thrombosis	Antiplatelets (Ticlopidine)	Fully recovered
Levy, 2011(32)	NA	Headache, hypertension, dizziness, nausea, vomiting, sensory deficit, cranial nerve palsies and intracranial stroke	Opalski syndrome	MRI: infarction in the brainstem and cerebellum. CT-venogram: CVST in the transverse and sigmoid sinus ECHO: mild TR	Anticoagulant Therapy (heparin)	Full recovery
Manasewitsch, 2020(3)	10	Headache, vertigo, nausea, vomiting, gait abnormalities, ataxia, and stroke	chorioamnionitis, IDA	MRI: infarction at the left cerebellar hemisphere CT-angiogram: dissection of the left vertebral artery and left PICA	Anticoagulant therapy (enoxaparin)	NA

Table 2: Summary of the included studies; time from delivery (days), clinical presentation, comorbidities, investigation, treatment, and final outcome

Study ID	Time from delivery (days)	Clinical presentation	Comorbidities	Investigation	Treatment	Outcome
McKinney, 2010(34)	6	Hypertension and headache, visual symptoms, and stroke	NA	MRI: Multiple infarctions at areas supplied by post circulation. CT-angiogram: dissection of both vertebral and basilar arteries with proximal segments dilatation of the posterior circulation.	Anticoagulants (Heparin), Antiplatelet (Aspirin), nicardipine infusion and levetiracetam	Not Fully recovered
Mikeal levey, 2011(32)	14	Headache, neck pain, hypertension, vomiting, dizziness, vertigo, visual symptoms, sensory deficit, and intracranial and extracranial stroke	Opalski syndrome	MRI: infarction of Medulla, cerebellum, and pyramidal dissection CT-angiogram not done ECHO: mild TR	Anticoagulants (heparin)	Full recovery
Mitchell, 2014(39)	10	Headache, dizziness, visual symptoms, sensory deficit, and stroke	NA	MRI: intramedullary infarction. CT-angiogram: the abnormal appearance of the right vertebral artery	Antiplatelet (Aspirin and clopidogrel)	Not Fully recovered
Monari, 2021(5)	NA	Headache, nausea, vomiting, dizziness, vertigo, visual symptoms, gait abnormalities and stroke	NA	MRI: infarction of the posterolateral portion of the brain bulb. CT-angiogram: right vertebral artery dissection.	Anticoagulant therapy (heparin and enoxaparin) and Antiplatelet (aspirin and clopidogrel)	NA
Nehme, 2020(23)	10	Headache, neck pain, hypertension, visual symptoms, gait abnormalities, SAH	NA	MRI: hematomas at dissection sites CT-angiogram: dissection of both vertebral arteries	Endovascular surgery with CCB and Antiplatelets (aspirin)	NA
Nishimura, 2015(29)	5	Headache, neck pain, hypertension, and seizures	PRES	MRI: infarction in the subcortical white matter CT-angiogram: stenosis of the right vertebral artery	Magnesium sulfate and Nicardipine	Full recovery
Pires, 2011(33)	18	Headache, neck pain, migraine, anosognosia, dysarthria,	NA	MRI: Contraindicated. Digital subtraction angiogram: dissection of Both ICA and left vertebral artery (string beads)	Anticoagulant therapy	Not Fully recovered
Previtra, 2012(37)	14-21	Headache, neck pain, vertigo, nausea, vomiting, Right faciobrachial syndrome, intracranial stroke	History of cervical manipulation	Brain MRI was normal, SAT MRI did not show dissection in Vertebral (R)	Anticoagulants, rehabilitation	Full recovery
Sano, 2021(40)	18	Headache, neck pain and subarachnoid hemorrhage	NA	MRI: infarction in both basal ganglia and right occipital cortex CT-angiogram: NA	Lowering BP without any thrombolytic therapy	Full recovery
Shanmugalingam, 2016(43)	3	Headache, hypertension, dizziness, and neck pain	NA	MRI: no evidence of post circulation infarction. CT-angiogram: features suggesting dissection or intramural thrombus of vertebral arteries	Anticoagulant therapy or antiplatelets	Full recovery

Table 2: Summary of the included studies; time from delivery (days), clinical presentation, comorbidities, investigation, treatment, and final outcome

Study ID	Time from delivery (days)	Clinical presentation	Comorbidities	Investigation	Treatment	Outcome
Simon, 2015(30)	21	Headache with mildly decreased facial sensation	Endometriosis and anemia	MRI: Increased intensity of the vertebral and carotid arteries bilaterally with near occlusion of the R.t internal carotid CT-angiogram: dissection of the left vertebral and bilateral internal carotid	Anticoagulant therapy (heparin and transferred to another hospital)	NA
Spence, 2016(35)	21	Hypertension and headache and neck pain	Repaired sinus venous ASD, ACS	ECG: anterior and inferior STE with reciprocal STD in the lateral leads MRI: NA CT-angiogram: dissection of both vertebral arteries, LAD, LCX, Celiac, SMA, and MA ECHO: no abnormalities detected.	Revascularization and Antiplatelet (aspirin, clopidogrel), statins, BB, amlodipine, ramipril, nitroglycerin	Full recovery

SAH: subarachnoid hemorrhage; HTN: hypertension; HELLP: Hemolysis, Elevated Liver enzymes and Low Platelets; MTHFR: methylenetetrahydrofolate reductase; MRI: magnetic resonance imaging; CT: computed tomography; ECG: electrocardiography; NSTEMI: non-ST-segment elevation myocardial infarction; LAD: left anterior descending artery; ECHO: echocardiography.

36% developed bilateral vertebral artery dissection.

Some studies reported the extension of VAD to include the basilar artery and other studies presented multiple vessel dissections as reported in a previous study (14) in which there was a rare case of postpartum multi-arterial dissection, involving the vertebral artery, coronary artery, and the internal mammary artery (6, 15). The exact incidence rate of cervical dissection is unknown; however, it has an estimated incidence of 2.6–3.0 cases per 100,000 population per year, with VAD being 3–5 times less frequent than carotid artery dissection (16, 17). Females are 2.5 times more likely to get VAD than males (17). Moreover, it has been reported that 2.4% of cervical dissections occur in females in the postpartum period (18). In addition, VAD is a leading cause of ischemic stroke among young people (19).

Postpartum cervical dissection can be caused by a variety of underlying factors, but the mechanisms are unclear. There are several hypotheses in literature regarding the effects of pregnancy hormones, especially progesterone, on collagen synthesis in the tunica media of vessels, increasing its sensitivity to systemic stressors like hypertension (6, 7, 9, 19).

Approximately 31 (70%) of patients presented with neurological symptoms. The main clinical presentation of VAD is typically acute, severe neck pain in the occipito-cervical region, either with or without headache (20). Our results showed that VAD in females in the postpartum period was mainly presented with headache as the commonest presentation in 39 (89%) of the cases followed by neck pain in 28 (64%), hypertension in 23 (52%) and visual defects symptoms in 17 (39%)

of the cases. Physical examination in VAD may reveal nystagmus, truncal ataxia, loss of taste, impairment in pain and thermal sensation, and ophthalmoplegia; however, that clinical picture may be vague, and symptoms overlap with that of the postpartum period making the differential diagnosis even more difficult (20). Investigations used to diagnose VAD are CT, CTA, and MRI. CT scan can show the ischemia in the posterior fossa, subarachnoid hemorrhage, vertebral artery occlusion and mural thrombus. MRI can also prove the diagnosis but is not always available. CTA can easily show any regularity or thickening in the vascular wall, this makes the CTA the investigation of choice in the case of VAD (20). Our finding showed that two or more of these investigations are usually used to establish the diagnosis or complications and CT was the commonest investigation used with 66% and MRI with 64% of cases.

Regarding the management of VAD, antithrombotic therapy should be started as soon as possible. Both antiplatelets and anticoagulants are the main lines in treatment, in a previous randomized trial (CADISS Trial) there was no difference in the efficacy of anticoagulants and antiplatelets in preventing stroke in patients suffering from vertebral artery dissections including carotid and vertebral arteries (21). Additionally, this conclusion was supported by a case series study of twelve patients who suffered cervical dissections, in which there was no difference in prognosis or complications (19). Anticoagulation is to be started with low-molecular-weight or unfractionated heparin followed by oral anticoagulation, while antiplatelets are applied for mono or dual therapy (10).

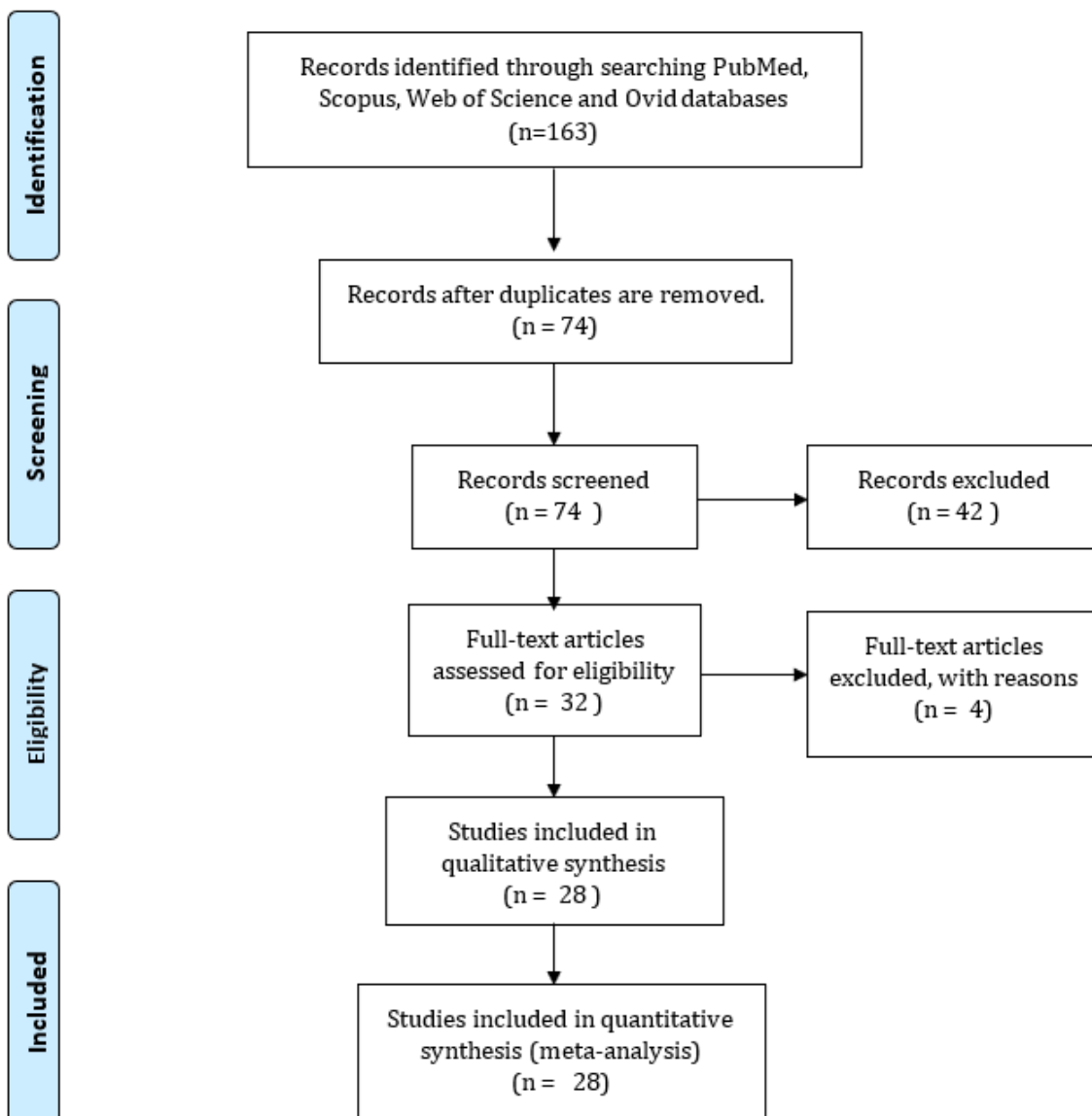


Figure 1: PRISMA flow diagram of study screening and inclusion.

Antiplatelets are widely preferred because of their availability and low cost. According to existing guidelines, antithrombotics should be continued for about three to six months, with no clear clinical evidence of the exact duration yet (1, 9). In the absence of exact duration and choice of antithrombotic strategy, it is recommended to be individually adapted according to each case scenario (22).

Clearly, this was evident from the management strategies in our included reports, in which antithrombotic choice was respected. 31 patients (70%) showed a full recovery after proper management while 4 cases (9%) showed incomplete recovery and the rest were not reported. Although postpartum VAD can carry a good prognosis it can cause permanent dam-

ages if complicated with stroke and infarction. VAD can develop complications such as cerebellar and brain stem infarctions, subarachnoid hemorrhage, pseudoaneurysm and cranial nerves affection (20). And all of these complications are reported in postpartum VAD in the included cases, either as a sign or a complication, along with stroke that developed in 10 patients (23%) and the subarachnoid hemorrhage that developed in 6 patients (14%); thus, early diagnosis and management of VAD are required, the sooner the better.

5. Limitations and recommendations

This study should be considered in light of several limitations. The first limitation is that there is a small number

Table 3: Pooled analysis of data of patients with post-partum vertebral artery dissection (n = 44)

Variables	Number (%)
Age (year)	
Mean \pm SD	34.26 \pm 3.50
Previous deliveries	
No	30 (68.1)
Signs and Symptoms	
Headache	39 (88.3)
Neck pain	28 (63.6)
Hypertension	23 (52.2)
Visual symptoms	17 (38.6)
Stroke	10 (22.7)
Dizziness	10 (22.7)
Nausea	10 (22.7)
Vomiting	9 (20.4)
Vertigo	8 (18.2)
Sensory deficits	7 (15.9)
Subarachnoid hemorrhage	6 (13.6)
Dysphagia	5 (11.3)
Ataxia	4 (9.0)
Cranial nerve	3 (6.8)
Gait problems	3 (6.8)
Palsies	3 (6.8)
Hearing changes	2 (4.5)
Weakness	1 (2.2)
Delivery Type	
Vaginal	20 (45.4)
Cesarean	16 (36.4)
Arteries dissected	
Unilateral dissection	28 (63.6)
Bilateral dissection	16 (36.4)
Pseudo-aneurysm	4 (9.0)
Recovery status	
Full recovery	31 (70.4)
Not fully recovered	4 (9.0)

Data are presented as frequency (%).
SD: standard deviation.

of cases, there is also lack of follow-up data. The specific dose of antithrombotic is different in each case scenario and cannot be generalized. Secondly, some clinical pictures are not completely reported when the cases are transported from one center to another or in case of long duration of hospital admission, in which not all the complications or side effects are fairly mentioned. The lack of literature about postpartum dissections is a remarkable limitation so further reports and high-quality evidence-based studies are strongly recommended.

6. Conclusions

PPVAD is a severe medical condition; most cases were fully recovered after an early and proper antithrombotic plan for each case scenario. Headache and neck pain were the com-

monest PPVAD presentations. Age, type of delivery, and Gravida were not statistically associated with PPVAD. Unilateral and bilateral postpartum VAD showed no statistical difference in the recorded outcomes of the patients. Most of the included studies recommend early suspicion and management for a better prognosis and prevention of complications.

7. Declarations

7.1. Acknowledgments

We would to express our sincere thanks to all authors of the included studies and to Medical research group of Egypt under supervision of Dr. Ahmed Negida for their support and encouragement in carrying out this project.

7.2. Conflict of interest

The authors have no conflict of interest to declare.

7.3. Fundings and supports

None.

7.4. Authors' contribution

Rehab Adel Diab: Conceptualization, Writing-Original draft, review, and editing. Nour Shaheen: Methodology, Writing-Original draft, review, and editing. Abdelrahman Mohamed: Formal Analysis Mahmoud Tarek Hefnawy: Writing-Original draft, review, and editing Dilawer chofan charo: Writing-Original draft, review, and editing Mostafa Meshref: Writing-Original draft, review, and editing. All Authors read and approved final version of the manuscript.

7.5. Ethics approval

Not applicable.

7.6. Data availability statement

The data was extracted from online published articles.

References

1. DeBette S, Leys D. Cervical-artery dissections: predisposing factors, diagnosis, and outcome. *The Lancet Neurology*. 2009;8(7):668-78.
2. Sances G, Granella F, Nappi R, Fignon A, Ghiotto N, Polatti F, et al. Course of migraine during pregnancy and postpartum: a prospective study. *Cephalalgia*. 2003;23(3):197-205.
3. Manasewitsch NT, Hanfy AA, Beutler BD, Antwi-Amoabeng D, Taha M, Elnaggar M, et al. Postpartum vertebral artery dissection: case report and review of the literature. *Thrombosis Journal*. 2020;18(1):1-5.

Table 4: Comparing the age, time from delivery to dissection, and follow-up of post-partum vertebral artery dissection based on laterality and number of gravidity

Variables	Unilateral (n=28)	Bilateral (n=16)	P	Gravida>1 (n=15)	Gravida=1 (n=22)	P
Age (year)	34.1 (0.75)	34.3 (0.9)	0.636	33.8 (0.72)	34.5 (0.73)	0.367
Time(day)	27.0 (11.73)	19.8(4.8)	0.101	42.2 (17.9)	12.8(3.4)	0.065
Recovery						
Full	17 (70%)	10 (71%)	0.291	9 (60%)	18 (82%)	1
Partial	1 (3.5%)	3 (18.8%)	0.291	1 (7%)	2 (9%)	1

Data are presented as mean (SD) or frequency (%).

- Redekop GJ. Extracranial carotid and vertebral artery dissection: a review. *Canadian journal of neurological sciences*. 2008;35(2):146-52.
- Monari F, Busani S, Imbrogno MG, Neri I, Girardis M, Ghirardini A, et al. Vertebral artery dissection in term pregnancy after cervical spine manipulation: a case report and review the literature. *Journal of Medical Case Reports*. 2021;15(1):1-8.
- Drăghici I-A, Marginean L, Filep R-C, Bajko Z, Barcutean L, Aldea T, et al. Postpartum Acute Basilar Artery Occlusion Secondary to Vertebral Artery Dissection. Case Report and Literature Review. *The Journal of Critical Care Medicine*. 2021;7(4):294-301.
- Morel A, Naggara O, Touzé E, Raymond J, Mas J-L, Meder J-F, et al. Mechanism of ischemic infarct in spontaneous cervical artery dissection. *Stroke*. 2012;43(5):1354-61.
- Sharshar T, Lamy C, Mas J. Incidence and causes of strokes associated with pregnancy and puerperium: a study in public hospitals of Ile de France. *Stroke*. 1995;26(6):930-6.
- Finley A, Rogers B, Richards T, Vogel H. Postpartum vertebral artery dissection. *Case Reports*. 2015;2015:bcr2015211872.
- Peng J, Liu Z, Luo C, Chen L, Hou X, Xiao L, et al. Treatment of cervical artery dissection: antithrombotics, thrombolysis, and endovascular therapy. *BioMed research international*. 2017;2017.
- Moola S, Munn Z, Tufanaru C, Aromatari sE SK, Sfetcu R. Chapter 7: systematic reviews of etiology and risk. *JBIManual for Evidence Synthesis*. 2020. 2020.
- NHLBI N. Study Quality Assessment Tools National Heart Lung and Blood Institute | NHLBI, NIH: U.S. Department of Health and Human Services; 2021 [Available from: <http://nhlbi.nih.gov/>].
- Shin JH, Suh DC, Choi CG, Lee HK. Vertebral artery dissection: spectrum of imaging findings with emphasis on angiography and correlation with clinical presentation. *Radiographics*. 2000;20(6):1687-96.
- Brantley HP, Cabarrus BR, Movahed A. Spontaneous multiarterial dissection immediately after childbirth. *Texas Heart Institute Journal*. 2012;39(5):683.
- Itumur K, Karahan Z, Ozmen S, Danis R, Toprak N. Spontaneous coronary artery dissection during hemodialysis in the post-abortion period. *International journal of cardiology*. 2008;127(2):e45-e7.
- Kim Y-K, Schulman S. Cervical artery dissection: pathology, epidemiology and management. *Thrombosis research*. 2009;123(6):810-21.
- Chang AJ, Mylonakis E, Karanasias P, Douglas F, Gold R, editors. Spontaneous bilateral vertebral artery dissections: case report and literature review. *Mayo Clinic Proceedings*; 1999: Elsevier.
- Arnold M, Camus-Jacqmin M, Stapf C, Ducros A, Viswanathan A, Berthet K, et al. Postpartum cervicocephalic artery dissection. *Stroke*. 2008;39(8):2377-9.
- Azad HA, Prasad N, Shlobin NA, Mitra A, Cloney MB, Hopkins BS, et al. Clinical characteristics, course, and outcomes of vertebral artery dissections in the postpartum period. *Neurosurgery*. 2021;89(5):792-9.
- Rathbun S. The surgeon general's call to action to prevent deep vein thrombosis and pulmonary embolism. *Circulation*. 2009;119(15):e480-e2.
- Investigators CT. Antiplatelet treatment compared with anticoagulation treatment for cervical artery dissection (CADISS): a randomised trial. *The Lancet Neurology*. 2015;14(4):361-7.
- Kennedy F, Lanfranconi S, Hicks C, Reid J, Gompertz P, Price C, et al. Antiplatelets vs anticoagulation for dissection: CADISS nonrandomized arm and meta-analysis. *Neurology*. 2012;79(7):686-9.
- Nehme A, Létourneau-Guillon L, Odier C, Poppe AY. Clinical Reasoning: A 36-Year-Old Woman Presenting With Headache Postpartum. *Neurology*. 2021;96(11):e1585-e9.
- Drazin D, Rosner J, Shirzadi A, Phuphanich S. Postpartum extracranial bilateral vertebral artery dissection mimicking subarachnoid hemorrhage. *The neurologist*. 2012;18(3):149-51.
- Manasewitsch NT, Hanfy AA, Beutler BD, Antwi-Amoabeng D, Taha M, Elnaggar M, et al. Postpartum vertebral artery dissection: case report and review of the literature. *Thrombosis Journal*. 2020;18(1).
- Keane JL, Liew LP. Postpartum Cervical Manipulation,

- Vertebral Artery Dissection and Reversible Cerebral Vasoconstriction: A Case Report. *Journal of Clinical Gynecology and Obstetrics*. 2019;8(3):97-102.
27. Van De Kelft E, Kunnen J, Truyen L, Heytens L. Postpartum dissecting aneurysm of the basilar artery. *Stroke*. 1992;23(1):114-6.
 28. Feldman JB, Kumaraswami S. Cesarean Hysterectomy in a Parturient With Morbidly Adherent Placenta Complicated by Postoperative Ischemic Stroke Secondary to Vertebral Artery Dissection: A Case Report. *A&A Practice*. 2019;12(1):9-14.
 29. Nishimura M, Hiraoka E, Kanazawa K, Akita H. Postpartum vertebral artery dissection with posterior reversible encephalopathy syndrome. *BMJ Case Reports*. 2015:bcr2014207332.
 30. Simon EL, Griffin G, Bosman E. Bilateral carotid and vertebral artery dissection: a life-threatening cause of postpartum headache. *Am J Emerg Med*. 2015;33(4):600.e1-3.
 31. Borelli P, Baldacci F, Vergallo A, Del Dotto P, Lucetti C, Nuti A, et al. Bilateral thalamic infarct caused by spontaneous vertebral artery dissection in pre-eclampsia with HELLP syndrome: a previously unreported association. *Journal of Stroke and Cerebrovascular Diseases*. 2012;21(8):914. e9-. e10.
 32. Levy M, Levy E, Maimon S. Atypical Postpartum Stroke Presenting as Opalski Syndrome: Case Report and Review of the Literature. *Case Reports in Neurology*. 2011;3(2):191-8.
 33. Pires C, Gerales R, Neto L, Melo TP. Spontaneous Multiple Cervical Artery Dissection in the Puerperium. *Cerebrovascular Diseases*. 2011;32(5):511-2.
 34. McKinney JS, Messé SR, Pukenas BA, Satti SR, Weigele JB, Hurst RW, et al. Intracranial Vertebrobasilar Artery Dissection Associated with Postpartum Angiopathy. *Stroke Research and Treatment*. 2010;2010:1-5.
 35. Spence S, Sud M, Bajaj R, Zavodni A, Sandhu S, Madan M. Postpartum spontaneous coronary, vertebral, and mesenteric artery dissections: a case report. *Journal of Medical Case Reports*. 2016;10(1).
 36. Cenkowski M, daSilva M, Bordun K-A, Hussain F, Kirkpatrick ID, Jassal DS. Spontaneous dissection of the coronary and vertebral arteries post-partum: case report and review of the literature. *BMC Pregnancy and Childbirth*. 2012;12(1):1-4.
 37. Antonino M, Previtera RP. Vertebral artery dissection after cervical manipulation in postpartum period: a case report. *Congress of the Italian Neurological Society: air.unimi.it*; 2012.
 38. Kaplan SS, Ogilvy CS, Gonzalez R, Gress D, Pile-Spellman J. Extracranial vertebral artery pseudoaneurysm presenting as subarachnoid hemorrhage. *Stroke*. 1993;24(9):1397-9.
 39. Mitchell LA, Santarelli JG SI, et al. Reversible cerebral vasoconstriction syndrome and bilateral vertebral artery dissection presenting in a patient after cesarean section. *J NeuroIntervent Surg*. 2014;6(5).
 40. Sano K, Kuge A, Kondo R, Yamaki T, Homma H, Saito S, et al. Postpartum reversible cerebral vasoconstriction with cortical subarachnoid hemorrhage and posterior reversible encephalopathy syndrome concomitant with vertebral artery dissection diagnosed by <scp>MRI MSDE</scp> method: A case rep. *Clinical Case Reports*. 2022;10(9).
 41. Kelly JC, Safain MG, Roguski M, Edlow AG, Malek AM. Postpartum Internal Carotid and Vertebral Arterial Dissections. *Obstetrics & Gynecology*. 2014;123(4):848-56.
 42. Gasecki AP, Kwiecinski H, Lyrer PA, Lynch TG, Baxter T. Dissections after childbirth. *Journal of Neurology*. 1999;246(8):712-5.
 43. Shanmugalingam R, Reza Pour N, Chuah SC, Vo TM, Beran R, Hennessy A, et al. Vertebral artery dissection in hypertensive disorders of pregnancy: a case series and literature review. *BMC Pregnancy and Childbirth*. 2016;16(1).
 44. Gomez-Rojas O, Hafeez A, Gandhi N, Berghea R, Halalau A. Bilateral Vertebral Artery Dissection: A Case Report with Literature Review. *Case Reports in Medicine*. 2020;2020:1-16.
 45. Monari F, Busani S, Imbrogno MG, Neri I, Girardis M, Ghirardini A, et al. Vertebral artery dissection in term pregnancy after cervical spine manipulation: a case report and review the literature. *Journal of Medical Case Reports*. 2021;15(1).

Appendix 1: The Joanna Briggs Institute (JBI) Critical Appraisal checklist for Case Reports (11)

Study ID	Were patient's demographic characteristics clearly described?	Was the patient's history clearly described and presented as a timeline?	Was the current clinical condition of the patient on presentation clearly described?	Were diagnostic tests or assessment methods and the results clearly described?	Was the intervention(s) or treatment procedure(s) clearly described?	Was the post-intervention clinical condition clearly described?	Were adverse events (harms) or unanticipated events identified and described?	Does the case report provide takeaway lessons?	Total yes, (Maximum = 8)
Nehme, 2020(23)	Yes	Yes	Yes	Yes	Yes	Yes	Yes	Yes	8
Drazin, 2012(24)	Yes	Yes	Yes	Yes	Yes	Unclear	No	Yes	6
Manasewitsch, 2020(25)	Yes	Yes	Yes	Yes	Yes	Unclear	Unclear	Yes	6
Monari, 2021(5)	Yes	Yes	Yes	Yes	Yes	Yes	Yes	Yes	8
Drăghici, 2021(6)	Yes	Yes	Yes	Yes	Yes	Yes	No	Yes	7
Keane, 2019(26)	Yes	Yes	Yes	Yes	Unclear	Yes	Yes	Yes	7
Van de Kelft, 1992(27)	Yes	Yes	Yes	Yes	Unclear	Yes	Yes	No	6
Feldman, 2019(28)	Yes	Yes	Yes	No	Yes	Yes	Yes	Yes	7
Finley, 2015(9)	Yes	Yes	Yes	Yes	No	Yes	Yes	Yes	7
Nishimura, 2015(29)	Yes	Yes	Yes	Yes	Yes	Yes	Yes	Yes	8
Simon, 2014(30)	Yes	Yes	Yes	Yes	No	Yes	No	No	5
Borelli, 2012(31)	Yes	No	Yes	Yes	Unclear	Yes	No	Yes	5
Levey, 2011(32)	Yes	Yes	Yes	Yes	Yes	Yes	Yes	Yes	8
Hutton P, 2010(14)	Unclear	Yes	Yes	Yes	Unclear	Yes	No	Yes	5
Pires, 2011(33)	Unclear	No	Yes	Yes	Unclear	Unclear	Yes	Yes	4
McKinney, 2010(34)	Yes	Unclear	Yes	Yes	Yes	Yes	Yes	Yes	7
Levy, 2011(32)	Yes	Yes	Yes	Yes	Yes	Yes	Yes	Yes	8
Spence, 2016(35)	Yes	Yes	Yes	Yes	Yes	Yes	Yes	Yes	8
Keane, 2019(26)	Yes	Yes	Yes	Yes	Yes	Yes	Yes	Yes	8
Cenkowski, 2012(36)	Yes	No	Yes	Yes	Yes	Yes	Yes	Yes	7
Previtra, 2012(37)	Yes	Unclear	Yes	Yes	Yes	Yes	Yes	Yes	7
Kaplan, 2016(38)	Yes	Yes	Yes	Yes	Yes	Unclear	Yes	Yes	7
Mitchell, 2014(39)	No	Yes	Yes	Yes	Yes	Yes	Yes	Yes	7
Sano, 2021(40)	Yes	Yes	Yes	Yes	No	Yes	Yes	Yes	7

Appendix 2: The NIH Quality Assessment Tool for Case Series, Good: Met 7-9 criteria, Fair: Met 4-6 criteria, Poor: Met 0-3 criteria (12)

Study ID	Was the study question or objective clearly stated?	Was the study population clearly and fully described, including a case definition?	Were the cases consecutive?	Were the subjects comparable?	Was the intervention clearly described?	Were the outcome measures clearly defined, valid, reliable, and implemented consistently across all study participants?	Was the length of follow-up adequate?	Were the statistical methods well-described?	Were the results well-described?	Total Quality Score	Quality
Jeannie, 2014(41)	Yes	Yes	Yes	NA	Yes	Yes	Yes	NR	Yes	7	Good
Gasecki, 1999(42)	Yes	Yes	NR	NA	No	Yes	Yes	NR	Yes	5	Fair
Shanmugalingam, 2016(43)	Yes	Yes	No	NA	Yes	Yes	Yes	NR	Yes	6	Fair
Azad, 2021(19)	Yes	Yes	Yes	Yes	Yes	No	Yes	Yes	Yes	8	Good

NA: not applicable, NIH: National Institutes of Health, NR: not reported.